

CRACKING THE CRACKED TOOTH CODE: DETECTION AND TREATMENT OF VARIOUS LONGITUDINAL TOOTH FRACTURES

The purpose of this review is to investigate diagnostic and treatment challenges related to tooth fractures primarily in the long axis of the crown and/or root. This includes when and how to identify and determine the extent of longitudinal fractures, a coronal restoration should be placed, root canal treatment is needed, and when a tooth or root should be extracted based on the location and extent of the longitudinal fracture.

The term longitudinal fracture is used because it typically represents vertical extensions of fractures over distance and time. These linear fractures tend to grow and change as opposed to those resulting from impact trauma, thus there are often problems with diagnosis and treatment. Cracks in teeth are findings that are to be detected in terms of location and extent. Crack detection is one aspect of a thorough diagnostic evaluation, but the presence of a crack alone does not provide information on the status of the pulp or periapical tissues; other diagnostic tests must be performed to determine a diagnosis. Practitioners must be aware that the major problem with having a crack in a tooth is the potential for bacterial penetration, which could lead to inflammation and disease. Therefore, cracks present in teeth are findings only; they are not to be considered a pulpal or periapical diagnosis.

Of significant note, this review is not intended to discuss fractures resulting from impact trauma, which are more common in anterior teeth and may occur in the vertical, as well as horizontal or oblique direction. Impact trauma results in an immediate fracture in the tooth as opposed to a longitudinal fracture that propagates over a period of time and may require considerably different treatment.

The content of this newsletter is intended to help resolve some of the confusion surrounding tooth cracks and fractures from a specialist's perspective. The goals are to help individual practitioners with diagnosis and treatment planning and to foster clearer communication amongst the dental team.

CRACKS ARE CONFUSING

Since there are many different types of cracks (and fractures) in teeth, and their signs and symptoms vary significantly, cracks have been confusing entities to detect and treat. Cracked teeth show a variety of symptoms, including erratic pain when chewing, possibly with release of biting pressure or pain when the tooth is exposed to temperature extremes. In many cases, the pain may come and go, and dentists may have difficulty locating which tooth is the cause of discomfort.

Cracks in teeth, particularly those in close approximation to the pulp and/or periodontium, can cause problems; most significantly, the potential for bacteria and its byproducts to cause inflammation, and pulp and periodontal degeneration. Our inability to know the extent of a crack line is one aspect that leads to misconception and complexity of determining an endodontic diagnosis. Another confusing aspect is that there has been no direct relationship established in the literature between patient's symptoms and the presence of a crack. Again, cracks that are present in teeth are findings; they are not to be considered a pulpal or periapical diagnosis.

INCIDENCE OF CRACKS

Unfortunately, the incidence of cracks in teeth is increasing. People are living longer and keeping their teeth longer. As a result, patients are more likely to have complex restorative and endodontic procedures that remove tooth structure, leaving teeth more susceptible to cracks. People of all ages are also living more stressful lives, which can result in crack-inducing habits, such as clenching and bruxism. Additionally, in recent years, practitioners have been more aware of the existence of cracks and, therefore, detect more of them. A recent 2007 study has found that patients who were referred from a general dentist to an endodontist with cracks involving marginal ridges were only identified in 9.7 percent of the cases evaluated over a six-year period. This percentage is expected to be higher in the general population since this study only includes patients that were referred.

The good news is that many teeth with cracks can be saved! The keys to saving these teeth are to know:

1. How to identify and classify cracks;
2. The characteristic signs and symptoms; and
3. How to detect the crack as early in its development as possible.

DEFINING CRACK TYPES

Because the location, direction and extent of a crack have a profound effect on the choice of treatment, clarity is important. For consistency in this article, the five types of longitudinal tooth fractures are described as follows:

- Craze Lines
- Fractured Cusp
- Cracked Tooth
- Split Tooth
- Vertical Root Fracture

Lack of knowledge concerning the type, characterization and variety of fractures may lead to misunderstanding with incorrect diagnosis and inappropriate treatment. These five categories of longitudinal fractures have been devised to provide global definitions that researchers and clinicians can use to decrease this confusion. Only after these fractures have been defined and characterized can there be a better understanding of their epidemiology; this review will show how each longitudinal fracture classification is different, especially related to prognosis and treatment modalities.

One factor that contributes to the confusion surrounding the issue of cracked teeth is that various authors have suggested a number of inconsistent terms to describe tooth cracks. For instance, "complete" and "incomplete" have been used to refer to a variety of crack features, including degree of pulpal involvement, degree of root involvement or extent of the crack. Classification schemes that only consider whether a fracture is complete versus incomplete will not readily illuminate these differences.

Craze lines affect only the enamel. Fractured cusps, cracked teeth and split teeth begin on the occlusal surface and extend apically, affecting enamel, dentin, and possibly, the pulp. Vertical root fractures begin in the root. All types except craze lines are found most often in posterior teeth. Unlike a broken bone, the fracture in a cracked tooth will never heal.

Each of the cracks and fractures discussed in this review could be called "vertical fractures." Also, each fracture that involves the tooth root, whether originating from the coronal (enamel) or apical (root)

portion of the tooth, can be termed “vertical root fractures.” Therefore, a crack that extends from crown to root in a mesiodistal direction, a split tooth and a “true” vertical root fracture that involves only the root, have been termed “vertical root fractures.” The use of these terms in this manner is not appropriate and has caused significant confusion clinically and in the dental literature; their use should be minimized. Fractured cusps and vertical root fractures imply a complete or incomplete break of the tooth; craze lines and cracked teeth are only incomplete breaks in teeth; and split teeth are only complete breaks in teeth. Note too that the terms “crack,” “fracture” and “fractured line” tend to be used interchangeably in the literature. ([Bonus Material A](#) is a table that separates the five types of longitudinal tooth fractures as to their incidence, pathogenesis, clinical features, etiologies, diagnosis, treatment, prognosis and prevention. [Bonus Material B](#) is a figure that further illustrates how to clinically differentiate and categorize cracks and fractures of teeth as to location, separable segments (i.e., complete versus incomplete) and treatment.)

CLASSIC SIGNS, CLASSIC CONFUSION

Teeth with cracks tend to have erratic pain on mastication, especially with release of biting pressure, and the patient tends to have trouble explaining the complaint. Sometimes there is pain to temperature extremes, especially cold. Generally, there is no pain to percussion and radiographs are inconclusive. Often patients will complain of a long history of pain, which has been difficult to diagnose and treatment that has failed to relieve their symptoms.

These have been labeled “classic signs” of cracks, however, depending on the location, direction and extent of the crack, the patient may present any one or all of these signs and symptoms, or a variety of others. This variable combination of signs and symptoms makes diagnosis difficult.

Cracked teeth often manifest as the so-called “cracked tooth syndrome.” This syndrome is characterized by acute pain on mastication (pressure or release) of grainy, tough foods and sharp, brief pain with cold. These findings are also related to cusp fracture. However, cracked teeth may present with a variety of symptoms ranging from slight to very severe spontaneous pain consistent with irreversible pulpitis, pulp necrosis or apical periodontitis. Even an acute apical abscess, with or without swelling or a draining sinus tract, may be present if the pulp has undergone necrosis. In other words, once the fracture has extended to and exposed the pulp, severe pulp and/or periapical pathosis will likely be present. This explains the variation in signs and symptoms, and therefore, should not be termed a syndrome.

If the pulp is involved, there may be signs and symptoms of irreversible pulpitis or necrosis with periapical pathosis. If the crack extends to a root surface, there may be a periodontal defect. In fact, cracks are often a contributing factor in pulpal pathosis and should always be carefully considered during endodontic diagnosis, especially in a case without obvious etiology.

Many times, cracks are not identified until a variety of symptoms are present, a restoration is removed or a significant periodontal defect is identified. Because diagnosis can be so complicated, a patient with a tooth crack will often end up in the endodontist’s office after a long history of uncertain diagnoses. However, just like cracks in a windshield, cracks in teeth often start small and progress slowly. If caught early and treated appropriately, many cracks can be stopped or at least slowed down, preventing loss of the tooth.

Quick action on the part of the dentist can improve the chances of saving the tooth. If a crack is suspected, steps should be taken immediately to confirm the presence of a crack, determine the type and formulate an appropriate treatment plan.

THE OBVIOUS AND THE OBSCURE: STEPS FOR CRACK DETECTION AND CONFIRMATION

If you do not look for cracks and fractures in teeth, you will likely not find them. If a crack is suspected, several steps should be taken to confirm the suspicion. The tests performed and results achieved will vary between teeth that have or have not had endodontic treatment. If the suspect tooth has been endodontically treated, symptoms will be limited to those caused by the affected periodontium because the tooth has no remaining vital pulp tissue. For the tooth that has a vital pulp, the following steps can be used to confirm the presence or absence of a crack. Further pulpal and periodontal testing will be necessary to develop a diagnosis and determine the need for endodontic treatment. Remember, cracks in teeth are findings; they are not diagnoses.

The steps for crack detection and confirmation include (see [Bonus Material C](#) for more details):

- Dental History
- Subjective Examination
- Objective Visual Examination
- Tactile Examination
- Periapical Tests
- Bite Tests
- Vitality Testing
- Periodontal Probing
- Radiographic Examination
- Restoration Removal
- Staining
- Transillumination
- Wedging Forces
- Surgical Assessment

CLASSIFICATION OF LONGITUDINAL TOOTH FRACTURES

Craze Lines

When examining teeth for cracks, keep in mind that most adult teeth have craze lines. In posterior teeth, craze lines are usually evident crossing marginal ridges and extending along buccal and lingual surfaces (Figure 1). Long vertical craze lines commonly appear on anterior teeth. As they only affect the enamel, they cause no pain and are of no concern beyond the aesthetic.

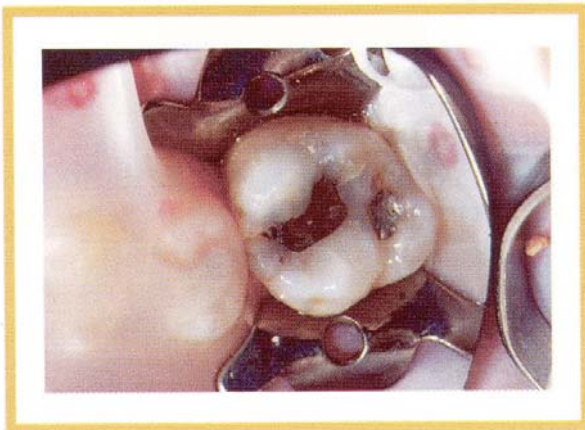

Fig. 1. Craze lines, such as those on the occlusal surface of this tooth, are sometimes mistaken for other types of cracks.

Diagnostic Clues

Craze lines are frequently confused with cracks, but can be differentiated by transillumination. If the tooth is cracked, the light will be blocked, allowing only a segment of the tooth structure to light up (Figure 2); if the tooth only has a craze line, the entire tooth structure will light up (see [Bonus Material D](#) for more information on transillumination).

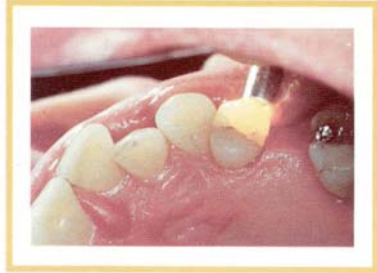

Fig. 2. A crack will block and reflect the light when transilluminated.

Fractured Cusp

The term fractured cusp is defined as a complete or incomplete fracture initiated from the crown of the tooth and extending subgingivally, usually directed both mesiodistally and buccolingually. The fracture usually involves at least two aspects of the cusp by crossing the marginal ridge and also extending down a buccal or lingual groove. The fracture will extend to the cervical third of the crown or root ([Bonus Material A](#), Figure 3).

Cuspal Fracture

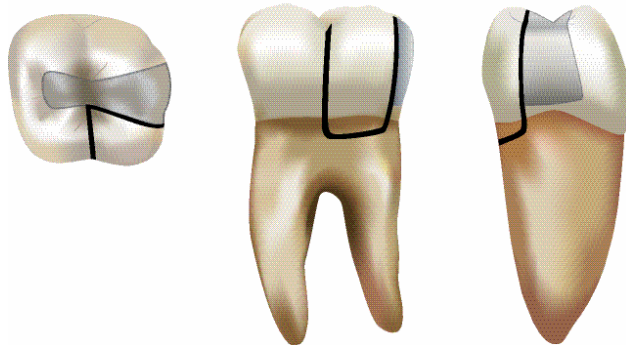


Fig. 3. Occlusal, lingual and distal/proximal views of a fractured cusp involving the distolingual cusp of the mandibular right molar. A restoration is typically present; usually one cusp is involved and the fracture is not centered as viewed from the proximal.

Of all cracks affecting dentin, cusp fractures are the easiest to identify and treat. Their treatment also has the best prognosis, especially when the crack does not extend below the gingival attachment.

The fractured cusp usually results from a lack of cusp support due to a weakened marginal ridge. Occlusally, it is common for the crack to have both a mesiodistal and a buccolingual component. The crack will cross the marginal ridge and continue down a buccal or lingual groove to the cervical region. It may terminate parallel to the gingival margin or slightly subgingivally (Figure 3). Generally, only one cusp is affected. It may be necessary to remove a restoration, stain the tooth and/or transilluminate to locate the cracks. Magnification may be helpful in determining the extent.

Diagnostic Clues

Class II restorations or extensive caries can contribute to weakened marginal ridges. Pain is mild and occurs only to stimulus. Generally, bite tests will elicit brief, sharp pain, especially with release of biting pressure. Tapping on selective tooth margins and cusps may help identify the area of the crack. The pulp is usually vital; radiographs are inconclusive. The affected cusp may break off during restoration removal, possibly resulting in relief of symptoms.

Treatment Planning

Depending upon the amount of remaining tooth structure, the tooth is treated by removing the affected cusp and restoring with a direct or a cuspal-reinforced restoration (full crown or onlay) that covers the crack margin. Dentin and enamel bonding with adhesive resins, if placed with special techniques, have been shown to reinforce a weakened tooth structure and provide cuspal protection. Root canal treatment or vital pulp therapy is only necessary in the event that the crack affects the pulp chamber or has resulted in irreversible pulpitis.

Cracked Tooth

A cracked tooth is defined as an incomplete fracture initiated from the crown and extending subgingivally, usually directed mesiodistally. The fracture may extend through either or both of the marginal ridges and through the proximal surfaces. The fracture is located in the crown portion of the tooth only or may extend from the crown to the proximal root ([Bonus Material A](#), Figure 4). Cracked teeth are described as incomplete (greenstick) fractures, which also describes their form. Occlusally, the crack is more centered and apical than a fractured cusp and, therefore, more likely to cause pulpal and periapical pathosis as it extends apically (Figure 4). Cracked teeth occur most commonly in mandibular molars, followed by maxillary premolars. The crack may rarely be buccolingual in mandibular molars. They do not occur in anterior teeth and rarely in mandibular premolars.

Cracked Tooth Progression To Split Tooth

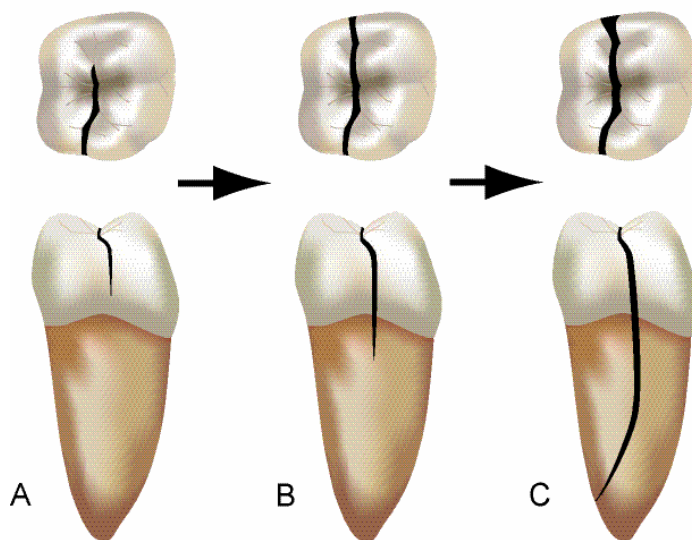


Fig. 4. (A) Occlusal and distal/proximal views of a cracked tooth affecting the distal marginal ridge of the mandibular right molar; the crack has not yet extended onto the root. (B) Growth/propagation of the crack to include both mesial and distal marginal ridges and extending onto the distal root surface; a restoration is usually not present and the crack is more centered as viewed from the proximal. (C) Further propagation results in a split tooth in which a separable segment is detected; mesial and distal marginal ridges are involved and the fracture extends deeply in the root.

Diagnostic Clues

The signs and symptoms of a cracked tooth will vary significantly depending on the progress of the crack. In its early stages, the crack will probably be invisible to the naked eye and impossible to disclose with staining. It may only exhibit acute pain on mastication or, possibly, sharp, brief pain to cold. Unless

the crack has progressed to involve the pulp or periodontal tissues, it may be difficult to distinguish from a cusp fracture. Craze lines may be differentiated by transillumination; light will be transmitted throughout the tooth, whereas with a cracked tooth, the crack will block and reflect the light. (Figure 2)

The restorative history of the tooth, while diagnostically helpful for cusp fracture, is not as helpful with cracked teeth. Restorations can be a contributing factor, and the crack may be evident across the cavity floor after a restoration is removed (Figure 5). However, unrestored teeth that are free of caries and teeth with conservative restorations frequently experience these cracks.

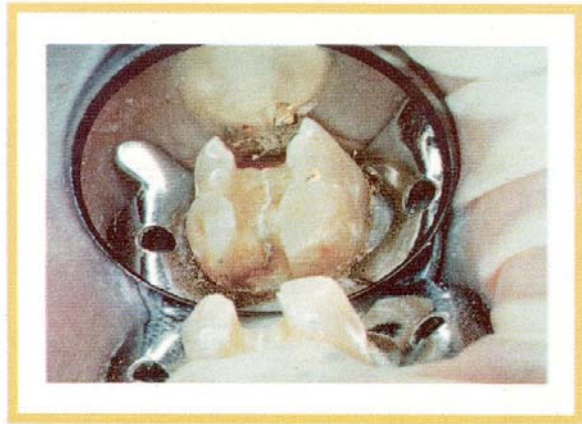


Fig. 5. Cracks may be evident across the floor of the cavity after restoration removal.

If a crack can be detected, use wedging to test for movement of the segments to differentiate a cracked tooth from a fractured cusp or split tooth. No movement with wedging forces implies a cracked tooth. A fractured cusp may break off under slight pressure with no further mobility. A split tooth will show mobility with wedging forces and the mobile segment extends well below the cemento-enamel junction.

Position of the crack may also help differentiate a cracked tooth from a fractured cusp. The crack occurs more toward the center of the occlusal surface than a cusp fracture. More centered cracks tend to go deeper toward the apex before completely separating the tooth into two segments (Figure 4).

If the crack has progressed to involve the pulp or periodontal tissue, the patient may have thermal sensitivity that lingers after removal of the stimulus, or slight to very severe spontaneous pain consistent with irreversible pulpitis, pulp necrosis or apical periodontitis. There may even be pulp necrosis with periapical pathosis.

Treatment Planning

The cracked tooth treatment plan will vary depending on the location and extent of the crack, which can be difficult to determine. Performing root canal treatment must be dependent on the determination of pulpal and periapical diagnosis. A tooth with a minimal crack requires root canal treatment only if the diagnosis indicates a need for it; a tooth with an extensive crack of long duration is more likely to require root canal treatment, but only if the diagnosis indicates. Therefore, pulpal and periapical diagnosis (not just crack detection) determines the treatment plan.

Many cracks are located but are determined not to be extensive, thus requiring no or minimal treatment. However, even when the crack can be located, many times the extent is difficult to determine. Endodontic treatment is often indicated, followed by a cuspal-reinforced restoration (full crown or onlay) to bind the cracked segments and protect the cusps. As stated before, dentin and enamel bonding with adhesive

resins, if placed with special techniques, have been shown to reinforce weakened tooth structure and provide cuspal protection. The placement of intraorifice barriers (plugs) over the root canal filling material may also be beneficial. However, many factors can affect prognosis and each of these must be carefully considered before proceeding with treatment.

Periodontal Probing

Absence of a defect does not rule out the presence of a crack.

Deep narrow, isolated probing indicates an adverse prognosis.

Radiographic Examination

- Findings will depend on pulpal and periapical status, but are usually not significant.
- Vertical or furcal bone loss may indicate a severe crack.
- What has been emphasized in relation to diagnosis to students and general practitioners about the importance of radiographic evaluation and vitality testing has little bearing on the detection of cracks in teeth. Cracks are difficult to visualize on radiographs and teeth may have a crack whether the tooth responds to vitality testing or not.

Banding

If pain to chewing is the only symptom, a tight-fitting band may be cemented to help confirm appropriate treatment for a tooth in which a crack has been detected (Figure 6). The band serves as a splint, holding the crack together. If banding resolves pain to chewing, a full coverage restoration may keep the tooth pain free. If pain continues after banding, further evaluation of the extent of the crack and pulpal and periapical status should be performed.

Continued thermal sensitivity after banding probably indicates that the crack extends near or into the pulp, and root canal treatment will likely be necessary prior to restoring the tooth with a crown.

- Care should be taken during root canal filling procedures to avoid excessive wedging forces that may cause the crack to spread. Cores composed of dentin bonding materials may help prevent the crack from spreading. Posts can exert wedging forces and should be avoided.


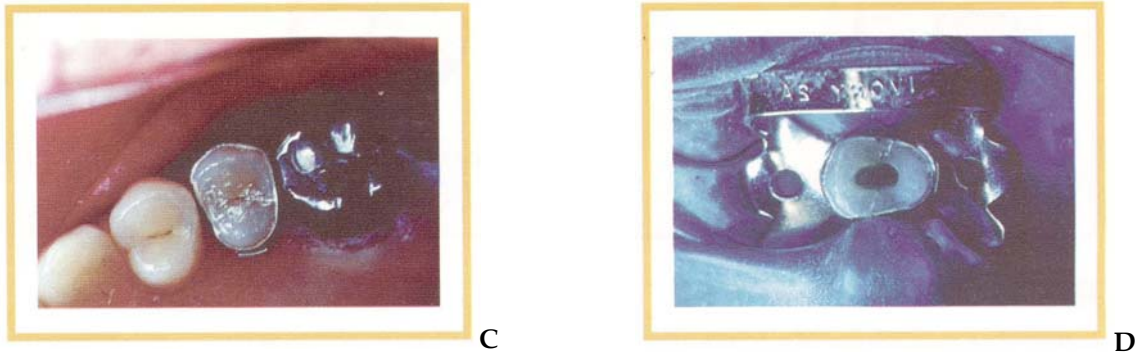


Fig. 6. A cracked second premolar (A) is prepared for banding (B). A band is cemented in place (C) and the tooth is monitored for relief of symptoms. If the crack has not yet reached the pulp chamber, banding should relieve the patient's discomfort. If symptoms persist, the pulpal status of the tooth should be evaluated to determine the need for root canal treatment (D).



Cracks Evident on the Cavity Floor and/or Proximal External Surface

If a crack is evident on the cavity floor and/or proximal external surface, the following should be considered:

Cavity Floor—Removal of the fracture line only in the area of the cavity floor that would include the initiation of an ideal endodontic access opening is helpful in determining the apical extent of the crack and whether the pulp is involved (Figure 4). However, keep in mind that the fracture is small and invisible at its furthest extent (even after staining), and likely continues deeper into the dentin than can be visualized.

Proximal Surface—Removal of the fracture line on the proximal external surface portion of the tooth below the level of the cement-enamel junction is not usually indicated. More information on the extent of the crack may be obtained, but it also is likely to cause the tooth to become nonrestorable. Removal of the proximal marginal ridge and tooth structure associated with the fracture takes away sound tooth structure, thereby decreasing tooth strength and resistance to fracture. However, keep in mind that not removing the crack on the proximal surface may allow bacterial penetration to continue, which could eventually lead to the need for root canal treatment or extraction

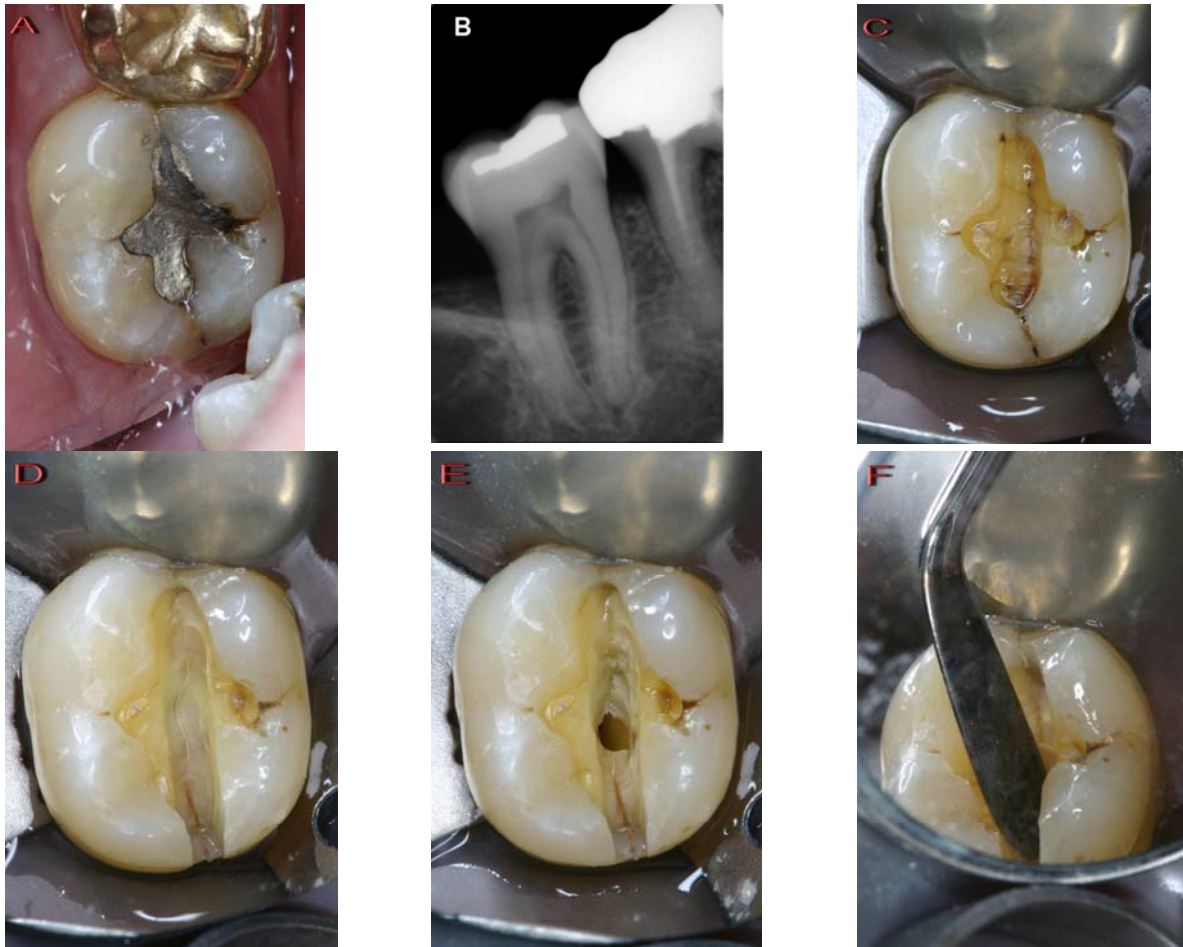


Fig. 7. A cracked tooth involving the mesial and distal marginal ridges of a mandibular second molar (A). Radiograph (B) confirms a small restoration, but no evidence of the crack since this is a two-dimensional representation of a three-dimensional object. After removal of the amalgam restoration, the crack is visualized on the floor of the cavity preparation (C). Removal of dentin along the crack is continued (D) resulting in exposure of the pulp (E). Wedging forces (F) resulted in no movement of the tooth segments indicating an incomplete fracture. Reprinted with permission from Torabinejad and Walton, *Endodontics: Principles and Practice* 4th ed, Saunders/Elsevier 2009.

Endodontic Access

- The practitioner may choose to complete an endodontic access to determine whether the pulpal floor is cracked. However, the practitioner should not try to chase down the extent of the crack with a bur, because the crack becomes invisible long before it terminates and sound dentin will be sacrificed unnecessarily.
- Staining the access cavity may help disclose the crack.
- Magnification and illumination may help confirm the presence of a crack on the pulpal floor. If the crack is visible only partially across the chamber floor, the practitioner may choose to band the crown or place a temporary crown to protect the cusps until root canal treatment can be completed and a permanent restoration placed. If the crack extends the full width of the chamber floor, the prognosis is very poor and the practitioner should consider extraction. In rare cases, resection along the crack may be considered for strategically important molars.

If the crack is visible across the chamber floor and there is a deep periodontal defect, prognosis is generally hopeless.

If wedging forces create mobility of tooth segments, the prognosis is hopeless.

Prognosis

In cases of cracked teeth, the patient should be fully informed that the prognosis is questionable. This is not yet based on research evidence, but is based on the principle that it is better to inform and prepare patients for the potential for failure, especially since these fractures have a tendency to grow with time. The long-term prognosis for a cracked tooth is better when no crack is visible or the crack does not extend to the chamber floor and the tooth is rendered pain free by banding or the placement of a temporary crown. Patients should be advised, however, that cracks may continue to progress and separate. Although treatment will succeed in many cases, some cracked teeth may eventually evolve into split teeth and require extraction. Placement of a cuspal-reinforced restoration, while providing optimum protection for the tooth, does not guarantee success, but is certainly beneficial in most cases.

Only recently have studies been published that outline chances for successful outcomes for cracked teeth, but these studies are limited and only for specific conditions. One 2006 study evaluated a small number (n=50) of root-filled cracked teeth with a diagnosis of irreversible pulpitis and determined a two-year survival rate of 85.5 percent. This study indicated that the only significant prognostic factors were teeth with multiple cracks, terminal teeth in the arch and pre-root filling pocketing. Another study done in 2007 evaluated 127 patients with teeth diagnosed with reversible pulpitis that had a cracked tooth. The treatment was placement of a crown restoration without performing root canal treatment. Twenty percent of these cases converted to irreversible pulpitis or necrosis within six months and required root canal treatment, with none of the other teeth requiring root canal treatment over a six-year evaluation period.

Prognosis is more variable with cracks than with other types of longitudinal fractures. Determining the position and extent may be helpful in determining when to recommend extraction.

Treatment of Extensively Cracked Teeth

A crack that is not separable and extends deeply in the root and/or involves the furcation remains one of the most difficult situations for determining treatment. A cuspal-reinforced restoration (full crown or onlay) to bind the cracked segments and protect the cusp is indicated unless the tooth is to be extracted. Again, pulpal and periapical diagnosis (not just crack detection) determine the final treatment plan. Many factors (i.e., periodontal probing, radiographic examination, need for banding to evaluate reduction of symptoms, etc.) can affect prognosis, and each of these must be carefully considered before proceeding with treatment. While the final determination of the extent of a crack is difficult in these situations, the authors recommend informing the patient of the findings and prognosis, and providing all treatment alternatives.

Techniques that provide more information related to the extent of cracks internally and on the proximal surfaces below the cemento-enamel junction are needed. It is hypothesized that the prognosis decreases from questionable to poor when cracks involve (in order):

One marginal ridge limited to crown

Two marginal ridges limited to crown

Marginal ridge(s) and internal proximal cavity wall only

- Marginal ridge(s) and floor of cavity preparation (may involve restoration removal)
- One marginal ridge extending from crown to root surface (difficult to visualize)
- Two marginal ridges extending from crown to root surface (difficult to visualize)
- Marginal ridge(s) and into canal orifice(s)
- Marginal ridge(s) and pulpal floor
- Furcation involvement (only confirmed after exploratory surgery or extraction)

Alternative treatment plans for these latter conditions involve extraction with replacement by a fixed or removable bridge, or an implant. However, removal of teeth with sound periodontal ligaments is not prudent; keeping natural teeth helps to achieve optimum dental health.

Split Tooth

The term split tooth is defined as a complete fracture initiated from the crown and extending subgingivally, usually directed mesiodistally through both of the marginal ridges and the proximal surfaces. The fracture is located coronally and extends from the crown to the proximal root ([Bonus Material A](#), Figure 4). A crack that is more centered on the occlusion will tend to extend more apically. A split tooth is the evolution (end result) of a cracked tooth; the fracture is now complete and extends to a surface in all areas. The root surface involved is in the middle or apical third, usually extending toward the lingual. There are no dentin connections; tooth segments are now entirely separate (Figures 8, 9). The split may occur suddenly, but it more likely results from long-term growth of an incomplete cracked tooth ([Bonus Material A](#)).

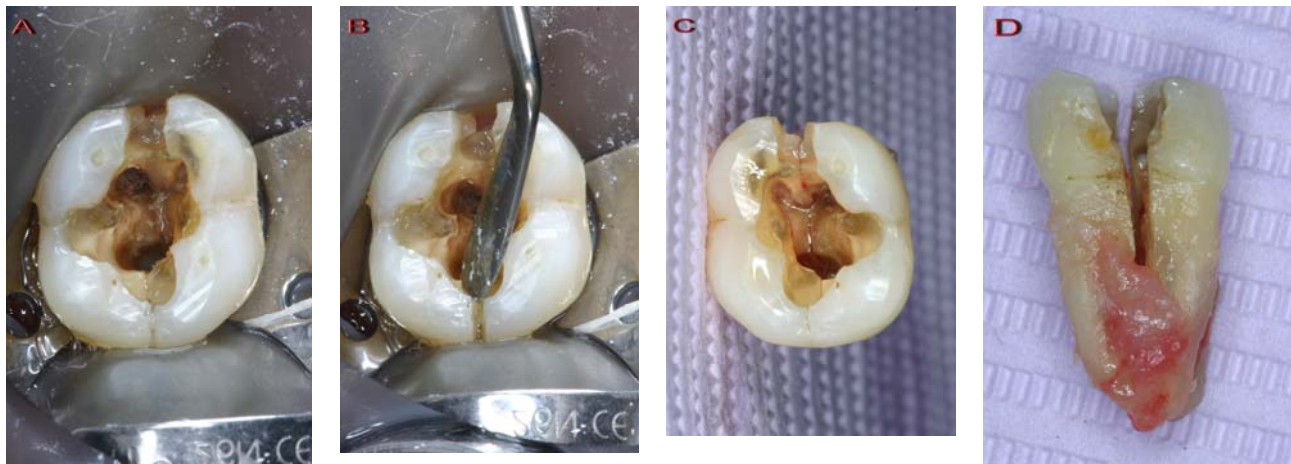


Fig. 8. Split tooth is visualized (A) and confirmed by using wedging forces (B), which resulted in separation of the tooth segment. The extracted tooth (C) highlights the fracture line extending from the mesial marginal ridge, through the floor of the cavity preparation, also involving the distal marginal ridge. The proximal view of the extracted tooth (D) shows a complete fracture that extends deeply to the root surface with infiltration of granulomatous tissue.

A split tooth is identified by a readily apparent or easily disclosed crack with segments that separate with wedging forces, such as probing with an explorer or instrument placed into the occlusal cavity preparation (Figures 8, 9). Patients will usually complain of marked pain to chewing and significant soreness of the jaw or gums. Periodontal involvement, however, may result in a mistaken diagnosis of periodontal abscess.

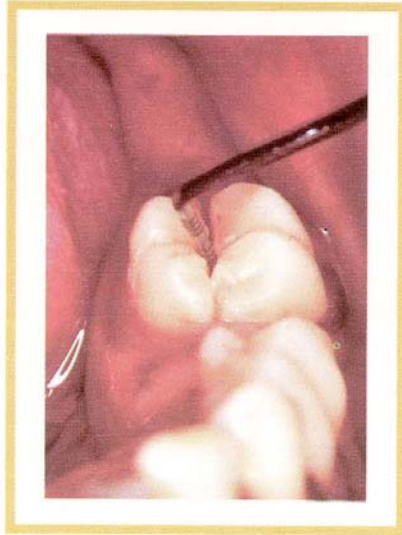


Fig. 9. The segments of a split tooth are generally easy to separate with wedging forces applied with a probe or other instrument.

Treatment Planning

Split teeth can never be saved intact, but the position of the crack and its extent apically will determine the prognosis and treatment. If the fracture is severe (that is, deep apically), the tooth must be extracted. If the fracture shears to a root surface that is not too far apical (middle to cervical third of the root), the smaller segment will be very mobile. Then there is a good possibility that the small segment can be removed and the remainder of the tooth salvaged.

Different approaches to maintenance are used depending on the conditions. Some choices are the following:

Remove the fractured segment, so the type of treatment and restoration can be determined. However, the next choice is preferred and is generally less complicated since bleeding is controlled and a tooth matrix is available to condense the intracoronal restoration.

Retain the fractured segment temporarily. First, a rubber dam is applied with a strong clamp to isolate and hold the segments together. Root canal treatment is completed—if not already performed—and restoration with a retentive bonded core material—onlaying the undermined cusps—or bonded restoration is performed; then the fractured segment is removed. Granulation tissue proliferates to occupy the space and reattach the periodontium to the root dentin surface. The final restoration usually is the bonded core material, but may be a full crown with a margin related to the new attachment.

Remove the fractured segment and perform crown lengthening or orthodontic extrusion. First, the mobile segment is removed and root canal treatment is performed, followed by crown lengthening or orthodontic extrusion, and finally, placement of an appropriate restoration. This is not feasible in most situations because the fracture is too deep on the root surface.

Remove the fractured segment and perform no further treatment. This choice is appropriate when root canal treatment has been completed previously and the tooth is already restored. All pulp space areas must be filled to the margins with permanent restorative material (e.g., amalgam) with no root canal filling material (e.g., gutta-percha or Resilon) exposed. The defect usually granulates in and reattachment to the fractured dentin surface occurs.

Vertical Root Fracture

A “true” vertical root fracture is defined as a complete or incomplete fracture initiated from the root at any level, usually directed buccolingually. The fracture may involve one proximal surface (buccal or lingual) or both buccal and lingual proximal surfaces. The fracture is located in the root portion of the tooth only, and may extend coronally toward the cervical periodontal attachment ([Bonus Material A](#), Figure 10). A review of vertical root fractures has been recently published. A VRF may extend the length of the root or occur as a shorter crack at any level along the root. The crack may or may not extend to both buccal and lingual surfaces (Figure 10).

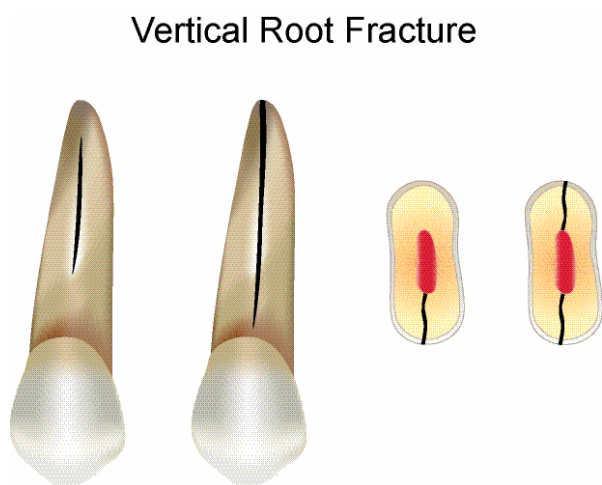


Fig. 10. Facial view of a vertical root fracture, a horizontal cross-section of a VRF affecting only the lingual root surface, and a horizontal cross section of a VRF affecting both the buccal and the lingual root surfaces; root canal-filling material is shown in the canal space.

Because VRFs present minimal signs and symptoms, they generally go unnoticed until periapical pathosis occurs. Then, they are very difficult to diagnose because they mimic other conditions. Because the recommended treatment is almost exclusively extraction or removal of the cracked root, care must be taken to avoid incorrect diagnosis. However, because VRF may mimic periodontal disease or failed root canal treatment, these cases often result in referral to a periodontist or endodontist for evaluation.

Etiological Factors

Many causes for vertical root fracture have been suggested. Two have been demonstrated—post placement and excessive compaction force during root canal filling. Roots that are wide buccally and lingually, but thinner mesially and distally, tend to fracture more often. Examples would be—mandibular incisors and premolars; maxillary second premolars; mesiobuccal roots of maxillary molars; and mesial and distal roots of mandibular molars. Roots of maxillary central incisors, lingual roots of maxillary molars and maxillary canines tend to be rounder and more resistant to VRF.

Diagnostic Clues

Patients typically present with only mild signs and symptoms. The tooth may or may not be mobile; a periodontal abscess may be present or in the patient’s dental history. Virtually all VRFs have a history of root canal treatment.

Periodontal probing can be helpful because the crack may occur at any level along the root and may not reach from apical to cervical. Some VRFs show normal probing patterns, however, most will allow deep probing in narrow or rectangular patterns typical of cracked tooth lesions. Deep probing may be only on the buccal or lingual aspect or on both (Figure 11). Percussion and palpation tests may be inconclusive.

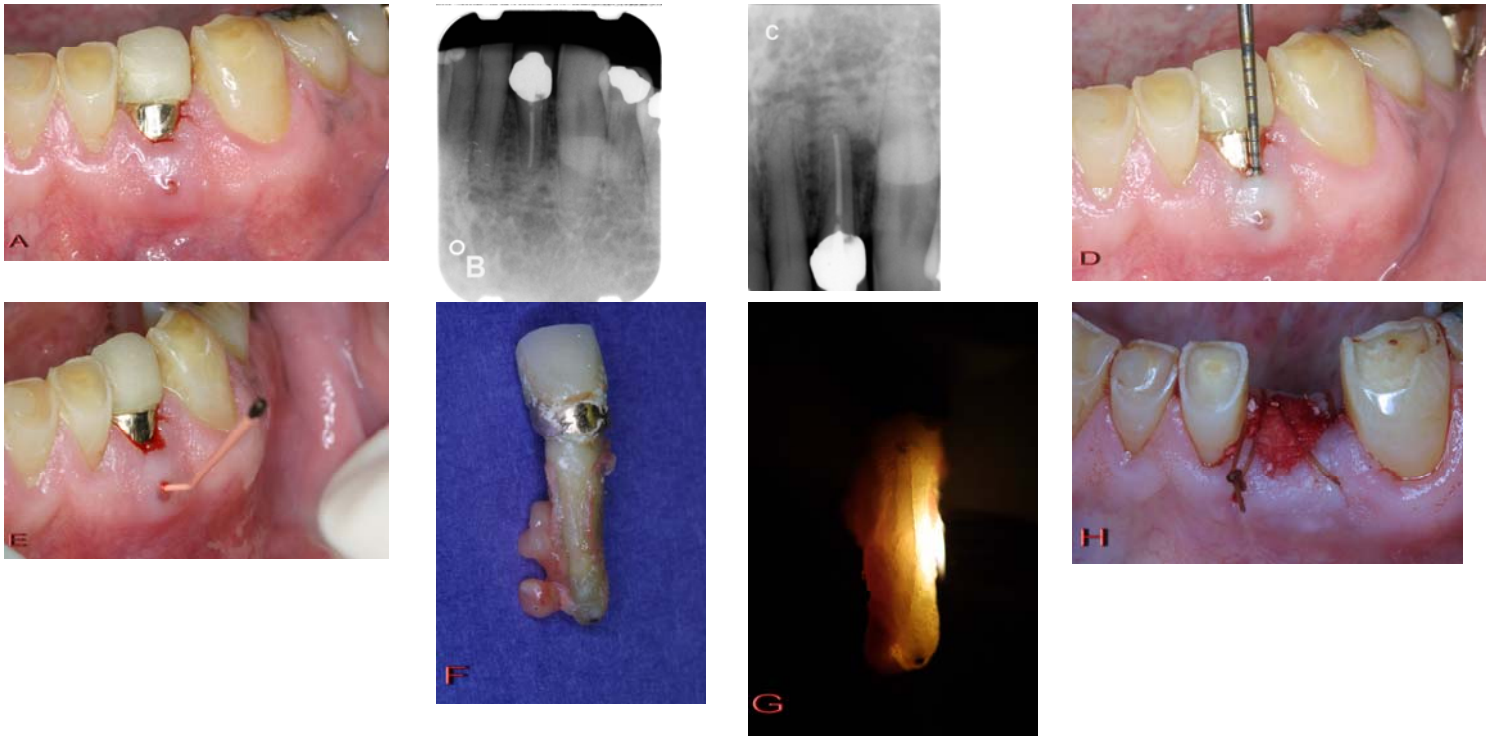


Fig. 11. This mandibular lateral incisor (A) has a history of root canal treatment, placement of a porcelain-fused-to-metal restoration, placement of a gold foil restoration and periodontal flap surgery. A prior radiograph from 14 months prior (B) reveals a healthy periodontium with an intact lamina dura. A recent radiograph (C) reveals the presence of a widened periodontal ligament space apically and a lateral radiolucency distally with loss of lamina dura. A 7mm narrow, isolated periodontal defect (D) and class II mobility is present. A sinus tract on the attached gingiva threaded with a root-filling cone (E) is present. The patient has mild symptoms that include a throbbing sensation. A vertical root fracture is heavily suspected, but not visualized clinically, and the patient elected to have the tooth extracted with the provision that the tooth would be treated and intentionally replanted if no vertical root fracture was detected. Upon extraction and removal of granulomatous tissue from the root, a vertical root fracture was visualized (F) and transilluminated (G). Site preservation was performed with BioOss covered with Colla Plug and the area sutured (H) in preparation for eventual implant or bridge placement. Note that having a sinus tract on attached gingival and a narrow, isolated periodontal probing defect in association with a tooth that has had root canal treatment, with or without a post placement, is considered to be pathognomonic for the presence of a vertical root fracture.

Radiographic evidence varies; only rarely will there be visible separation of the segments (Figure 12). Newer methods of analysis are currently being studied, such as cone beam-computerized tomography, in order to help identify longitudinal fractures in a nondestructive fashion.

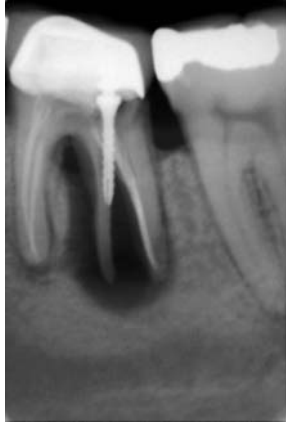

Fig. 12. Classic appearance of a vertical root fracture, although rarely visualized so evidently on the radiograph, showing a tooth that has been root-filled with post placement, separation of the distal root into segments, and a large radiolucency involving the apex, mid-root and furcation of the distal root.

Marked bone resorption from the apex along the lateral root surface can indicate a VRF (Figures 13, 14). Such resorption may or may not extend to the cervical region. The appearance of radiolucency may be mistaken for root canal treatment failure.

Signs, symptoms and radiographs all give variable findings, however, having a sinus tract and a narrow, isolated periodontal probing defect in association with a tooth that has had root canal treatment, with or without a post placement, is considered to be pathognomonic for the presence of a VRF.

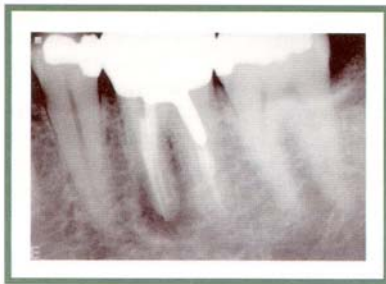


Fig. 13. The diffuse longitudinal radiolucency along the mesial root of #3 is typical for a vertical root fracture that extends from a root surface.

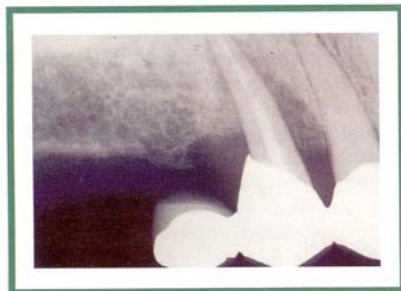

Fig. 14. Marked bone resorption from the apex along the lateral root surface(s) may indicate a cracked tooth or vertical root fracture.

Surgical Assessment

Flap reflection is the only reliable clinical diagnostic approach. Surgical exposure of soft tissue and bone overlying the root surface is the best method of identification. VRFs have consistent patterns (Figures 15, 16). When soft tissue is reflected, a “punched-out” oblong bony defect filled with granulomatous tissue overlying the root is characteristic. This defect may take the form of a dehiscence or fenestration at various root levels. When the inflammatory tissue is removed, the crack is usually evident (Figures 15, 16). In some cases, a crack may be detected when a resected root end is examined under magnification. Even if the crack is not readily detectable, the characteristic bony defect is usually considered conclusive evidence.

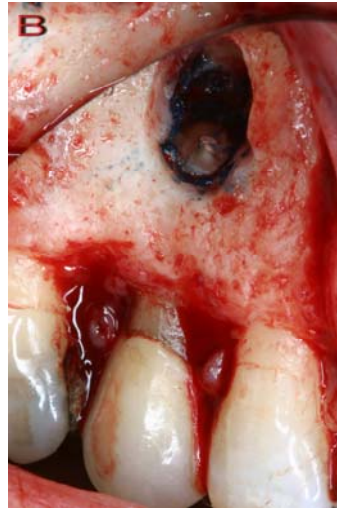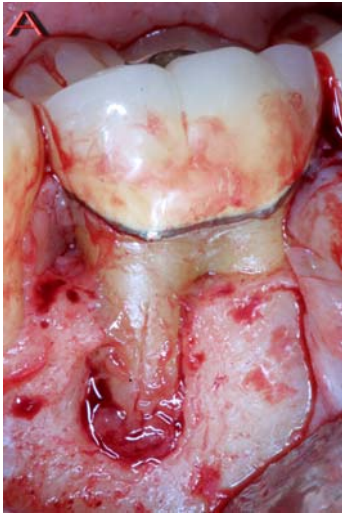


Fig. 15. Patterns of clinical bone loss exhibited with vertical root fractures. No granulomatous tissue may be present after flap reflection, but usually there is a characteristic punched-out, granulomatous tissue filled defect that is diagnostic of vertical root fracture. When the tissue is removed, revealed is a defect that may have a classic V-shaped appearance with loss of marginal bone (A) or may appear as a typical endodontic lesion defect with intact marginal bone as shown on this resected root (B). Transillumination and staining may be beneficial in locating fracture lines (B). All examples have had a history of compaction of root canal filling material and/or a post placement.

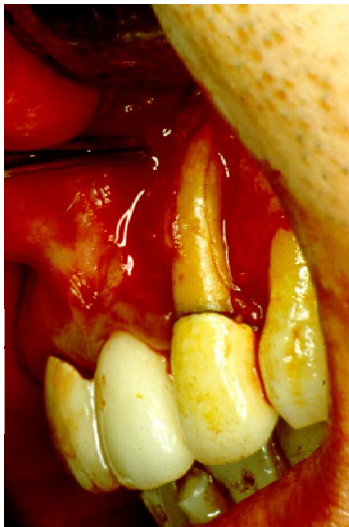

Fig. 16. Surgery may reveal a crack or fracture along the root surface when the inflammatory tissue is removed from the dehiscence; a determination of a vertical root fracture was made.

Treatment Planning

The only predictable treatment is removal of the fractured root or extraction of the tooth. In multirooted teeth, removal of the fractured root may be performed by root amputation (root resection) or hemisection. It is suggested that if these procedures are elected, a restoration be in place in the chamber that extends deeply into the canal spaces that will be resected. The purpose of this deeply placed restoration is to ensure a seal when the root is removed. Root canal filling materials must be replaced by a better sealing restoration when exposed to the oral cavity since they provide poor sealing capabilities when exposed to bacteria. It is difficult to gain access and place new restorations in this area after the root is resected, therefore, having a better sealing restoration than a root filling material already in place upon resection

makes this an easier procedure to accomplish. One disadvantage of this technique is the scatter of fine restoration particles that may lodge into the surgical site.

Other modalities have been suggested in attempts to reduce the fracture or retain the root, such as placement of calcium hydroxide, ligation of the fractured segments or cementation of the fractured segments, trying to bind them by adhesive resins, epoxies or glass ionomer. A unique approach is to extract the tooth, repair the fracture with a laser, cement or bonding agent, and then replant the tooth (into the normal position or inverted 180 degrees). Many of these suggested methods are impractical and have not been shown to be effective long term. Surgical repairs, such as removal of one of the fractured segments or repair with amalgam, resin or adhesives after surgical exposure and preparation, have also been suggested, but successful results have limited documentation. Researchers are looking into new treatments, but, as yet, no method of saving the fractured root has proven practical or effective.

Prevention

Because the causes of VRF are well known, prevention is not difficult. The cardinal rules for safety are to:

1. avoid excessive removal of intraradicular dentin; and
2. minimize internal wedging forces.

The binding strength of root dentin is considerable but is easily compromised. Treatment and restorative procedures that require minimal dentin preparation should be selected. Canal preparation techniques that over enlarge the canal and overly aggressive instruments, such as nickel-titanium files that are more tapered, must be further evaluated with respect to their effect on changing the fracture resistance of teeth. Root canal filling materials that increase the strength of the root must also be evaluated.

Compaction/condensation of root canal filling materials should be carefully controlled. Posts weaken roots and should not be used unless they are necessary to retain a foundation. The post design least likely to cause stress and to fracture dentin is the flexible (including carbon-fiber) or cylindrical (parallel-sided), although these designs are not suitable in all restorative situations. Cast posts or some of the tapered preformed posts may be necessary; their shape may exert wedging forces that readily split roots or cause dentin strain, particularly if they lack a stop or ferrule on the root seat. Any post used should be as small as possible, have a passive fit, and not lock or grip the root internally with threads. Cementation should be done carefully and slowly; an escape vent for the cement is probably helpful. (See [Bonus Material E](#) for more information on post placement in endodontically treated teeth with longitudinal tooth fractures and [Bonus Material F](#) for an extensive list of selected references related to longitudinal tooth fractures.)

SUMMARY

The American Association of Endodontists hopes this issue of *ENDODONTICS: Colleagues for Excellence* will help resolve some of the confusion surrounding tooth cracks. Quick action on the part of practitioners can improve the chances of saving the tooth. If a crack is suspected, the steps outlined above and detailed in the bonus materials should be taken immediately to confirm the presence of a crack, determine the type and formulate an appropriate treatment plan. If you have any additional questions or concerns, your local endodontist is always available as an ongoing resource.

The AAE wishes to thank Drs. Eric Rivera and Richard E. Walton for authoring this issue of the newsletter, as well as the following article reviewers: Drs. James A. Abbott, Michael J. Feldman, Louis E. Rossman, Clara Spatafore and James F. Wolcott.

The information in this newsletter is designed to aid dentists. Practitioners must use their best professional judgment, taking into account the needs of each individual patient when making diagnosis/treatment plans. The AAE neither expressly nor implicitly warrants against any negative results, associated with the application of this information. If you would like more information, consult your endodontic colleague or contact the AAE.

Did you enjoy this issue of *ENDODONTICS*? Are there topics you would like *ENDODONTICS* to cover in the future? We want to hear from you! Send your comments and questions to the American Association of Endodontists at the address below.

American Association of Endodontists
211 E. Chicago Ave., Suite 1100
Chicago, IL 60611-2691
info@aae.org
www.aae.org