

Modern Endodontic Surgery Concepts and Practice: A Review

Syngcuk Kim, DDS, PhD, MD(hon), and Samuel Kratchman, DMD

Abstract

Endodontic surgery has now evolved into endodontic microsurgery. By using state-of-the-art equipment, instruments and materials that match biological concepts with clinical practice, we believe that microsurgical approaches produce predictable outcomes in the healing of lesions of endodontic origin. In this review we attempted to provide the most current concepts, techniques, instruments and materials with the aim of demonstrating how far we have come. Our ultimate goal is to assertively teach the future generation of graduate students and also train our colleagues to incorporate these techniques and concepts into everyday practice. (*J Endod* 2006;32:601–623)

Key Words

Apical surgery, endodontic surgery, microsurgery, MTA, ultrasonic retropreparation

From the Department of Endodontics, School of Dental Medicine, University of Pennsylvania, Philadelphia, Pennsylvania.

Address requests for reprint to Syngcuk Kim, DDS, PhD, MD, Louis I. Grossman Professor and Chair, Director, Microscope Training Center, Department of Endodontics, School of Dental Medicine, University of Pennsylvania, Philadelphia, PA 19008. E-mail address: Syngcuk@pobox.upenn.edu. 0099-2399/\$0 - see front matter

Copyright © 2006 by the American Association of Endodontists.
doi:10.1016/j.joen.2005.12.010

The classic view that endodontic surgery is a last resort is based on past experience with accompanying unsuitable surgical instruments, inadequate vision, frequent postoperative complications, and failures that often resulted in extraction of the tooth. As a result, the surgical approach to endodontic therapy, or surgical endodontics, was taught with minimum enthusiasm at dental schools and was practiced by very few in private practices. Stated simply, endodontic surgery was not considered to be important within the endodontist's domain.

Fortunately, this changed when the microscope, microinstruments, ultrasonic tips, and more biologically acceptable root-end filling materials were introduced in the last decade (Fig. 1). The concurrent development of better techniques has resulted in greater understanding of the apical anatomy, greater treatment success and a more favorable patient response. These developments marked the beginning of the endodontic microsurgery era that began in the 1990s. The purpose of this review is to illustrate the advancements in techniques and theories and, to provide a contemporary perspective of endodontic microsurgery today and how it can be used to improve patient care.

The Differences between Traditional and Microsurgical Techniques in Endodontic Surgery

Endodontic surgery is perceived as difficult because the surgeon must often approximate the location of anatomical structures such as large blood vessels, the mental foramen, and the maxillary sinus. Although the chances of damage to these structures are minimal, traditional endodontic surgery does not have a positive image in the dental profession because of its invasive nature and questionable outcome (1, 2). If we accept the premise that the success of endodontic surgery depends on the removal of all necrotic tissue and complete sealing of the entire root canal system, then the reasons for surgical failure by the traditional approach become clear. Examination of failed clinical cases and extracted teeth by surgical operating microscopes reveal that the surgeon cannot predictably locate, clean, and fill all the complex apical ramifications with traditional surgical techniques. These limitations can only be overcome with the use of the microscope with magnification and illumination and the specificity of microsurgical instruments, especially ultrasonic instruments. Table 1 shows the primary differences between the traditional and microscopic approach to endodontic surgery.

Endodontic microsurgery, as it is now called, combines the magnification and illumination provided by the microscope with the proper use of new microinstruments (1–5). Endodontic microsurgery can be performed with precision and predictability and eliminates the assumptions inherent in traditional surgical approaches.

The advantages of microsurgery include easier identification of root apices, smaller osteotomies and shallower resection angles that conserve cortical bone and root length. In addition, a resected root surface under high magnification and illumination readily reveals anatomical details such as isthmuses, canal fins, microfractures, and lateral canals. Combined with the microscope, the ultrasonic instrument permits conservative, coaxial root-end preparations and precise root-end fillings that satisfy the requirements for mechanical and biological principles of endodontic surgery (1, 5).

Periapical Lesions: Can Complete Healing Occur with Nonsurgical Endodontic Procedures Alone?

The success of endodontic therapy ranges from 53 to 98% when performed the first time (6–8), while that for retreatment cases with periapical lesion is lower (9, 10). The histological status of a periapical lesion shown as a radiolucent lesion on a radio-

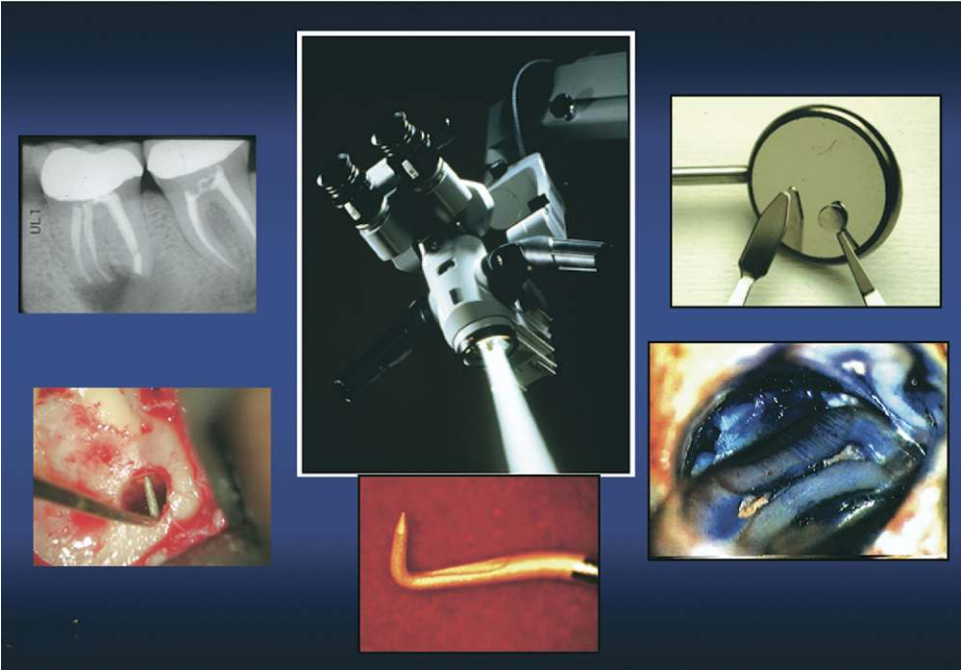

Figure 1. Pictorial representation of endodontic microsurgery. From top center clockwise: micromirrors, isthmus, ultrasonic KiS tip, KiS tip positioned for root-end preparation, radiograph of resected apex, and MTA root-end filled apices.

graph, is unknown to the clinicians at the time of treatment (Fig. 2). The lesion can be a granuloma or a cyst. It is a well-accepted fact that a granuloma heals after endodontic therapy. However, there has been a long-standing debate among dentists as to whether periapical cysts heal after endodontic therapy (11, 12). Endodontists are of the opinion that cystic lesions heal after complete endodontic therapy. Oral surgeons hold the opposing view, that such lesions do not heal and have to be removed surgically. The truth may actually lie somewhere in between. Nair's (13) meticulous serial sections of human periapical lesions showed that overall 52% of the lesions ($n = 256$) were epithelialized, but only 15% were actually periapical cysts (Fig. 2) (14, 15). Periapical cysts can be differentiated into true cysts, which have a completely enclosed lumina, and pocket cysts that are open to the root canal (13, 15). It is the prevailing opinion that pocket cysts heal after endodontic therapy (13, 16, 17), but true periapical cysts may not heal after non-

surgical endodontic therapy (11, 12, 15). Only a subsequent surgical intervention will result in healing of such a lesion. Thus, from a purely pathological point of view, approximately 10% of all periapical lesions require surgery in addition to endodontic treatment. In addition, failed re-treatment cases because of apical transportation or procedural errors, often the result of using NiTi rotary files, are in many cases, best treated by surgical endodontics, especially if they have post restorations (Fig. 3). Further, the complexity of the canal anatomy does not allow 100% success in nonsurgical endodontic therapy, even if the cysts are pocket cysts (Fig. 2). Considering these situations one may wonder why so few surgeries were performed and why surgery was not taught more assertively in the specialty training programs. Fortunately, with the advent of microsurgery, the approach to the management of periapical lesions is changing. Teaching the use of the magnification is now an accreditation requirement of the ADA for endodontic specialty programs. As a result, more private specialty practices have incorporated

TABLE 1. Differences between traditional and microsurgical approaches

	Traditional	Microsurgery
1. Osteotomy size	Approx. 8–10 mm	3–4 mm
2. Bevel angle degree	45–65 degrees	0–10 degrees
3. Inspection of resected root surface	none	always
4. Isthmus identification & treatment	impossible	always
5. Root-end preparation	seldom inside canal	always within canal
6. Root-end preparation instrument	bur	ultrasonic tips
7. Root-end filling material	amalgam	MTA*
8. Sutures	4 × 0 silk	5 × 0, 6 × 0 monofilament
9. Suture removal	7 days post-op	2–3 days post-op
10. Healing Success (over 1 yr)	40–90%	85–96.8%

*Other materials such as SuperEBA are also being used. For details see section on root-end filling.

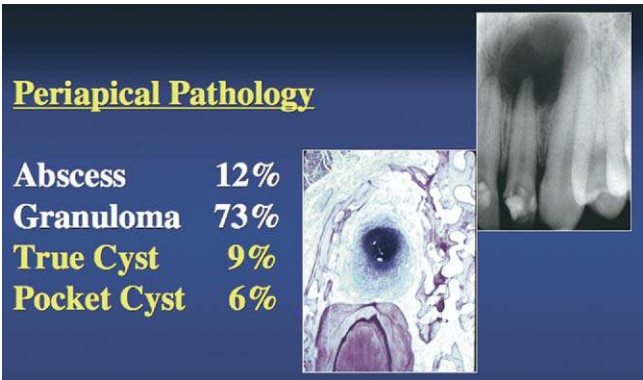


Figure 2. According to Nair (11, 12), 15% of all periapical radiolucencies are some type of cyst. The radiograph shown does not correspond to the histological section, but illustrates the relationship in general.

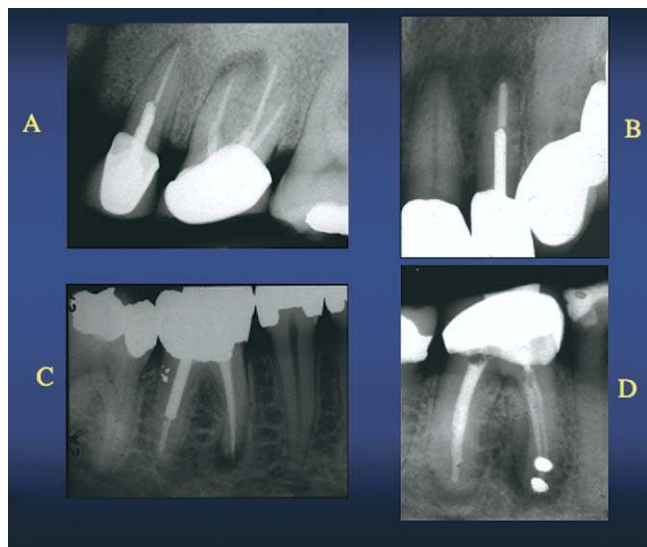

Figure 3. Clinical cases requiring surgical endodontics. The cause of failure in *A* and *C* is apical transportation, which is not easy to correct nonsurgically. (*B*) Shows well executed endodontics, and another attempt of nonsurgical retreatment would most likely fail. (*D*) Shows a failed traditional technique surgery.

microsurgery as a treatment option. When we examine our treatment options, the surgical approach is the more conservative treatment than the nonsurgical treatment for certain cases. A common example is a tooth with acceptable endodontics and a new post and crown restoration, but a persistent or enlarging periapical lesion (Fig. 3*B*). Breaking or disassembling the crown, removing the post and retreating the canals would be more dramatic, more time consuming, more costly and less predictable than a root-end microsurgical retreatment. This surgical retreatment approach has been shown to have a higher success than nonsurgical retreatment provided that periodontal conditions are not compromised (3).

The Operating Microscope: Why is It Essential for Microsurgery?

Microsurgery is defined as a surgical procedure on exceptionally small and complex structures with an operating microscope. The microscope enables the surgeon to assess pathological changes more precisely and to remove pathological lesions with far greater precision, thus minimizing tissue damage during the surgery.

One of the most significant developments in the past decade in endodontics has been the use of the operating microscope for surgical endodontics (1–5, 18). The medical disciplines (e.g. neurosurgery, ENT, and ophthalmology) incorporated the microscope into practice 20 to 30 yr ahead of us. It is now inconceivable that certain procedures in medicine would be performed without the aid of the microscope.

The operating microscope provides important benefits for endodontic microsurgery in the following ways:

1. The surgical field can be inspected at high magnification so that small but important anatomical details, e.g. the extra apex or lateral canals, can be identified and managed. Furthermore, the integrity of the root can be examined with great precision for fractures, perforations, or other signs of damage.
2. Removal of diseased tissues is precise and complete.
3. Distinction between the bone and root tip can easily be made at high magnification, especially with methylene blue staining.

4. At higher magnification the osteotomy can be made small (3–4 mm) and this results in faster healing and less postoperative discomfort.
5. Surgical techniques can be evaluated, e.g. whether the granulomatous tissue was completely removed from the bone crypt.
6. Occupational and physical stress is reduced since using the microscope requires an erect posture. More importantly, the clinical environment is less stressful when clinicians can clearly see the operating field (Fig. 4).
7. The number of radiographs may be reduced or may be eliminated because the surgeon can inspect the apex or apices directly and precisely.
8. Video recordings or digital camera recordings of procedures can be used effectively for education of patients and students.
9. Communication with the referring dentists is improved significantly.

Given these clinical as well as occupational advantages, performing apical surgery without magnification is no longer adequate or defensible. It is disadvantageous for the treating endodontist as well as for the patient. Some may claim that using 3× or 4× loupes is sufficient, however, clinicians who use the microscope would argue that the loupes do not provide enough magnification to detect crucial details. It is interesting that there is a substantial difference in surgery outcome between studies using the microscope (3, 19) and those that do not (20, 21). Although these are not randomized controlled studies directly comparing these two approaches, we believe that surgical outcomes are improved when the clinician can examine the resected root surface carefully, and that omission of this most critical step in microsurgery has a direct effect on the outcome of the surgery. Some may argue that using loupes is good enough. However, the fact is that inspecting the resected root surface with the highest magnification of the microscope is not even good enough. To completely see all the critical anatomical details of the root surface it has to be stained with methylene blue. Using loupes is the first step and a welcome change from unaided vision, but effective magnification and illumination requires the operating microscope.

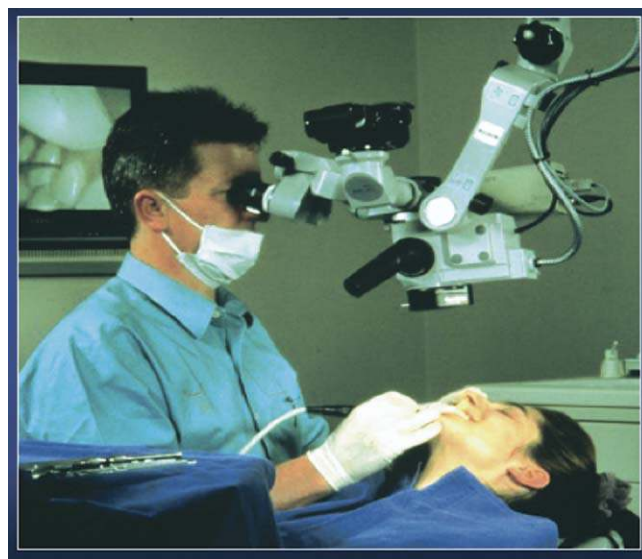


Figure 4. A modern clinical environment in which the microscope provides not only a clinical but also an ergonomic advantage.

TABLE 2. Magnifications for different surgery stages

Magnification	Procedures
Low ($\times 4$ to $\times 8$)	Orientation, inspection of the surgical site, osteotomy, alignment of surgical tips, root-end preparation, and suturing
Midrange ($\times 8$ to $\times 14$)	Most surgical procedures including hemostasis. Removal of granulation tissue, detection of root tips, apicoectomy, root-end preparation, root-end filling
High ($\times 14$ to $\times 26$)	Inspection of resected root surface and root-end filling, observation of fine anatomical details, documentation

Misconceptions About the Operating Microscope

The introduction of any new tool or equipment, if it is designed to produce significant changes, has always led to misconceptions, misinterpretations and resistance. In the 1950s, neurosurgery, ophthalmology, and ENT were done with loupes or even with unaided sight. This is unthinkable today. Of course, apical surgery is not nearly as complex or critical as these fields, but the size of the operating field and the size of the anatomy is not very different.

In every arena, neurosurgery, ENT, and ophthalmology, the process of acceptance was, at first, marked by resistance. Fortunately, we embraced the microscope rather quickly and with enthusiasm. Since 1998, all postgraduate endodontic programs must teach the use of magnification in accordance with the American Dental Association Accreditation Standard for endodontic graduate programs (22).

The frequently asked question, “How powerful is your microscope?” really addresses the issue of usable power. Usable power is the maximum object magnification that can be used in a given clinical situation relative to depth and size of the field. For example, with increasing magnification the depth of field decreases and becomes narrower. Experience suggests that magnification above $30\times$ is of little value in periapical surgery because the slightest movement by the patient, sometimes even breathing, moves the field out of view and out of focus. The surgeon then must repeatedly re-center and refocus the microscope, wasting valuable time. Thus the belief, that “the greater the magnification the better” is a misconception. Table 2 shows suggested magnifications for different surgery stages.

As shown in Table 2, we do not believe that all surgical procedures have to be performed at high magnifications. For certain procedures, low magnification is better than high magnification, because the viewing fields must be large enough, for instance, to properly align the ultrasonic tip.

The microscope does not improve access to the surgical field. If access is limited for traditional surgery, it will also be limited when the microscope is placed between the surgeon and the surgical field. However, the microscope does create a much better view of the surgical field by appropriate magnification and highly focused illumination. Because vision is greatly enhanced, cases can be treated with a high degree of confidence and accuracy. Those who use the microscope routinely wonder how they managed without it in the past. There is a maxim; to see better is to do better and we might add: to do it more easily.

Hemostasis

Local Anesthesia: The Epinephrine Misconception

The main purpose of anesthetics in clinical dentistry, in particular endodontics, is for local anesthesia. In endodontic surgery, however, local anesthesia has two distinct purposes: anesthesia *and* hemostasis. Thus, a high concentration of vasoconstrictor containing anesthetic, e.g. 1:50,000 epinephrine, is preferred to obtain effective vasoconstriction

for lasting hemostasis (1, 23, 24). Because a higher concentration of epinephrine is used, there is a concern as to its effects on the systemic circulation (25).

Some claim that the amount of epinephrine in an infiltration or block injection in dental procedures produces little or no systemic effects (26, 27). Others believe that the amount of epinephrine given as local anesthetic causes systemic effects (25, 28, 29). Virtually all of the adverse effects associated with epinephrine are dose dependent. The New York Heart Association suggested a maximal dose of 0.2 mg of epinephrine for cardiac patients when used in conjunction with procaine. This maximal dose is still referred to and has been used unofficially as a factor by various authors to drive the maximum dosage for other agent (30). Currently recommended maximum dosage of epinephrine 1:50,000 in local anesthetics 2% lidocaine for adults for good hemostasis is 5.5 cartridges to reach 0.2 mg (31).

Although the systemic effects, such as pulse rate and blood pressure, are minimal in response to the amount of epinephrine used in surgical procedures, the study clearly demonstrates that the plasma level of epinephrine is elevated when a high dose is used (25). When a healthy patient was injected with eight cartridges of 2% lidocaine with 144 mg epinephrine, changes in blood pressure, heart rate, and plasma norepinephrine levels were all elevated (25). It appears that virtually all of the adverse effects associated with epinephrine are dose dependent. Furthermore, the results of our preliminary study showed that the amount and concentrations of epinephrine used in endodontic surgery does not usually elicit dramatic and persistent systemic cardiovascular responses. This assessment is supported by the recent study by Vy et al. (31) who showed that placement of 2.25% racemic epinephrine saturated in CollaCote collagen effects little to no changes in blood pressure and pulse rate of human volunteers indicating again that cardiovascular effects by this hemostatic agent is minimal. The cardiovascular effects are minimal and short-lived and are well tolerated by the majority of patients, except patients with severe cardiovascular disorders or who have had cardiovascular surgery. Thus, the use of 1:50,000 epinephrine with 2% lidocaine is recommended for local anesthesia in the majority of cases. With severe cardiac patients, a consultation with his or her physician before the surgery is highly recommended and should be routine in the surgery protocol.

Because many anesthetics are vasodilators the use of anesthetics without vasoconstrictors, such as plain mepivacaine (e.g. 3% Carbo-caine), is not recommended as this will lead to excessive bleeding during surgery.

Mechanism of Vasoconstriction by Epinephrine

Epinephrine binds α -1, α -2, β -1, and β -2 adrenergic receptors located on the vascular smooth muscles. The α -1 receptors are adjacent to sympathetic nerves that innervate blood vessels. The α -2 receptors are distributed throughout the vascular system and are generally bound by circulating catecholamines. When epinephrine binds to the β -1 adrenergic receptors in the heart muscle, the heart rate, cardiac contractility, and peripheral resistance increase. When the drug binds β -2 adrenergic receptors in the peripheral vasculatures, vasodilation results. The β -2 receptors are prevalent in blood vessels that supply skeletal muscles and certain viscera but are relatively rare in mucous membranes, oral tissues, and skin. Ideally, for the purpose of endodontic microsurgery, an adrenergic vasoconstrictor would be a pure α -agonist. Fortunately, the predominant receptors in the oral tissues are α -receptors, and the number of collocated β -2 receptors is very small (Fig. 5). Thus, the drug's predominant effect in the oral mucosa, submucosa and periodontium is vasoconstriction. Because virtually all adverse effects associated with epinephrine are dose and route depen-

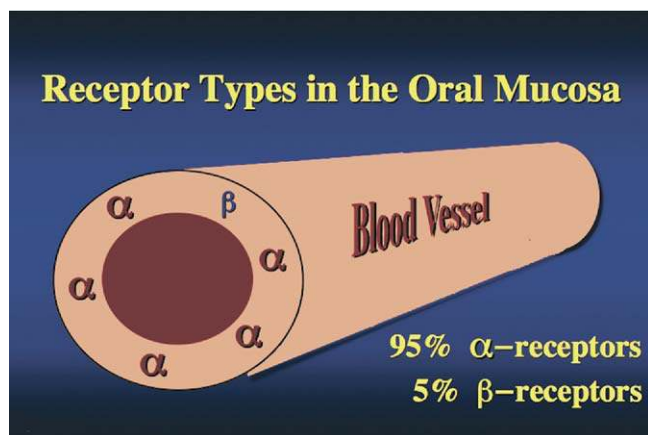


Figure 5. Schematic diagram illustrating the density of adrenergic receptors in blood vessels of the oral mucosa. (Reprinted with permission from color atlas of Microsurgery in Endodontics, by S. Kim with G. Pecora and R. Rubinstein. W.B. Saunders Co., A Harcourt Health Sciences Company, 2001.)

dent, clinicians should use the appropriate dose with an aspirating syringe.

Surgical Hemostats

Topical hemostats or local hemostatic agents are useful adjuncts for hemostasis. Once an incision has been made and the flap is reflected, topical hemostats, in many situations, play an important role in achieving hemostasis. They can be broadly classified by their mechanism of action (32):

There are numerous agents on the market. Only some of the popular, effective and frequently used agents will be discussed (Table 3).

Bone Wax

The use of bone wax (Ethicon, Somerville, NJ) as a local hemostatic agent was first introduced by Horsley (33). In 1970, Selden (34) found bone wax to be an effective hemostat in periapical surgery. Bone wax contains a large percentage of highly purified beeswax and a softening and conditioning agent (isopropyl palmitate). With bone wax, the hemostatic mechanism has essentially a tamponade effect. The wax, when placed under moderate pressure, plugs all vascular openings. The plug is formed partly of blood and partly of bone wax, which prevents further bleeding. The method of action is purely mechanical and does not affect the blood clotting mechanism.

When using bone wax for hemostasis it should first be packed firmly into the entire cavity, and then the excess should be carefully removed to expose only the apex of the tooth. Following root-end filling, the wax should be removed. Studies have shown that bone wax causes a foreign body reaction if left in the surgical site. Ibarrola et al. (35) showed that in rats the wax consistently produced inflammatory reactions. Bone wax residues have also been associated with sinus tracts that developed after surgery, suggesting that care must be exercised to ensure the complete removal of this material from the surgical site. Therefore, bone wax is infrequently used in endodontic microsurgery.

Epinephrine Cotton Pellet

This is a mechanical/chemical agent. Racellets (Pascal Co., Bellevue, WA) are cotton pellets containing racemic epinephrine hydrochloride. The amount of epinephrine in each pellet varies. For example, each Racellet #3 pellet contains an average of 0.55-mg racemic epinephrine. Each Racellet #2 pellet contains 1.15 mg of racemic epinephrine hydrochloride. It has been shown that when Racellet #2 was used in

periapical surgery, the pulse rate of patients did not change with the application of pressure to the bone cavity (36). Because epinephrine used topically causes immediate local vasoconstriction, there is little absorption into the systemic circulation and thus there are practically no systemic effects.

Other hemostatic cotton pellets with epinephrine are Epidri (Pascal Co.), that contain an average of 1.9 mg racemic epinephrine hydrochloride, and Radri (Pascal Co.) that has a combination of vasoconstrictor and astringent. Each pellet of Radri contains an average of 0.45-mg racemic epinephrine hydrochloride and 1.85 mg of zinc phenol sulfonate.

Before placing an epinephrine pellet all the granulomatous tissue should be removed from the bone cavity. The first epinephrine pellet is placed against the bone and is followed by packing the cavity with sterile cotton pellets one at a time. Pressure is applied over these sterile pellets using the back of a hand mirror or college pliers for about 2 to 4 min. The sterile cotton pellets are then removed one at a time taking care not to dislodge the epinephrine pellet. If bleeding still occurs, the procedure is repeated with a new epinephrine pellet until hemostasis is achieved. The combination of both epinephrine and pressure has a profound effect that usually results in immediate and profound vasoconstriction. Epinephrine causes local vasoconstriction by acting on the α -1 receptors present in the blood vessels wall, and the pressure augments this hemostatic potential. The epinephrine cotton pellet also prevents debris from getting lodged into the bone crypt during root-end preparation and root-end filling. The pellet must be removed before the final irrigation and closure of the surgical site.

Ferric Sulfate

Another chemical agent used in hemostasis is ferric sulfate: Stasis (Cut-Trol, Mobile, AL), Viscostat, and Astringent (Ultradent Products, Inc., UT). Ferric sulfate or ferric subsulfate is a hemostatic agent that has a long history. It was first used in medicine in 1857 as Monsel's solution, which is 20% ferric sulfate. Even though the mechanism of Monsel's solution is still debated, agglutination of blood proteins results from the reaction of blood with both ferric and sulfate ions and with the acidic pH (0.21) of the solution (37). The agglutinated proteins form plugs that occlude the capillary orifices. Thus, in contrast to traditional hemostatic agents, ferric sulfate affects hemostasis through a chemical reaction with blood.

Ferric sulfate is easy to apply and there is no need to apply any pressure. A dark brown or greenish brown coagulum forms immediately on contact with blood and the source of any persistent hemorrhage can be located because of the color difference. Thus, any bleeding point can be easily identified and hemostasis is achieved almost immediately. Although ferric sulfate is known to be cytotoxic and to cause tissue necrosis, systemic absorption of ferric sulfate is unlikely, because the coagulum isolates it from the vascular supply. Care must be taken, however, not to leave ferric sulfate solution in the bone because it has significant adverse effects on osseous healing (38). Therefore, the surgical site must be thoroughly flushed with saline to remove the ferric sulfate completely so that there is no complication or delay in healing.

TABLE 3. Hemostatic agents by mechanism of action

Mechanical agents	Bone wax
Chemical agents	Vasoconstrictors (epinephrine)
	Ferric sulfate
Biological agents	Thrombin
Resorbable agents	Calcium sulfate
	Gelfoam
	Absorbable collagen
	Microfibrillar collagen
	Surgicel

Thrombin

Topical thrombin USP (Thrombostat, Thrombogen) is a protein substance that is produced in a conversion reaction from bovine prothrombin. It is a potent dry powder that acts rapidly in an intrinsic fashion to clot the blood fibrinogen directly. Thrombin USP is used widely in the medical field to achieve localized hemostasis; however, its use in endodontic surgery has not been investigated. The main disadvantage of topical thrombin is that it is difficult to handle and to deliver to the bleeding site. It is also expensive.

Recommended Clinical Steps for Achieving Hemostasis

There are numerous ways to achieve hemostasis. With the abundance of available hemostatic agents and with the introduction of new products, the choice has to be based on objective evaluation. A good agent achieves hemostasis within a short period of time, is biocompatible, does not impair or retard healing, is reliable and works best for the particular surgical procedure and lastly, it is relatively inexpensive. With these purposes in mind, the following sequence is recommended to achieve effective hemostasis during endodontic microsurgery.

Presurgical

Inject two carpules (maximum three carpules in special situations) of 1:50,000 epinephrine containing local anesthetic, e.g. 2% Xylocaine, into multiple infiltration sites buccal/lingual and palatal throughout the entire surgical field. Wait at least 15 to 20 min for the vasoactive agent in the anesthetic to constrict the blood vessels in the soft tissues as well as in the hard tissues before making the first incision.

Surgical

- A. Remove all granulated tissue, quickly and completely because this tissue is highly vascularized and, therefore, bleeds profusely.
- B. Place an epinephrine pellet into the bone crypt followed by dry sterile cotton pellets until the crypt is filled. Apply pressure for 2 min. Remove all cotton pellets except for the first epinephrine pellet. Continue with the surgical procedure and remove the epinephrine pellet before final irrigation and closure.
- C. Small bleeders from the bone can be stilled by dabbing them with a cotton pellet soaked with ferric sulfate solution. All of the ferric sulfate deposits must be carefully and thoroughly removed by saline flush, as they are a major irritant to the tissues if left in-situ.
- D. A large osteotomy site is filled with freshly mixed calcium sulfate paste. After setting hardened calcium sulfate is carved out around the root. Although the paste is not designed for hemostasis per se, it is very effective agent for hemostasis for a large bone crypt. The calcium sulfate paste can then be left in the crypt because it is resorbable.

Figure 6 summarizes these recommendations.

Postsurgical

Moist gauze compresses should be applied to the tissues before and after suturing to remove blood clots between the bone and soft tissues, to assure proper alignment of the flap and to reduce stress on the suture lines.

Effective and complete hemostasis is imperative in endodontic microsurgery for good visualization, a dry environment for placement of root-end filling materials, and a more efficient surgical procedure with less blood loss.

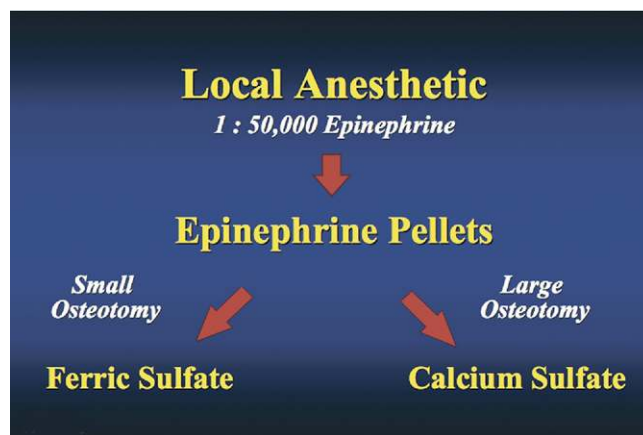


Figure 6. Schematic diagram illustrating hemostatic techniques employed at the University of Pennsylvania. (Reprinted with permission from Color Atlas of Microsurgery in Endodontics, by S. Kim with G. Pecora and R. Rubinstein. W.B. Saunders Co., A Harcourt Health Sciences Company, 2001.)

Soft-Tissue Management: New Concepts and Practice

The following management procedures have changed from the traditional techniques. First, the semilunar incision, the most popular flap design technique with anterior teeth, is no longer recommended because of inadequate access and scar formation (39). Second, the removal of sutures is done within 48 to 72 h, not a week (1, 5). Third, new suture materials are monofilament, gauge 5×0 or 6×0 to provide rapid healing (1, 5). Fourth, the papilla base incision (PBI) has been developed to prevent loss of interdental papilla height with sulcular incisions (40). Fifth, flap retraction during the surgery is facilitated by making a resting groove in the bone, especially during mandibular posterior surgery, to ensure retraction (1).

Fundamentally, the flap designs are very similar to those of the traditional techniques: the sulcular full-thickness flap, the muco-gingival flap and vertical releasing incisions (41, 42). The once popular semilunar flap design and the Luebke-Ochsenbein flap design are no longer recommended. In both the sulcular full-thickness flap and the muco-gingival flap designs, the wider base of the flap to improve microcirculatory perfusion was an unnecessary procedure, and it created a lasting scar as a result of cutting the mucosal tissue across the fiber lines (1, 41). With the current method the base of the flap is as wide as the top, and the vertical incisions follow the vertical blood vessel alignment. This facilitates nearly scar-free healing while still providing more than adequate access to the surgical site.

In the sulcular full-thickness flap design, the main disadvantage is recession and shrinkage of the papilla (40, 43). Velvart (40, 44) proposed the PBI for the marginal mucoperiosteal flap to prevent or minimize loss of interdental papillary height. A recent article by Velvart and Peters (2005) provides an excellent review on this subject (45).

It has been customary to remove 4×0 silk sutures after 1 wk. With the microsurgery technique, monofilament sutures are removed within 48 to 72 h for best results (1, 5). This is enough time for reattachment to take place and the suture removal is easy and painless (Fig. 7). After 72 h, the tissues tend to grow over the sutures, especially with mucosal tissues, and thus removal of sutures may be more uncomfortable.

Suture materials often used now are the thinner monofilament polyamide with smaller needles. The 5×0 and 6×0 sutures are ideal for microsurgery and polypropylene sutures (6/0 or 7/0) are also popular (44). The use of 4×0 silk sutures is no longer acceptable because the silk is braided and causes accumulation of plaque causing delayed healing or secondary inflammation (1). The thinner and smaller mono-

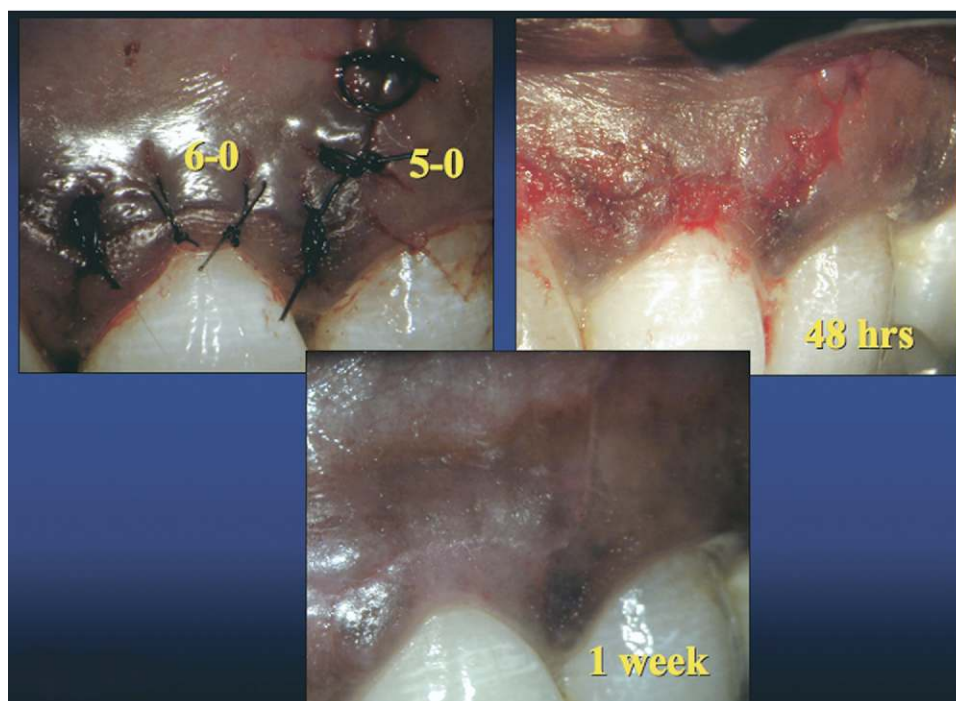


Figure 7. Micro-suturing with 5×0 and 6×0 monofilament sutures (top left); suture removal after 48 h (top right) and tissue healing 1 wk postoperatively.

filament sutures promote a cleaner surgical site and thus rapid healing. With the incorporation of new materials, concepts, and technique modification, healing after surgery leaves almost no scars. In this age, when esthetics in dentistry is important, microsurgery also contributes to the highest esthetic standards in this field.

Atraumatic Tissue Retraction and the Groove Technique

In the past, the importance of good and stable retraction was not understood. Surgeons thought that retraction is the assistant's job and paid little attention to the consequences and complications associated with poor retraction.

One of the key factors in postoperative tissue swelling is because of frequent slippage of the retractor during surgery (1). This is also the main cause of transient parasthesia in the mandibular molar/premolar region (1). To address this problem, retractors of several shapes and sizes were developed to permit stable and nontraumatic retraction. These retractors have wider (15 mm) and thinner (0.5 mm) serrated working ends compared to the standard retractors (1). Some are concave while others are convex to accommodate the irregular contours of the buccal plates. The serrated tips provide better anchorage on the bone and are designed to prevent slippage during retraction.

In addition to contour specific retractors, a new procedure has been developed to protect the mandibular nerve and prevent postoperative problems, such as parasthesia, when operating in the molar/premolar region near the mental foramen. A 15-mm long horizontal groove is cut into the water-cooled bone with a Lindemann bur or a #4 round bur. This groove must be made beyond the apex to allow space for the osteotomy and subsequent apicoectomy. The groove permits secure anchoring of the serrated retractor tip and secure, steady retraction of the flap. As shown in Fig. 8, a safe and efficient way to make a groove above the mental foramen is to first identify the foramen, then carefully cover it with the retractor and then make the groove just above it. Once the retractor is in position within the groove, there should be no movement or slippage.

Osteotomy: Smaller is Better

Does the size of the apical lesion make a difference? This is an argument that has been studied extensively, but is still an area of debate. Boyne et al. (46) in his study examined nine patients with 21 periapical defects in the anterior region with at least one cortical plate remaining intact. The sizes were divided into two groups of lesions ranging from 5 to 8 mm and 9 to 12 mm. Biopsies were taken at 4, 5, and 8 months. It was found that 9 to 12-mm defects had herniation with fibrous tissue, while the smaller defects had complete bone regeneration. In 1970, Hjorting-Hansen (47) showed that cavity spaces up to 5 mm showed complete bone regeneration independent of anatomic site. Hjorting-Hansen and Andreason (48) did a similar study on dogs. The results showed complete healing at 5 mm with one cortical plate intact. However, if both plates were removed, incomplete healing resulted. The larger size lesions showed healing, but with fibrous tissue. The authors concluded that the size of the lesion matters as well as the removal of one, or both cortical plates. These studies suggest that the larger the defect, the smaller the chance that complete healing will take place.

A recent study on healing, as evidenced by radiographic changes, showed that there is a direct relationship between the size of the osteotomy and the speed of healing: the smaller the osteotomy, the faster the healing. For instance, a lesion smaller than 5 mm would take on average 6.4 months, a 6 to 10 mm size lesion takes 7.25 months and larger than 10 mm requires 11 months to heal (3). Thus, the osteotomy should be as small as possible but as large as necessary to accomplish the clinical objective. There is a tendency during surgery to enlarge the osteotomy towards the coronal margin, away from the apex. This tendency results in excessive removal of healthy bone around the neck of the crown easily causing a perio-endo communication. When this happens, the long-term prognosis for the tooth is poor. With the microsurgical techniques, the size of the osteotomy is significantly smaller, just 3 to 4 mm in diameter. This is just larger than an ultrasonic tip of 3 mm in length, yet allows the tip to vibrate freely within the bone cavity (Fig. 9).

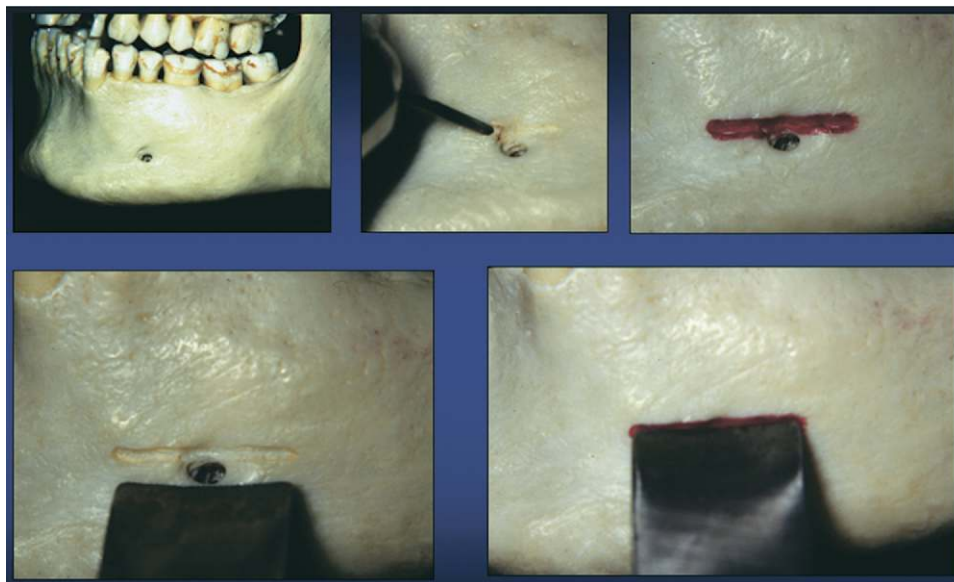


Figure 8. The Groove Technique: a small narrow horizontal groove is made just above the mental foramen. A KP#1 retractor is firmly seated in the groove protecting the nerve during the osteotomy.

Distinction Between Bone and Root Tip Under the Microscope

A major purpose of using the microscope during the osteotomy is to clearly distinguish the root tip from the surrounding bone. As mentioned earlier, this differentiation is one of the most important advantages of using the microscope (see Microscope section). It would be ideal to locate the root tip precisely all the time. However, if the apical lesion has not fenestrated or if the lesion extends lingually, then locating the apex can be a real challenge, even for the experienced surgeon. Once the access cavity has been prepared, the osteotomy must be examined carefully to ascertain whether the root tip can be seen. The root has a darker, yellowish color and is hard, whereas the bone is white,

soft, and bleeds when scrapped with a probe (1). This step is essential for keeping the size of the osteotomy small. If the initial osteotomy is prepared without magnified examination, the chances are that the osteotomy will be too large and thus violating one of the main advantages of microsurgery. If the root tip can not be seen, careful drilling and microscopic examination along with applying methylene blue stain, preferentially staining the periodontal ligament, allows root tip identification as well as a small osteotomy.

The Bevel Angle: Is it Necessary?

Elimination or minimization of the bevel angle is one of the most important benefits of microsurgery. With the traditional rotary bur, the steep bevel angle of 45 to 60 degrees was recommended (49–52). The purpose of this steep bevel was simply for access and visibility (Fig. 10) (51). In fact, with the traditional techniques beveling to this degree was inevitable, since the surgical instruments were large. The following is a comparison of bevel angles created by the traditional rotary bur tech-

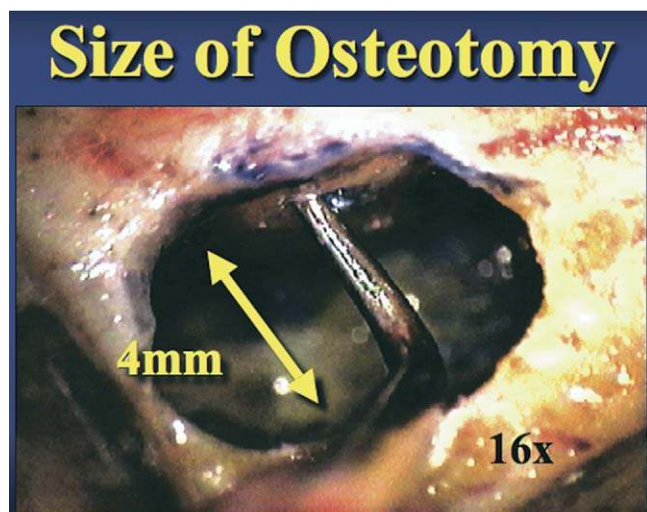

Figure 9. The ideal osteotomy measures ca. 4 mm in diameter allowing a 3 mm ultrasonic tip to move freely within the bone crypt. This by the microsurgical osteotomy is compared with a much larger traditional size osteotomy. (Reprinted with permission from Color Atlas of Microsurgery in Endodontics, by S. Kim with G. Pecora and R. Rubinstein. W.B. Saunders Co., A Harcourt Health Sciences Company, 2001.)

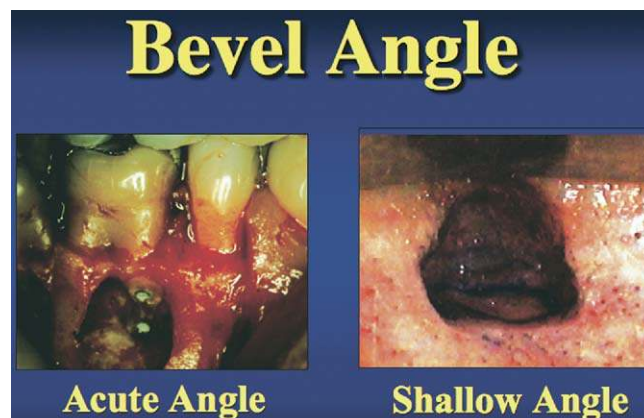


Figure 10. A comparison of a large osteotomy and acute bevel angle made by the traditional bur method (left) with a smaller osteotomy without bevel angle, made by the microsurgical method (right). The image at right is 10× larger than the left image.

TABLE 4. Comparison of bevel angles created by traditional and microsurgical techniques

Microsurgical Technique	Traditional Technique
<ul style="list-style-type: none"> • No bevel or less than 10 degrees • Expose few dentinal tubules • Small osteotomy • Minimal loss of buccal plate • No danger of perio communication • Easy identification of apices • No lingual perforation 	<ul style="list-style-type: none"> • Acute Bevel (45–60 degrees) • Exposure many tubules • Large osteotomy • Greater loss of buccal plate • Great danger of perio communication • Frequent missing of lingual apex • Easy lingual perforation

nique and the perpendicular preparation (no bevel) done with the microsurgical technique (Table 4).

There is no biological justification for a steep bevel angle. It was strictly for the convenience of the surgeons for apex identification and for the subsequent apical preparation (1, 2). In fact, beveling causes significant damage to the very tissue structures that the surgery is designed to save, i.e. buccal bone and root. By diagonal resection, the result of steep beveling, the buccal bone is removed along with a large area of the root causing, in effect, a large osteotomy. Furthermore, beveling frequently misses the lingually positioned apex, causes elongation of the canal and reduction of the root diameter, thereby weakening it (1, 5, 53).

Root-End Resection

How Much Should be Resected?

There is no complete agreement as to how much of the root has to be resected to satisfy biological principles. Gilheany et al. (54) suggests that at least 2 mm be removed to minimize bacterial leakage from the canals. Our anatomical study of the root apex shows that at least 3 mm of the root-end must be removed to reduce 98% of the apical ramifications and 93% of the lateral canals (1). As these percentages are very similar at 4 mm from the apex, we recommend root-end amputation of 3 mm, since this leaves on average of 7 to 9 mm of the root, providing sufficient strength and stability. A root-end amputation of less than 3 mm does, most likely, not remove all of the lateral canals and apical ramifications, therefore, posing a risk of reinfection and eventual failure (Figs. 11 and 12).

Anatomy of the Root Outline After Root-End Resection

The anatomy of the root outline varies greatly. Its shape can be oval, ovoid, reniform and various other irregular forms (51, 55). The oval or ovoid shapes are frequently found in single roots while the more complex shapes, e.g. reniform is found in fused premolar or molar roots. In surgery, it is essential that the entire root-end be resected. It is a frequent occurrence in failed surgical cases, that only the buccal aspect of the root was resected leaving the lingual apex in situ. The result is a continuous infection from the lingual apex (4). This situation is more frequent in premolars and molars with fused roots and can be avoided by staining the resected root surface with methylene blue (details in following section).

Inspection and Management of the Resected Root Surface; the Most Important Step in Microsurgery!

Once a root tip is resected perpendicular to the long axis of the root, proper identification of anatomical details and their management are some of the most important and unique steps in microsurgery and are critical for the success of the treatment (1). Unfortunately, this surgical procedure cannot be done adequately and precisely with un-

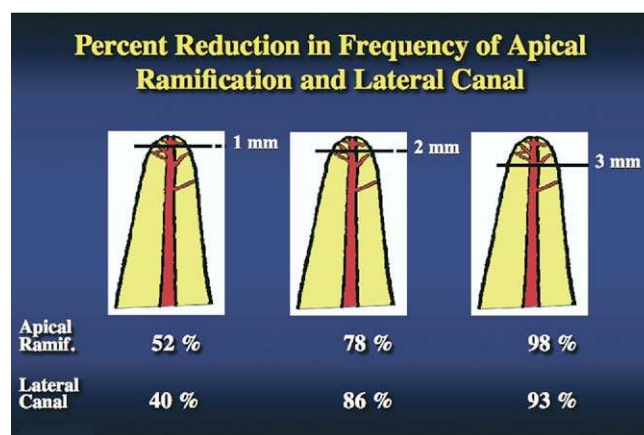


Figure 11. Frequency of apical ramifications and lateral canals. A 3-mm apical resection was needed to eliminate the majority of apical ramifications and lateral canals. (Reprinted with permission from Color Atlas of Microsurgery in Endodontics, by S. Kim with G. Pecora and R. Rubinstein. W.B. Saunders Co., A Harcourt Health Sciences Company, 2001.)

aided vision or even with loupes. Only the high magnification of a microscope provides the light and the magnification to completely see the anatomical details of the resected root surface (1, 3–5, 42, 53). One of the fundamental drawbacks of the traditional root-end resection technique without magnification and microinstruments is the inability to manage and to adequately inspect the anatomical details of the root surface. In contrast, with the bright illumination and the range of magnification of the operating microscope from 4× to 25×, the resected root surface can be examined in great detail. Yet, a complete and critical inspection of the resected root surface requires staining of the surface with a contrasting medium, such as methylene blue, that stains the PDL and pulp tissues selectively (4, 5). With the aid of micromirrors placed at 45 degrees to the surface, the reflected view of the root surface shows every anatomical detail of the canal system, which is critical for a successful surgery. This is equally important for surgical retreatment cases, in which this step also identifies the causes of failure of the previous surgical procedure. It is the inspection of the resected root surface, which shows why and how the traditional apical surgical technique was highly inadequate.

As pointed out earlier, the anatomical details of the resected root surface are complex. All types of shapes and forms can be found in the

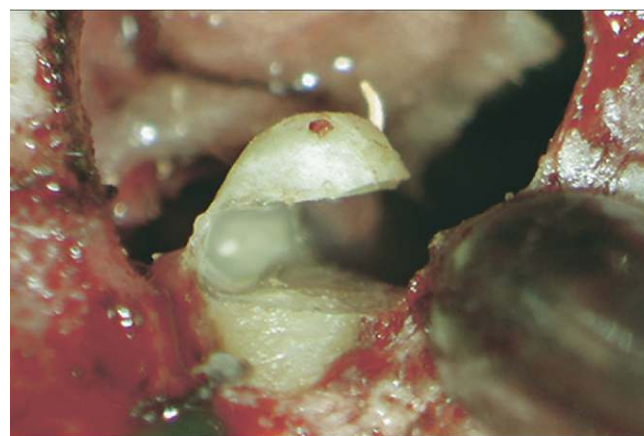

Figure 12. A digital image of a 3 mm apical resection on a maxillary premolar. (Photo by Dr. F. Maggiore, Germany.)

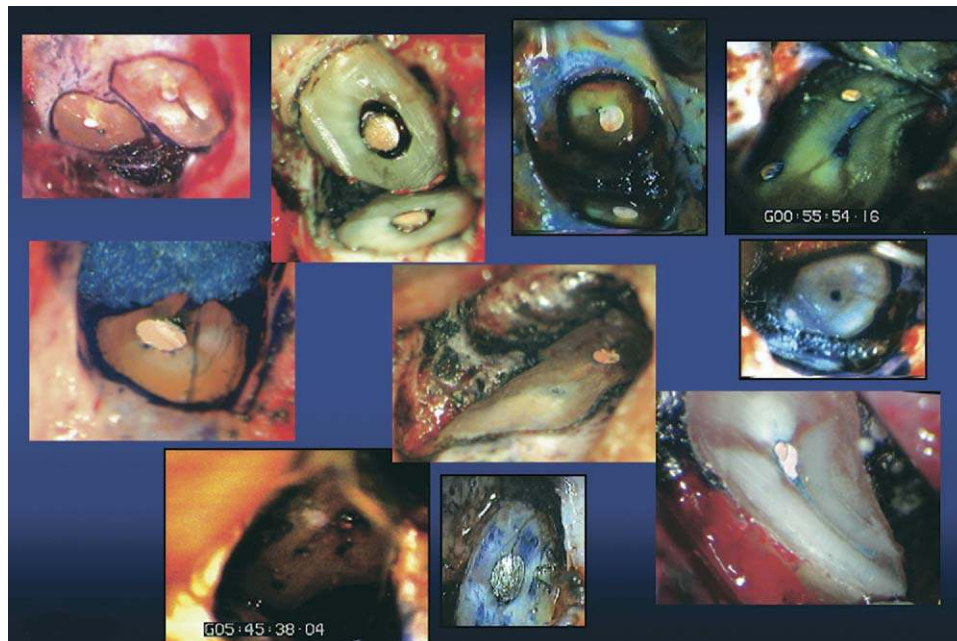

Figure 13. Inspection of this resected root surfaces shows several types of apical configurations, isthmi and anatomies.

canal system. When cutting the root perpendicular to its long axis, round, oval, horseshoe shaped, S-shaped, two to five small round and oval shaped canals and isthmuses, and so forth, can be observed (Fig. 13). This important step in microsurgery is not considered at all in the traditional surgical technique.

Consequences of Apical Curettage Without Root-end Resection and Root-end Resection Without Root-End Filling

A survey of the literature does not provide any conclusion as to which is the best option as many of these studies include the old surgical techniques and some studies are inadequate in terms of duration and number of cases observed (56–60). However, the following observations can be made: Because the major cause of periapical lesions is a leaky apical seal with attendant egress of microorganisms and their toxins, the removal of the diseased periapical tissues by periradicular curettage eliminates only the effect of the leakage, not the cause. Thus, elimination of the periradicular lesion alone will likely result in the recurrence of the lesion. Initially, there may be a cessation of symptoms and a radiographical improvement, but this is only temporary. As the initial healing surge plateaus, the slower but persistent pathosis prevails, and the case will eventually fail again. Up to this point, there is total agreement among endodontists, because a leaky root filling or an untreated accessory canal or isthmus causes problems. For a failed non-surgical case, nonsurgical retreatment should be attempted first, provided that the benefits of this retreatment outweigh the surgical retreatment. Apical surgery entails not just the removal of the diseased tissue or the root tip, but most importantly resealing of the root canal system. When surgical retreatment is required, two important questions should be considered: is root-end resection alone enough in cases where the root canal filling seems to be adequate, or is it necessary to refill the root-end in every case?

Altonen and Mattila (56) reported that teeth with root-end fillings had greater healing success than those that were not filled, provided that nonsurgical fillings were done. Lustman (57) and Rahbaran (58) also observed better success with either amalgam or SuperEBA root-end filling materials than in the nonfilled groups. The materials and surgical

techniques used in these studies were of the traditional methods. Regardless, it is clear from these studies that placing root-end fillings results in greater healing success. However, there are also some studies that report opposite findings. Rapp (59) found no significant difference in healing between teeth that were root-end filled and those that were not. Further, August (60) reported that fewer of the cases with root-end filling healed than cases with root-end resection only. Careful examination of these studies (56–60) shows many problems associated with their procedures and conclusions: Firstly, the sample size is small leading to underpowered results. Secondly, the studies were done with the old, traditional methods using amalgam as the root-end filling material. As discussed earlier, the old methods had inherent problems not only with the resection angle but also with the placement accuracy of the root-end fillings (see Resected Root Surface). Therefore, the conclusions of these studies are less relevant for modern surgical endodontics.

Because there is no conclusive study indicating the correct approach we have to decide on the basis of the canal anatomy at the root-end section. As shown in Fig. 13, one of the key steps in microsurgery is inspection of the resected root surface. This step reveals all the details and complexity of the root canal anatomy. The important question is can apicoectomy alone prevent any further leakage from the canal provided that the canal is obturated before surgery.

The Toronto Study states (21) that nonsurgical retreatment followed by root-end resection without root-end filling is an acceptable alternative treatment option on the basis of eight cases, in which seven cases were successful. This report is of some concern. Certainly, some cases will heal, especially if the size of the root-end resection is large. The reason is that the anatomic complexity decreases significantly coronal of the apical delta. Thus, well cleaned and filled canals with such extensive resection could work. However, the price is a short and weakened tooth and a comparatively large osteotomy. In addition, this approach would not work in posterior teeth where the anatomy is much more complex. More importantly, because of the relative short roots in posterior teeth, root-end resections of more than 3 mm might substantially compromise the strength and stability of the tooth. It is our clinical experience as well as that of many others, who have practiced micro-

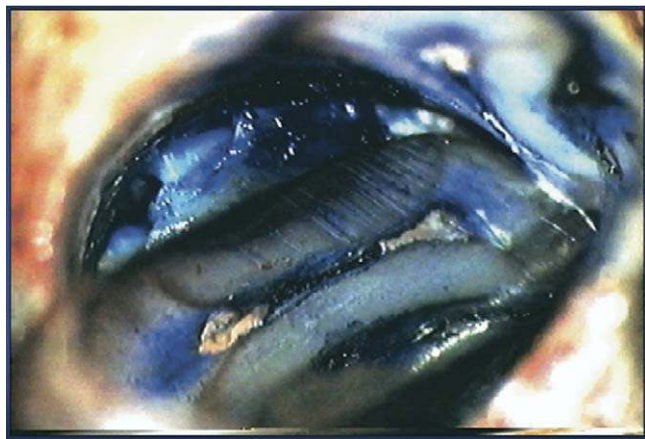


Figure 14. An example of a canal isthmus in the mesial root of the mandibular 1st molar (type V) is presented. An actual clinical example is reflected in the micromirror. (Reprinted with permission from *Color Atlas of Microsurgery in Endodontics*, by S. Kim with G. Pecora and R. Rubinstein. W.B. Saunders Co., A Harcourt Health Sciences Company, 2001.)

surgery for many years, which cases that were retreated nonsurgically with a subsequent root-end resection without root-end filling frequently failed.

The Isthmus

An isthmus is defined as a narrow strip of land connecting two larger land masses or a narrow anatomic part or passage connecting two larger structures or cavities (61). The isthmus has been called a corridor (62), a lateral connection (63), and an anastomosis (64). Weller et al. (65) described the canal isthmus as a narrow, ribbon-shaped communication between two root canals that contains pulp tissue. In many cases, a tooth with a fused root has a web-like connection between two canals and this connection is

called an isthmus (Fig. 14). An isthmus is a part of the canal system and not a separate entity. As such it must be cleaned, shaped and filled as thoroughly as other canal spaces. Surprisingly, isthmuses were not even mentioned in dental textbooks or journals until 1983, when Cambruzzi and Marshall (66) published an article on isthmuses in a Canadian dental journal. Until 1990, evidence of a treated and root-end filled isthmus is virtually absent from the dental literature.

Types

There are many isthmus types (Fig. 15). According to Hsu and Kim (60), there are five different types. Type I was defined as either two or three canals with no noticeable communication. Type II was defined as two canals that had a definite connection between the two main canals. Type III differs from the latter only in that there are three canals instead of two. Incomplete C-shapes with three canals were also included in this category. When canals extend into the isthmus area, this was named type IV. Type V was recognized as a true connection or corridor throughout the section.

Incidence

The isthmus is most frequently observed between two root canals within one root. Thus, the majority of posterior teeth contain an isthmus. At the 3-mm level from the original apex, 90% of the mesiobuccal roots of maxillary first molars have an isthmus, 30% of the maxillary and mandibular premolars, and over 80% of the mesial roots of the mandibular first molars have one (1, 55). This high incidence of isthmuses in premolars and molars is an important consideration when performing apical surgery. This is one of the reasons why apicoectomy alone, without root-end preparation and/or root-end filling, especially in molar teeth, usually fails.

Identification

In posterior teeth, root apices are usually round, but after a 3-mm resection, roots are peanut shell shaped and usually show evidence of

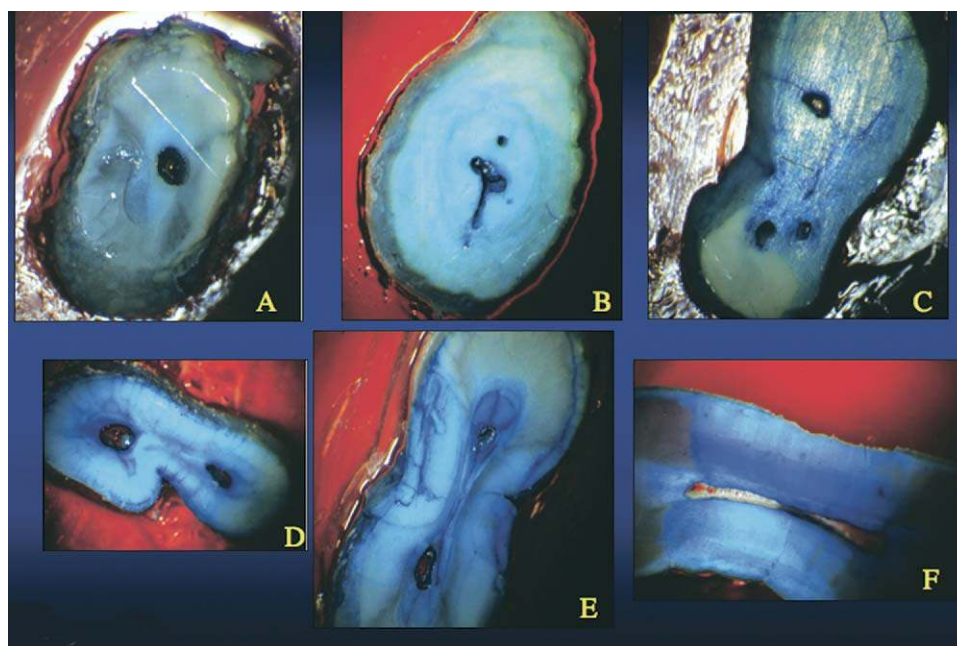


Figure 15. Inspection of resected root surfaces of extracted teeth reveals many different types and shapes of isthmi. (A) Shows an infrequently seen round apex. (B) Shows a modified type I. (C) has several apices with a type I isthmus. (D) Is a type II isthmus, (E) is a type IV, and (F) a type V. The classification is based on Hsu and Kim (55). The majority of molar isthmi are types IV and V.

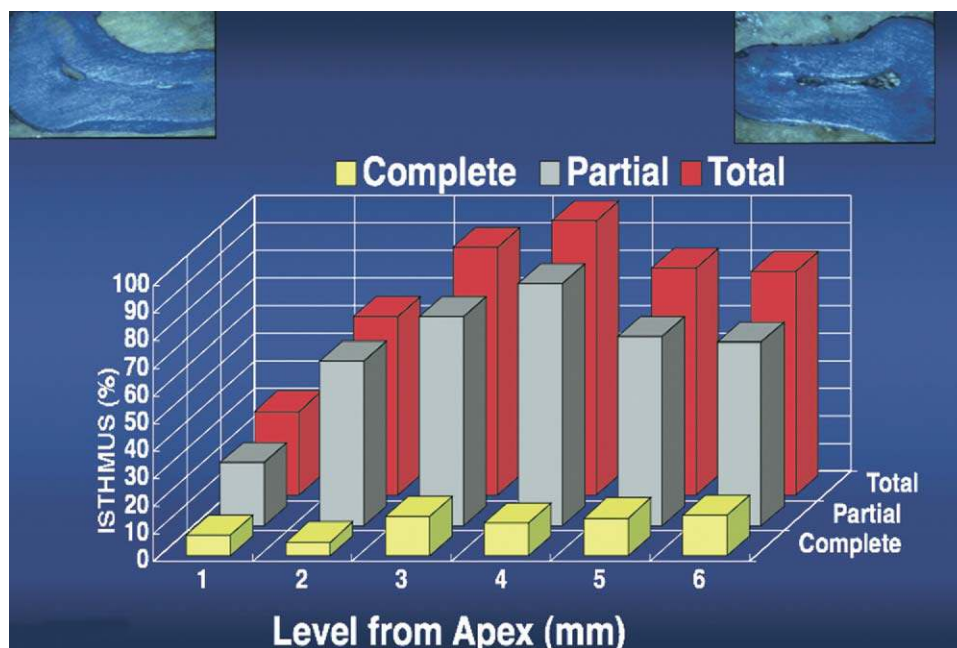


Figure 16. A great number of complete (type V) and incomplete (type IV) isthmi are located between 3 and 4 mm from the apices of the mesiobuccal roots of maxillary first molars. (Reprinted with permission from *Color Atlas of Microsurgery in Endodontics*, by S. Kim with G. Pecora and R. Rubinstein. W.B. Saunders Co., A Harcourt Health Sciences Company, 2001.)

an isthmus. Methylene blue staining is the most effective means to identify anatomical details, such as isthmuses.

Management

Weller et al. (65) distinguished two types of isthmuses: the complete and incomplete isthmus (Fig. 16). The management of a complete isthmus is relatively easy with the use of appropriate ultrasonic instruments. However, the incomplete isthmus requires a careful approach with thin ultrasonic tips trougling along the incomplete isthmus (67). It is essential that the entire canal system, canal(s), and isthmus, be prepared to a depth of 3 mm.

Clinical Significance

A survey of numerous failed cases done with traditional methods clearly shows that the main cause of failure in the mesial roots of molars is mismanagement or failure to manage the isthmus (1, 2, 55). Frequently, the root-end filling is placed only into one canal, while bacteria and toxins are still present in the isthmus as well as the second canal. Thus, the reported high success rate with apicoectomy alone, as reported in the Toronto study (21) are likely to only occur in teeth without isthmuses. This appears unusual because, as mentioned previously, 80 to 90% of molar roots have isthmuses (1, 55, 65). Thus the suggestion that nonsurgical retreatment followed by an apicoectomy alone would solve molar surgical problems is ill advised. It is essential to identify and manage the isthmus when treating multi-rooted posterior teeth.

To summarize, the ready identification of isthmuses under the microscope, efficient and precise ultrasonic instrumentation and finally, filling with the best biocompatible root-end filling material, is in our opinion, the best and most successful microsurgical approach (3, 19). Presented in Fig. 17 is a typical case that failed because of not treating the isthmus, and healed subsequent to surgical management. It is our observation that the main cause of failure in mesial roots of mandibular molars done with the bur and amalgam is the inability to treat the isthmus, thus causing the root-end filling to float at the buccal aspect of the canal while the lingual leaks.

Ultrasonic Root-end Preparation

The conventional root-end cavity preparation technique using rotary burs in a micro-handpiece poses several problems for the surgeon (1, 4, 5, 53, 67, 68):

1. Access to the root-end is difficult, especially with limited working space
2. There is a high risk of a perforation of the lingual root-end or cavity preparation, when it does not follow the original canal path
3. There is insufficient depth and retention of the root-end filling material
4. The root-end resection procedure exposes dentinal tubules
5. Necrotic isthmus tissue cannot be removed

These clinical dilemmas were never questioned in the past, rather it was an accepted fact, because the standard tools at that time were too large for the surgical site and the true complexity of the root-end anatomy was not known. Many articles and textbooks of that time contain extensive descriptions how to retro-prepare with burs. Figure 18 shows a generation change in root-end preparation tools from burs to micro-burs to ultrasonic tips.

The aim of the root-end preparation is to remove the intracanal filling material and irritants and to create a cavity that can be properly filled. The ideal root-end preparation can be defined as a class 1 cavity at least 3 mm into root dentine, with walls parallel to and coincident with the anatomic outline of the root canal space (67).

Richman first introduced the use of ultrasonics in endodontics in 1957, using a modified ultrasonic periodontal chisel scaler for root canal debridement and apicoectomy (69). Eventually Carr (4) introduced retrotips designed specifically for root-end cavity preparation during endodontic surgery. Several authors later reported superior operator control, decreased risk of perforation by increased ability to stay centered in the canal when using the ultrasonic retrotips as compared to the microhandpiece (70).

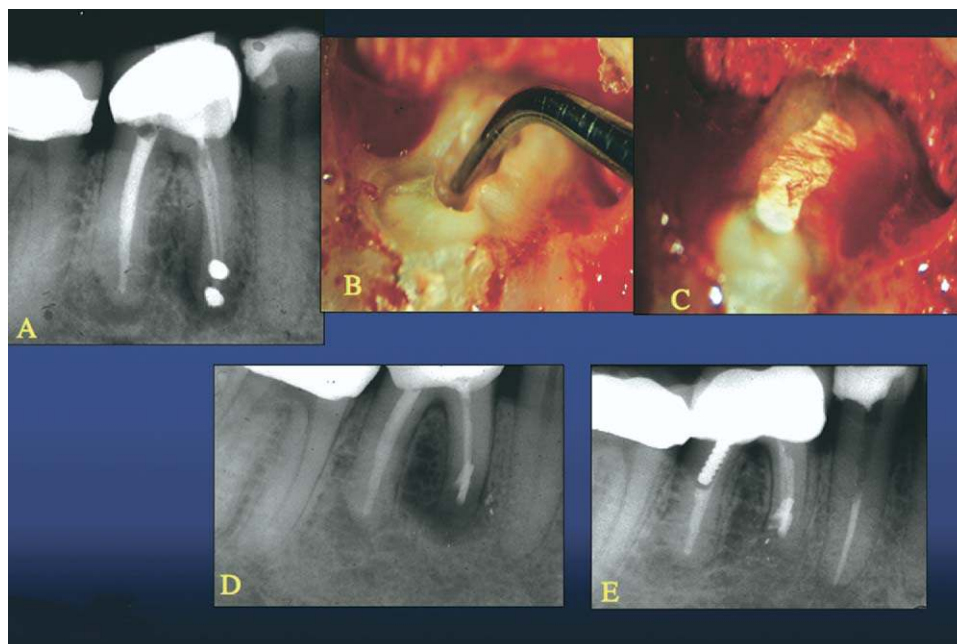


Figure 17. Failed traditional surgical case (A). High magnification of root-end preparation with an isthmus (B). Obturation of root-end in C with SuperEBA shown at 16 \times magnification. Note elongated root-end filling covering two apices and connecting the isthmus (C). Radiograph immediately after surgery (D) and 1 yr postsurgery (E), showing complete healing. (Reprinted with permission from Color Atlas of Microsurgery in Endodontics, by S. Kim with G. Pecora and R. Rubinstein. W.B. Saunders Co., A Harcourt Health Sciences Company, 2001.)

Wuchenich et al. (71) compared the root-end cavities prepared with conventional handpieces or ultrasonic tips in cadavers in a SEM study. They found that ultrasonics tips also made cleaner and deeper root-end cavity preparations, aiding retention of the root-end filling material and disinfection by removing infected dentin.

Despite the advantages of using ultrasonics, Saunders et al. (72), while experimentally using the ENAC system (smooth stainless steel tips) on extracted teeth reported crack formation in the walls of the cavity, which may increase the chance of apical leakage. However, Layton et al. (73) suggested that the cracks might be a result of the exper-

iment design, because the previous study used demineralized and dehydrated the teeth, which may have predisposed towards crack formation.

Layton (73) used smooth stainless steel tips also on extracted teeth to evaluate if the cracks were created during the root resection procedure or after the root-end preparation with ultrasonic tips. The results of his study concurred with Saunders that ultrasonic preparations do lead to increased number of cracks in the walls of the preparations. He observed more cracks on the resected surfaces after root-end cavity preparation than after root resection only.

Layton also observed a higher prevalence of microfractures when he used the tips at higher power settings. Walington et al. (74) have suggested using low to moderate intensity for 2 min to minimize the risk of root dentine microfractures.

Because both the Saunders and Layton studies were performed on extracted teeth (72, 73), in which microfractures could possibly be attributed to tooth desiccation, brittleness, and absence of periradicular tissues. Min et al. (75) suggested the use of cadavers for the results to be more clinically relevant. A study by Gray et al. (76) on cadavers reported that the ultrasonic tips did not cause a greater than average number of cracks. The number of cracks observed in his study seemed insignificant. It was suggested that the periodontal ligament might dissipate stresses and thereby prevent cracking. In another experiment on cadavers (77) an impression of the resected root-end was made with polyvinylsiloxane and was examined under SEM; also to find no significant cracks. An in vivo study (78) on 25 patients undergoing endodontic surgery using the polyvinylsiloxane impression technique found only one root-end showing evidence of a crack.

Most ultrasonic instruments used in prior studies were smooth, stainless steel tips. Diamond coated ultrasonic surgical instruments have been introduced in recent years in hopes of minimizing dentinal fractures through their ability to abrade dentine more quickly, thus minimizing the time that the instrument is in contact with the root-end

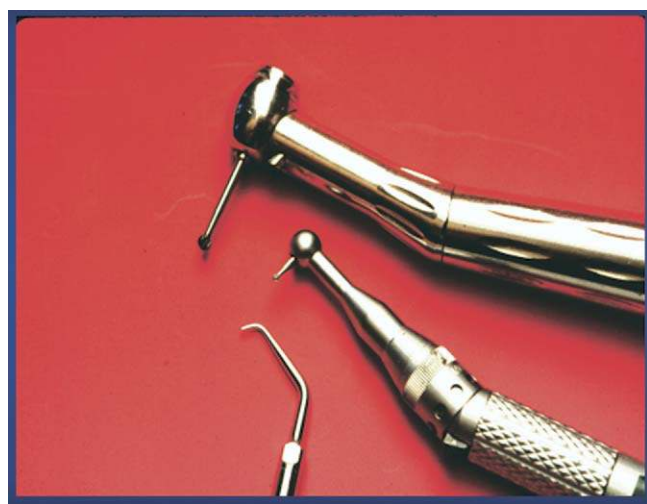


Figure 18. Traditional root-end preparation instruments with burs (top and center) and modern ultrasonic instrument (bottom). (Reprinted with permission from Color Atlas of Microsurgery in Endodontics, by S. Kim with G. Pecora and R. Rubinstein. W.B. Saunders Co., A Harcourt Health Sciences Company, 2001.)

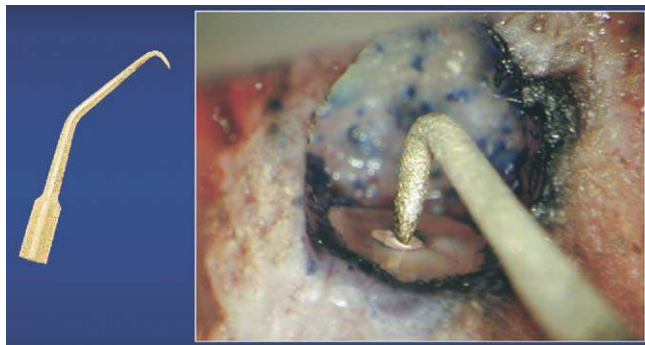


Figure 19. Microsurgical root-end preparation of a maxillary canine with a KiS #1 ultrasonic diamond coated tip (16 \times).

(79). Various studies (80-82) comparing the diamond-coated tips with stainless steel tips have concluded that neither tip produced a significant number of microcracks. However, the diamond coated tips cut much faster, and left a more grooved or rough cavosurface. It is not considered a clinical problem, instead it may be an advantage.

The most recent developments are the Zirconium coated and diamond coated tips e.g. KiS tips (1) (Fig. 19). In regard to diamond coated tips, diamonds adhere to the surface of the tips resulting in a slightly larger diameter, whereas Zirconium nitride is processed into the metal making the tip narrower. A drawback of the Zirconium coated tip versus the rough diamond coated tip is its ineffectiveness in removing gutta-percha. This is mainly because of the surface smoothness. Navarre et al. (79) compared the KiS tips with the stainless steel tips and concluded that KiS tips remove gutta-percha from axial walls and prepare ideal root-end preps faster than the stainless CT-5 tips. In summary, ultrasonic tips have fundamentally changed apical surgery. The histological section in Fig. 20 provides a graphical demonstration of the advantage of using an ultrasonic instrument over a bur. Ultrasonic instruments are still being improved upon, and new, different types of coating would make a difference in cutting efficiency while minimizing microfractures. The search for the most efficient ultrasonic instruments will continue, and their application together with the microscope and microinstruments will make endodontic microsurgery even more effective.

Root-End Filling Materials: Is MTA the Best Material?

An ultrasonically prepared 3 mm class I cavity preparation must be filled with a material that guarantees a hermetic seal.

In this section, the authors will not elaborate on the many different kinds of root-end filling materials since this matter has been addressed many times in this journal in recent years. Especially, a review article by Torabinejad and Pitt Ford (83) provides an excellent review. There are several root-end filling materials now used in conjunction with apical surgery. Amalgam has been and still is to some extent a widely used material. However, in the past decade amalgam has slowly given way to ZOE containing materials, such as IRM and SuperEBA as a favorite root-end filling materials. Numerous studies show that these ZOE containing materials are superior to amalgam in terms of sealability and biocompatibility (84-87). More recently, mineral trioxide aggregate (MTA) has been suggested as having many of the properties of the ideal root-end filling material.

Although the exact composition of MTA is proprietary, the main ingredients are tricalcium silicate (Ca_3Si), tricalcium aluminate (Ca_3Al), and tricalcium oxide (Ca_3O_2). Because of its superior sealing ability and biocompatibility over conventional filling materials, MTA is gaining popularity among endodontists (88-91). In vivo studies have

shown that MTA has the capacity to induce bone, dentin and cementum formation in vivo (92-94). In comparison to amalgam and SuperEBA as root-end filling materials, MTA consistently resulted in regeneration of periapical tissues including periodontal ligament and cementum (Figs. 21, 22, and 23). Although the precise mechanisms of MTAs mineralized tissue-inducing activity remain unknown, it is likely that MTA will have a wider clinical application beyond the dental pulp and root canal therapy. Preliminary results of a study assessing inductive properties of MTA on bone and dentin (95) show that the cell cultures using animal and human osteoblasts and dentinoblasts grown on MTA grew faster and better than cells without MTA (Figs. 24 and 25). Based on the findings from this study, we suggest that MTA stimulates osteo- and odontogenic cell proliferation via intra- and extracellular Ca^{2+} and Erk dependent pathways and that MTA promotes cell survival via the PI3K/Akt signaling pathway.

It may be premature to state that MTA is the ideal root-end filling material, however, results of experiments performed using animal models and in vitro laboratory methods, along with the modern cellular and molecular methods, provide unequivocal evidence that MTA has greater healing induction potential and is more biocompatible than any other root-end filling material available to date (89, 92, 94, 95). Some clinical experimental results also agree with the scientific results (91). However, the use of MTA alone does not guarantee clinical success. MTA cannot overcome deficiencies in techniques that are inherent in the traditional apical preparation. Clinical studies show that healing of cases sealed with MTA is much better, but not significantly different than IRM, provided that modern microsurgical or, at least, ultrasonic preparation techniques were employed (19). Good surgical techniques and protocol are as important for better results as are the materials.

Given the development of contemporary microsurgical techniques and tissue inductive root-end filling materials, the continued use of traditional surgical techniques with amalgam fillings has been questioned (19).

Root-End Filling Material: Gray MTA (gMTA) and White MTA (wMTA)

Most of the research findings (88-95) on MTA have been based on the gMTA. Recently, gMTA has been replaced by wMTA (ProRoot by Densply) for reasons that are not clear. There are only few studies so far that have made a direct comparison between the two types of MTA in their constituents, biocompatibility, sealing ability, and regeneration of the original tissues.

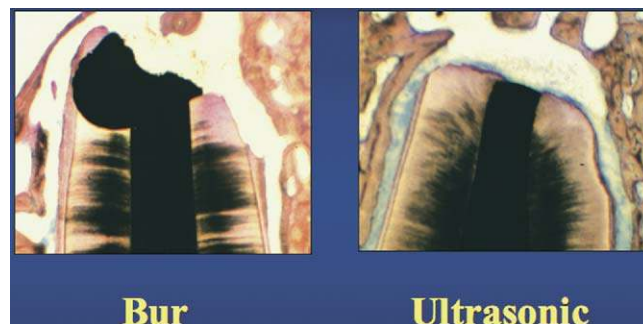

Figure 20. Histological images of root-end preparations in dogteeth by a bur (left) and ultrasonic tip (right). The bur preparation nearly resulted in a lingual perforation, while the ultrasonic preparation preserved the integrity of the root apex because of the co-axial preparation within the root canal.

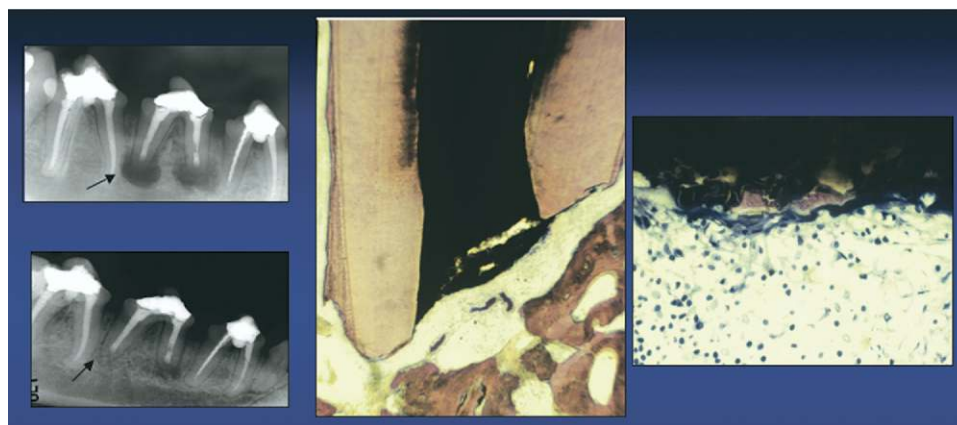


Figure 21. MTA root-end filled apex (mesial root) of a dog tooth showed complete healing at 5 months postoperative (left X-rays). The histological pictures show new bone formation at the surgical site (center) and the absence of inflammatory cells (right), suggesting a complete resolution of the pathology. The distal apex, showing incomplete healing, is filled with SuperEBA (left X-rays).

Analysis of the chemical constituents of both types of MTA has shown that they are almost identical in their composition except for the absence of iron compound in the wMTA (96, 97).

Biocompatibility of gMTA and wMTA was compared by evaluating cell attachment and osteogenic behavior. Perez et al. (98) demonstrated that there was no initial difference in the cell attachment, but the cells on wMTA did not survive as long as on the gMTA. On the contrary, Camilleri et al. (99) directly compared the biocompatibility using a cell culture method and concluded that the samples of two commercial forms of MTA showed good biocompatibility. Studies on wMTA have concluded that WMTA is biocompatible and has the potential to induce osteogenic behavior, although in some cases no direct comparison was made with gMTA, (100, 104–106).

The sealing ability was compared using the bacterial leakage test on perforation repair sites. Ferris et al. (101) tested the ability of both types of MTA to seal off the perforation site and showed that there was no significant difference between the two materials. Also a bacterial leak-

age test through the root filling with gMTA and wMTA showed that there was no statistically significant difference between them although the gMTA fillings had leaked in fewer cases (102).

The tissue response was compared by subcutaneous implantation of dentin tubes filled with gMTA (103) and wMTA (104) and subsequent histological examination showed that there was no obvious observable difference between the two. They both showed similarities in the bridge formation and tissue changes, indicating that the mechanisms of action of the wMTA and gMTA are similar.

Faraco et al. tested pulp capping with gMTA (105) and wMTA (106) on dog dental pulps and showed that both resulted in a healing process with complete dentin bridge formation in all the samples. Parirokh et al. (106) also showed that there is no difference between the two. They both formed hard tissue barriers and caused minimal or no tissue inflammation.

Although additional studies are needed to test wMTA, the published findings so far indicate that wMTA is comparable to gMTA.

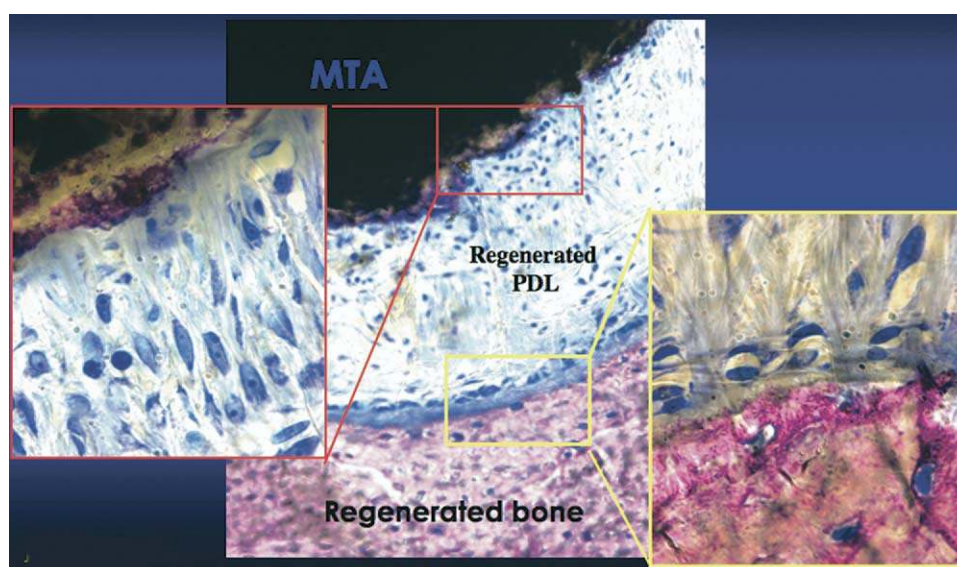


Figure 22. Histological sections of dog teeth root-end filled with MTA show remarkable bone regeneration (yellow frame). At large magnification (right) numerous PDL-like projections are seen from the bone toward the MTA filling. From the MTA side, numerous PDL-like projections with fibroblasts forming a columnar pattern are seen (left). The regenerated PDL has the same width of ca 0.38 mm, as a normal PDL.

Tissue response in animal study: Results

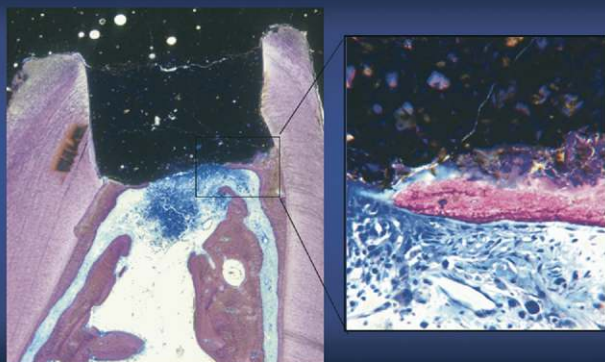


Figure 23. The same preparation as in Fig. 22 shows newly generated cementum-like projections covering the MTA. At large magnification (right) a growing cementum-like entity, closely linked to the MTA, can be seen. With time the cementum-like projection will close over the MTA, forming a biologically barrier.

Surgical Sequelae and Complications: The Mental Foramen and Sinus

Many clinicians avoid doing surgery on posterior teeth because of possible paresthesia in the mandibular arch and sinus infringement in the maxillary arch. These anatomical entities should not be a deterrent for surgery as there are well-tested techniques to manage them.

Mental Foramen Management

Generally, the mental foramen is located below and between the apices of the second premolar and the mesiobuccal root of the first molar. More precisely, its most common location is inferior to the crown of the second premolar (62.7%) (107), and it is always larger

Cellular response in cell culture: Results

Cell proliferation assay (MTT assay)

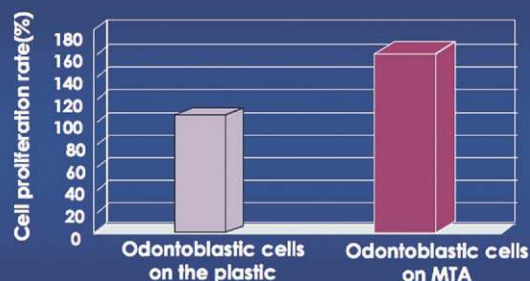


Figure 25. MDPC23 odontoblasts grown on MTA proliferated significantly faster (about 60%) than those in the control. This test was done using the MTT assay.

than it appears on the radiograph (108). A thorough knowledge of the anatomy of the region, as well as taking angled radiographs are essential. It is also essential that the vertical releasing incision is long enough to expose the mental foramen after a careful dissection. Once the foramen is identified, a retractor is placed to protect the foramen and under the microscope, a horizontal groove is cut just above the foramen (Fig. 8). Although injuring the nerve is extremely rare, transient paresthesia may occur even if the surgical site is far from the nerve. Inflammatory swelling of the manipulated tissues may cause impingement on the mandibular nerve, resulting in transient ipsilateral paresthesia. Normal sensation generally returns within few weeks. Thus, performing surgery on mandibular posterior teeth should not be of great concern, provided that proper preparations are made. At our institution, there has been no case of permanent paresthesia in more than 450 mandibular molar cases since 1992, when microsurgery was first taught and performed by endodontic graduate students.

Cellular response in cell culture: Results

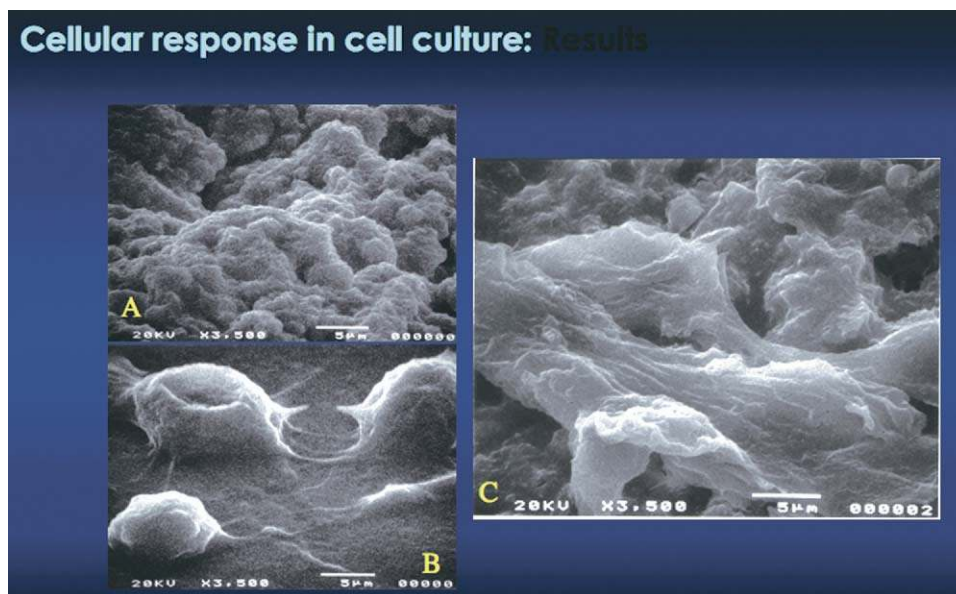


Figure 24. Scanning electron microscope images of gray MTA (A), MDPC23 mouse odontoblast cells (B), and cells grown on MTA (C). MDPC23 cells without MTA appear normal, of a round shape and attached to the plate surface (B). MDPC23 cells grown on gray MTA have a flat appearance, showing robust growth, suggesting that MTA may stimulate cell growth. Electron dispersion analysis was used to differentiate cells from MTA by comparing the Ca^{2+} content.

TABLE 5. Radiographic checkup of resected teeth in the maxillary posterior region ($n = 146$) 6–42 months postoperatively

Healing	Maxillary Sinus Exposed	Maxillary Sinus Not Exposed
Complete	33 (89.2%)	93 (85.3%)
Incomplete	3 (8.1%)	8 (7.3%)
None	1 (2.7%)	8 (7.3%)
Total	37 (100%)	109 (100%)

Sinus Management

The sinus can be easily perforated when dealing with maxillary posterior teeth. Sometimes it can be avoided with the careful execution of the surgery. Sometimes it cannot be avoided, when the root-ends extend into the sinus. When the sinus is perforated, the most important step is to prevent any solid particles, such as cotton pellets, root-end filling materials, and so forth, from entering the sinus cavity. The sinus is capable of flushing away large amount of fluid but not solid materials. Thus, flushing of the sinus with saline poses no problem. If the size of the sinus perforation is very small, a cotton pellet tied securely to a suture can be used as a barrier (1). If the perforation is large, however, a thin iodine gauze strip can be inserted into the sinus, leaving the end outside for ready retrieval, before continuing the surgery. Once the surgery is completed, the cotton pellet or the iodine strip must be removed completely. The postoperative preparations should include a prescription of an antibiotic, such as ciprofloxacin or amoxycillin for 1 wk, postoperative instructions to sleep with the head slightly elevated, to avoid nose blowing and to expect possible nose bleeds. When these precautions are

taken, there are usually no problems with a sinus perforation. A comparison study done by Prof. G. Watzek and his colleagues at the University of Vienna, Austria showed that there is no difference in terms of complete healing (89.2% vs. 85.3%) of cases with sinus perforation and with an intact sinus (Table 5).

Classification of Endodontic Microsurgical Cases

Because the outcome of endodontic surgery depends on the pre-existing condition of the tooth, it is important to know that the probability of success depends on the given situation. Therefore, we propose the following classification (Figs. 26 and 27):

Class A represents the absence of a periapical lesion, no mobility and normal pocket depth, but unresolved symptoms after non-surgical approaches have been exhausted. Clinical symptoms are the only reason for the surgery.

Class B represents the presence of a small periapical lesion together with clinical symptoms. The tooth has normal periodontal probing depth and no mobility. The teeth in this class are ideal candidates for microsurgery.

Class C teeth have a large periapical lesion progressing coronally but without periodontal pocket and mobility.

Class D are clinically similar to those in class C, but have deep periodontal pockets.

Class E teeth have a deep periapical lesion with an endodontic-periodontal communication to the apex but no obvious fracture.

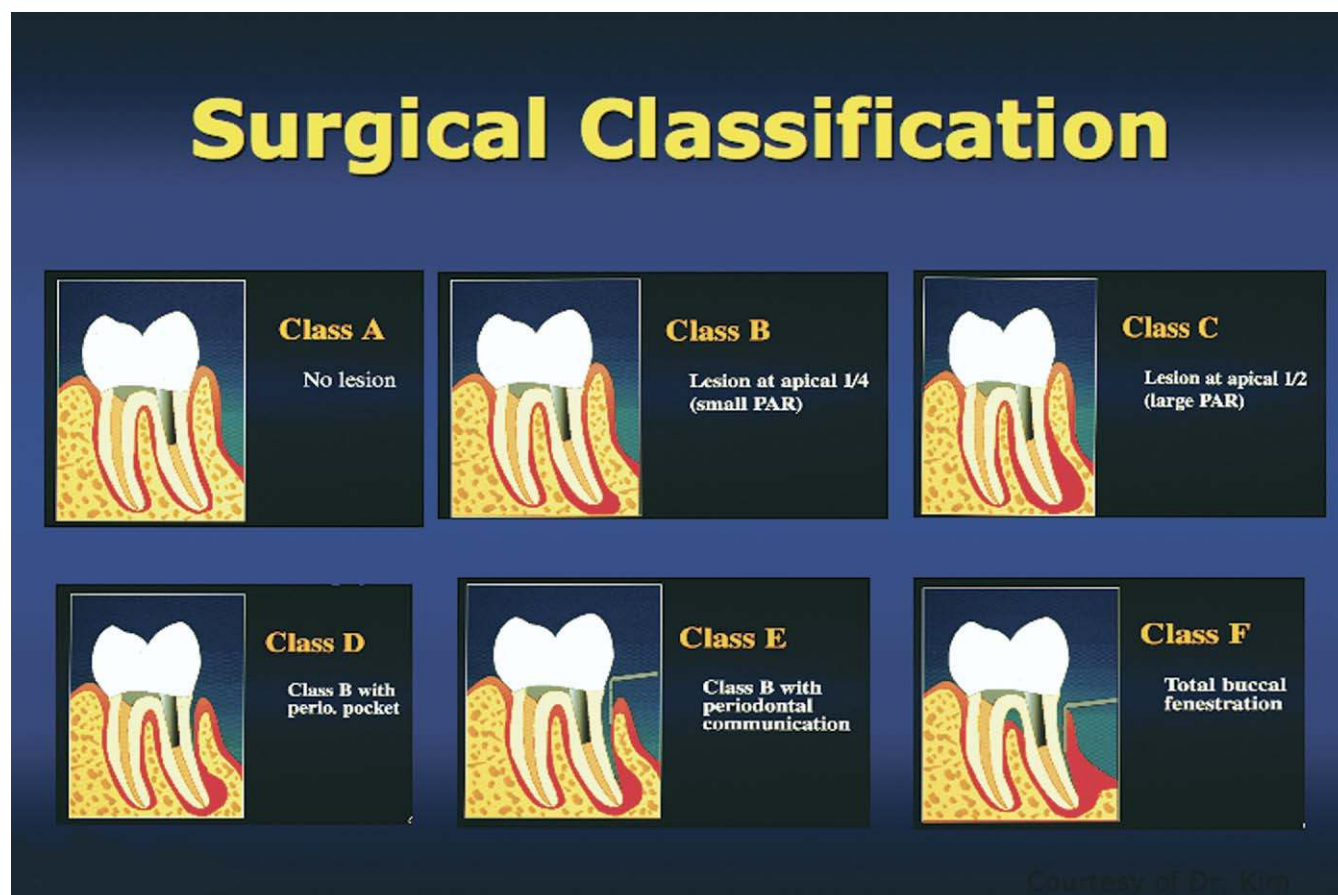

Figure 26. Classification of endodontic microsurgical cases.

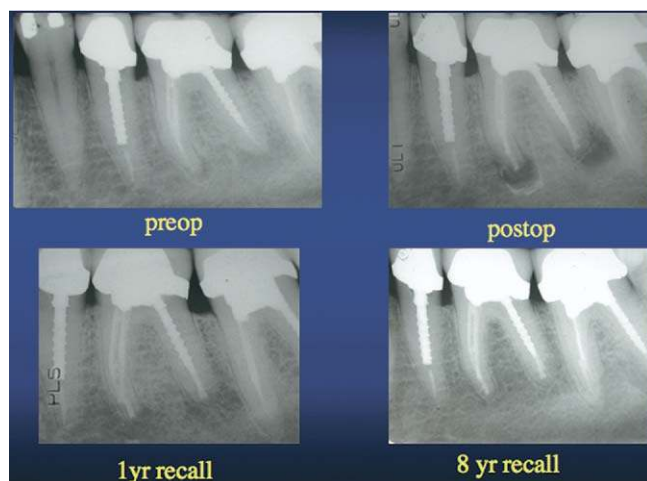

Figure 27. A long-term 8 yr follow-up of a #19 using microsurgical techniques and gray MTA as root-end filling material. Complete radiographical and clinical resolution of the pathology with total absence of symptoms.

Class F represents a tooth with an apical lesion and complete denudement of the buccal plate but no mobility.

Classes A, B, and C represent no significant surgical treatment problems, and the conditions do not adversely affect treatment outcomes. For instance, in the study by Rubinstein and Kim (3), cases in these categories had 96.8% healing success after 1 yr. However, classes D, E, and F present serious difficulties. Although these cases are in the endodontic domain, proper and successful treatment requires not only endodontic microsurgical techniques but also concurrent bone grafting and membrane barrier techniques. These are true challenges even for the endodontic surgeon who has excellent microsurgical skills, because the causes of the problem are of combined endodontic and nonendodontic origins. The predictable and successful management of these cases is the true challenge.

Postoperative Reactions: Pain and Swelling

Pain and swelling are common postoperative reactions after surgical endodontic treatment. It is a common impression with the traditional techniques that apical surgery is invasive and causes moderate to severe pain and swelling and requires analgesics 1 day after the surgery for a significant number of patients. Further, 23% of these patients are absent from work because of swelling and pain (109, 110).

At the University of Pennsylvania, we examined and monitored postoperative pain and swelling in more than 150 patients undergoing microsurgical endodontics. The patients were preloaded with 800-mg ibuprofen and continued on this drug for 2 days four times per day. The preliminary results of this study clearly demonstrate that pain and swelling were minimal. Occasionally, patients report some swelling but only minor pain. Similar results were obtained by Tsesis et al. (111). The difference between the Tsesis and our study is that Tsesis used small doses (8 mg) of a corticosteroid (Dexamethasone) preoperatively and two single doses (4 mg) 1 and 2 days postoperatively. Pain and swelling were evaluated using the Verbal Numerical Rating Scale (VNRS) ranging from 1 (no pain) to 10 (intolerable pain). The degree of swelling was expressed as none, mild, moderate, and severe. Of the 82 patients, 64.7% did not report any swelling 1-day postsurgery. Only one patient reported maximum pain of VNRS 4 and close to 80% of the patients reported VNRS 1, indicating no pain. These results may be attributed to the use of ibuprofen or dexamethasone, however, it may also be the microsurgical procedures that are largely responsible for the mild to no

postoperative reactions. In either case, if a small dose of ibuprofen or dexamethasone provides postoperative comfort, it would be beneficial to incorporate their use into the surgical protocol.

Lasers

Various laser systems were tried in endodontic surgery with limited benefits (112, 113). The CO₂ or Nd:Yag lasers are not suitable because they do not cut bone and dentin effectively (112–114).

Er:Yag lasers have also been used for apical surgery (115–117). The authors claim that the Er:YAG laser causes no vibration and discomfort while cutting bone and dentin and less damage to soft tissues and bone, as well as less contamination of surgical sites. Outcomes of a critical prospective randomized clinical trial has not yet been reported. Clinical impressions from those who used the Er:YAG laser system for apical surgery are mixed: (a) The Er:YAG system can be used for osteotomies and root resections but the procedure requires more time than a preparation with burs. (b) While the Er:YAG laser may promote faster healing and more comfortable postoperative results according to the manufacturer, the root-end preparation cannot be done with the laser and the procedure still requires microsurgical ultrasonic preparation and filling. There are no convincing clinical and/or animal study results demonstrating significant advantages of using the laser over the microsurgical techniques. Under these circumstances, we should be cautious about changing our current surgical approach. If we incorporate this laser system into our surgical armamentarium, we must be sure that it has a significant and distinct advantage over the existing techniques. As of now, there are no articles published in peer-reviewed journals that demonstrate this advantage. Research using randomized clinical trial methods with the laser system is urgently needed to provide information as to whether the currently available laser system, Biolase, is of significant benefit in endodontic surgery.

Treatment Outcome of Endodontic Microsurgery

There is an abundance of success and failure studies and review articles in endodontic surgery (3, 19–21, 82, 118–125). Does the microsurgical approach provide better treatment results than the traditional techniques? Although relatively few surgical outcome studies use experimental designs with the higher levels of evidence-based research [e.g. randomized clinical trial (RCT)], many of the published studies are cohort studies or case series and, clearly, future studies should be designed to satisfy the Cohort and RCT requirements. Until then, we have to make our clinical decisions on the basis of current knowledge. It would be ideal to conduct a RCT using a group of traditional cases and another group of microsurgical cases. However, as stated earlier, it would be unethical to conduct such a study, knowing that the failure rate of traditional periapical surgery is very high. This sentiment is also echoed by Chong and Pitt Ford (19) who performed an important RCT study in microsurgery. As pointed out in their work, conducting a clinically reliable prospective study is extremely difficult, because outcome depends on participant cooperation, over which the investigators have limited control.

Thus, in this section we will mostly discuss the success of microsurgical techniques and compare them with the traditional techniques using available and relevant published articles. Success or healing of surgical cases must be differentiated by pre- and postmicrosurgery periods. Table 6 contains data of recent studies.

Traditional Methods

The clinical success of traditional surgery, based on the absence of symptoms and on radiographical healing, ranged from 44 to 90% for a certain period of time (126–130). Such disparity could be explained by

TABLE 6. A Summary of Selected Microsurgical Studies

Author/Year	Sample Size	Teeth Art/ PM/M	Follow-up Period	Study Design	Inclusion/ Exclusion Criteria	Magnification	Retroprep	Retrofill Material	Success Rate
Wang et al. (2004)	155 teeth	42A/58P	4–8 yrs	prospective	No	No	Ultrasonic	Amalgam, Composite Super EBA, IRM or MTA	74%
Maddalone and Gagliani (2003)	120 teeth	62/30/28	3 yrs	prospective	No	Loupes	Ultrasonic	Super EBA	92.40%
Chong et al. (2003)	108 teeth		1 vs 2 yrs	prospective	Yes	Microscope	Ultrasonic	IRM vs. MTA	87% IRM 92% MTA
Schwartz - Arad et al. (2003)	122 teeth		11.2 months mean	retrospective	No	No	Bur	Amalgam & IRM	44.30%
Von Arx et al. (2003)	39 roots in 25 molars	25M	1 yr	prospective	Yes	No	Ultrasonic	SuperEBA	88%
Wessen and Gale (2003)	1,007 teeth	all molars	5 yrs	prospective	No	No	Bur	Amalgam	57%
Rubenstein and Kim (2002)	59 roots	19/17/23	5–7 yrs	prospective	Yes	Microscope	Ultrasonic	SuperEBA	91.50%
Rahbraran et al. (2001)	176 teeth	129/33/14	4 yrs	retrospective	No	No	Ultrasonic & Bur	SuperEBA & Amalgam	37.4% Endo 19.4% Oral Surg
Rud et al (2001)	834 roots in 520 molars	520M	1 yr	retrospective	No	Microscope	N/A	Dentine bonded resin	92%
Zuolo et al. (2000)	114 teeth	39/24/39	1–4 yrs	prospective	Yes	No	Ultrasonic	IRM	91.20%
Testori et al. (1999)	302 roots in 181 teeth	65/126	4.6 yrs mean	retrospective	No	No	Ultrasonic vs Bur	SuperEBA vs Amalgam	68% Bur 85% ultrasonic
Rubenstein and Kim (1999)	91 roots	30/30/31	1 yr	prospective	Yes	Microscope	Ultrasonic	SuperEBA	96.80%
Halse et al (1991)	474 teeth		1 yrs	retrospective	No	No	Bur	Amalgam	68.70%

differences in the study designs, sample sizes, the recall period, and the lack of clear and consistent evaluation criteria for clinical and radiographic parameters of healing. Other factors that can affect the prognosis in periradicular surgery include patient systemic conditions, amount, and location of bone loss, the quality of any previous root canal treatment or retreatment, coronal restoration, occlusal microleakage, surgical materials and techniques, and the surgeon's skills (128–130). Considering these factors, a survey of the literature reveals a distinct pattern in the treatment outcome by different techniques and methods.

A classic study by Frank et al. (130) reported that 42.3% cases, that had been documented successful initially, failed after 11 to 15 yr. From this result the authors questioned the use of amalgam and traditional surgical methods using a handpiece and burs. The effects of several prognostic factors in surgery outcomes were examined by evaluating previous studies. Despite many unexplainable results, one correlation was obvious: teeth with radiolucencies failed in significantly greater numbers (129). Molven et al. (128) found that the efficacy of the apical seal was the most important factor for successful apicoectomy. This would explain the low success obtained with the traditional surgical methods as described in this review.

Comparison of Ultrasonic versus Traditional Method

Bader and Lejeune (131), Rahbaran et al. (126), and Testori et al. (20) compared the healing of these two different periapical techniques retrospectively, the traditional technique with rotary instruments, and the modern technique using ultrasonic tips. The Bader and Lejeune's study (131) was a prospective RCT study: 80 teeth were assigned to four groups with two groups treated with traditional techniques and the other two groups with ultrasonic root-end preparation. IRM was the sole root-end filling material. The ultrasonic technique healing success of 95% was compared with 65% success with the traditional techniques.

Testori et al. (20) reported that of 68% of the teeth treated with the traditional techniques healed in 4.5 yr versus 85% with the ultrasonic technique. This was a retrospective study and there were no stated inclusion or exclusion criteria. Both authors found a difference of 17% between the two techniques. It is noteworthy that ultrasonic instruments versus burs alone resulted in such a significant difference. How much of this difference was a result of the material used is not clear, as roots in the ultrasonic group were root-end filled with SuperEBA, while amalgam was used in the other group. The results with eugenol-based materials in the above two studies are comparable with results reported by Dorn and Gartner (132). Many authors (3, 20, 120, 132) since then have given varied results with eugenol-based materials like IRM and SuperEBA and the use of ultrasonic tips. It is apparent from these results that ultrasonic root-end preparation provides a significantly higher treatment success, perhaps in the range of 17 to 30%, than the traditional bur techniques.

Ultrasonic Without Microscope

Outcome studies need to be cautiously compared as there are too many variables in treatment protocol and methodology (3). To be meaningful, any success/failure study has to be well controlled and specific as to what it intends to study. A prospective approach is essential for a better understanding of the prognosis of surgical endodontics. This will help in well-defined case selection and in the application of reproducible, evidence-based, contemporary surgical techniques, and operator's skills (82). There are four prospective studies recently published. This, by no means, is meant as a comparison but as an acknowledgment of a common theme found among them (3, 82, 118, 120). Von Arx et al. (120) reported 88% success after 1-yr follow-up of 24 molars with 39 roots using ultrasonics and SuperEBA. He regularly found isthmuses in molars and managed them despite not using the microscope. His case

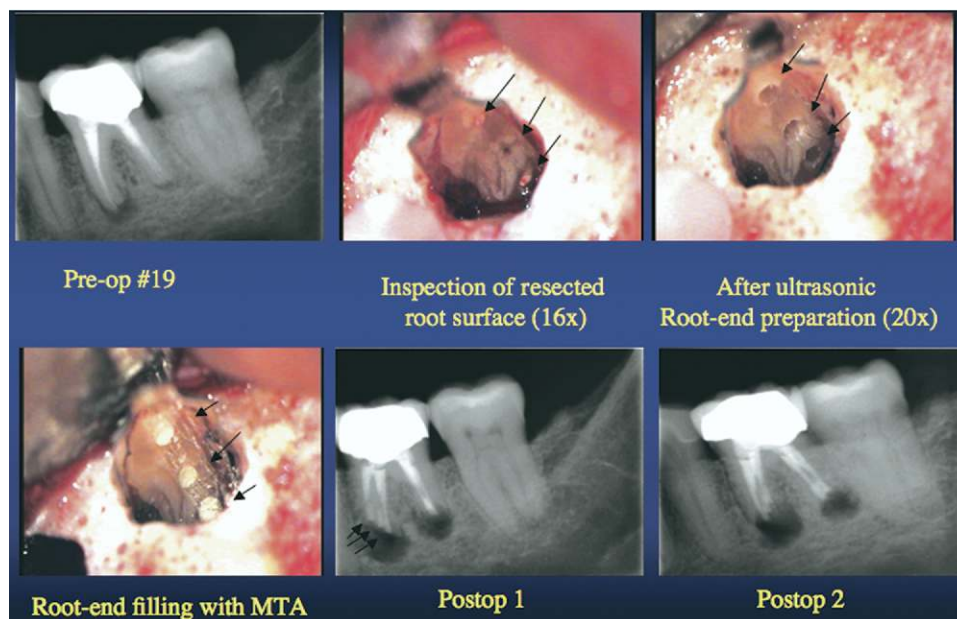


Figure 28. An example of unusual apical anatomy of a #19. The tooth was retreated twice with persistent clinical and radiographical problems. Inspection of the resected root surfaces at high magnification revealed three separate canals in the mesial root and an isthmus in the distal root. The case was performed under strict microsurgical protocol with MTA as the root-end filling material. (Courtesy Dr. G. Guess, La Jolla, CA.)

selection criterion was exclusion of advanced periodontitis. The details of the inclusion criteria are lacking in this case, however, this is an otherwise well executed and documented prospective study. Another worthy prospective study is by Zuolo et al. (82). They selected lesions of strictly endodontic origin (pockets less than 7 mm) and excluded through and through lesions or cases in which they found no buccal cortical plate. Healing after a 1 to 4 yr follow-up was 91.2% of 102 cases included in the recall. The study did not include the use of a microscope, but fiberoptic light was used to transilluminate the root. Out of the 102 case, 9 cases failed and out of these 9 cases 6 were molars, suggesting a higher incidence of molar failure (85%). This result is similar to Testori's (20) who used microsurgical instruments but not a microscope. The authors also did not mention finding isthmuses in molars, suggesting that they may not have identified them during the surgery. Maddalone and Gagliani 2003 (118) showed overall healing of 92.5% for 120 teeth with 28 molars. They used 4× loupes, ultrasonic tips and SuperEBA root-end fillings. They did not have strict inclusion criteria but stated that they did not include cases with compromised periodontal status. They compared their results with the works of Friedman et al. (133), and commented that the latter had fewer successful cases, possibly because they did not use ultrasonics. Maddalone and Gagliani (118) made no mention of isthmuses in their molar cases. Recently, Wang et al. (21) reported 74% healed cases of the 94 examined teeth that were treated with ultrasonic tips and various root-end filling materials (amalgam with varnish, SuperEBA, composite resin, and MTA). This seemingly low healing, compared to the other studies, may be a result of the use of amalgam and beveling. There was no mention of isthmuses in molar teeth, although 58 posterior teeth having been examined. This suggests that the resected root surfaces were not inspected for isthmuses. These prospective studies support the premise that the treatment outcome can be significantly improved with the use of ultrasonic tips and biologically acceptable root-end filling materials, even when not all of the microsurgical techniques are used.

Ultrasonics and the Microscope: The Complete Microsurgical Approach

Figure 27 shows a radiograph displaying the long-term success of a typical molar case performed with a strict microsurgical protocol using MTA as the root-end filling material. To the untrained eye the filling looks continuous, just somewhat larger. In contrast, Fig. 28 shows the way the microsurgical technique allows the surgeon to identify the unique canal anatomy and how it can be managed correctly.

In this category, there are two published prospective works. Rubinstein and Kim (3) evaluated the microsurgical techniques using only one root-end filling material, SuperEBA. They had strict criteria, selecting cases with pure endodontic lesions only. Ninety-four teeth (32 anteriors, 31 premolars, and 32 molars) were subjected to strict microsurgical procedures under the microscope, as described in this review. The purpose of this study was to evaluate microsurgical endodontic techniques. Briefly, all apices were resected 3 mm perpendicular to the long axis of the root. No bevel was made and the size of the osteotomy was usually 4 mm in diameter. The resected root surface was stained with methylene blue and was reflected in a micromirror for examination under the microscope at high magnification (16-24×). The apical canals were prepared 3 mm deep with ultrasonic tips and were subsequently sealed with SuperEBA. Recall radiographs were taken at 3-months intervals for 1 yr. The resolution of periapical radiolucencies along with the reestablishment of the lamina dura as well as the absence of symptoms were considered for healing. After 1 yr, 96.8% of the cases reported had healed (3), and recalls of the same cases after 5 to 7 yr showed a sustained healing of 91% (122).

In 2003, Chong and Pitt Ford (19) compared IRM versus MTA with the same technique for both groups. This RCT was designed to assess and compare the success of two popular root-end filling materials, MTA and IRM. Because the same microsurgical techniques were used, this was an ideal way to evaluate the techniques as well as the materials. Both materials promoted high levels of healing in 24 months: 92% with MTA and 87% with IRM. The authors had strict inclusion and exclusion

criteria: no pockets more than 4 mm deep and no mobility. Results of the studies by two different groups clearly demonstrate that the complete microsurgical technique using the appropriate root-end filling materials provides a higher degree of success than any other techniques used in the past.

Summary

Endodontic surgery has now evolved into endodontic microsurgery. By using state-of-the-art equipment, instruments and materials that match biological concepts with clinical practice, we believe that microsurgical approaches produce predictable outcomes in the healing of lesions of endodontic origin. We must consistently learn and teach microsurgery to all endodontists so that they can treat nonsurgical as well as surgical endodontic cases with equal ease and skill. With a high percentage of successful treatment outcomes of conventional endodontics together with high success of surgical endodontics almost all teeth with endodontic lesions can be successfully treated. The challenge for the future will be the successful and predictable management of periendo lesions.

We must continuously run well controlled experiments, clinical as well as biological, on many new techniques and materials to meet the present and future challenges. On the basis of published research, we believe that endodontic microsurgery with MTA is a predictable procedure to save teeth. We must assertively teach the future generation of graduate students, and also train our colleagues to incorporate these techniques into everyday clinical practice, similar to what periodontists did 15 yr ago with implants.

The preservation of our natural teeth must be our ultimate goal. After all, when all is said and done, our natural teeth are always better than any man-made replacement.

Acknowledgments

We express our sincere thanks to Drs. G. Carr, G. Pecora, and R. Rubinstein for pioneering and developing endodontic microsurgery. Our special thanks to our graduate students, Drs. F. Setzer, M. Korli, J. Song, and I. Ping for helping us to complete this article. We would like to express our sincere gratitude to Dr. Mian Iqbal for revising the figures and Jutta Dörscher-Kim for editing.

Supplementary data

Supplementary data associated with this article can be found, in the online version, at doi:[10.1016/j.joen.2005.12.010](https://doi.org/10.1016/j.joen.2005.12.010).

References

- Kim S, Pecora G, Rubinstein R. Comparison of traditional and microsurgery in endodontics. In: Kim S, Pecora G, Rubinstein R, eds. Color atlas of microsurgery in endodontics. Philadelphia: W.B. Saunders, 2001:5–11.
- Kim S. Principles of endodontic microsurgery. Dent Clin North Am 1997;41:481–97.
- Rubinstein RA, Kim S. Short-term observation of the results of endodontic surgery with the use of a surgical operation microscope and Super-EBA as root-end filling material. J Endod 1999;25:43–8.
- Carr GB. Microscope in endodontics. J Calif Dent Assoc 1992;20:55–61.
- Carr GB. Surgical endodontics. In: Cohen S, Burns R, eds. Pathways of the pulp, 6th ed. St Louis: Mosby, 1994:531.
- Saunders WP, Saunders EM. Coronal leakage as a cause of failure in root-canal therapy (a review). Endod and Dent Traumatology 1994;10:105–8.
- Kerekes K, Tronstad L. Long-term results of endodontic treatment performed with a standardized technique. J Endod 1979;5:83–90.
- Jokinen MA, Kotilainen R, Poikkeus P, et al. Clinical and radiographic study of pulpectomy and root canal therapy. Scand J Dent Res 1978;86:366–73.
- Bergenholtz G, Lekholm U, Milthorpe R, Heden G, Odesjo B, Engstrom B. Retreatment of endodontic fillings. Scand J Dent Res 1979;87:217–24.
- Gorni FG, Gagliani MM. The outcome of endodontic retreatment: a 2-yr follow-up. J Endod 2004;30:1–4.
- Nair PN. New perspectives on radicular cysts: do they heal? Int Endod J 1998;31:155–60.
- Nair PN. Non-microbial etiology: foreign body reaction maintaining post-treatment apical periodontitis. Endod Topics 2003;6:114–34.
- Nair PN, Pajarola G, Schroeder HE. Types and incidence of human periapical lesions obtained with extracted teeth. Oral Surg Oral Med Oral Pathol Oral Radiol Endod 1996;81:93–102.
- Nair PN. New perspectives on radicular cysts: do they heal? Int Endod J 1998;31:155–60.
- Nair PN. Pathogenesis of apical periodontitis and the causes of endodontic failures. Crit Rev Oral Biol Med 2004;15:348–381.
- Nair PN, Sjogren U, Schumacher E, Sundqvist G. Radicular cyst affecting a root-filled human tooth: a long-term post-treatment follow-up. Int Endod J 1993;26:225–33.
- Simon JH. Incidence of periapical cysts in relation to the root canal. J Endod 1980;6:845–8.
- Pecora G, Andreana S. Use of dental operating microscope in endodontic surgery. Oral Surg Oral Med Oral Pathol 1993;75:751–8.
- Chong BS, Pitt Ford TR, Hudson MB. A prospective clinical study of Mineral Trioxide Aggregate and IRM when used as root-end filling materials in endodontic surgery. Int Endod J 2003;36:520–6.
- Testori T, Capelli M, Milani S, Weinstein RL. Success and failure in periradicular surgery: a longitudinal retrospective analysis. Oral Surg Oral Med Oral Pathol Oral Radiol Endod 1999;87:493–8.
- Wang N, Knight K, Dao T, Friedman S. Treatment outcome in endodontics: the Toronto Study. Phases I and II: apical surgery. J Endod 2004;30:751–61.
- Commission on Dental Accreditation of the American Dental Association. Standards for Advanced Specialty Education Programs in Endodontics. 1998; (revised 2004).
- Buckley JA, Ciancio SG, McMullen JA. Efficacy of epinephrine concentration on local anesthesia during periodontal surgery. J Periodontol 1984;55:653–7.
- Gutmann JL. Parameters of achieving quality anesthesia and hemostasis in surgical endodontics. Anesth Pain Control Dent 1993;2:223–6.
- Troullos ES, Goldstein DS, Hargreaves KM, Dionne RA. Plasma epinephrine levels and cardiovascular response to high administered doses of epinephrine contained in local anesthesia. Anesth Prog 1987;34:10–3.
- Holroyd SV, Watts DT, Welch JT. The use of epinephrine in local anesthetics for dental patients with cardiovascular disease: a review of the literature. J Oral Surg Anesth Hosp Dent Serv 1960;18:492–503.
- Malamed S. Handbook of local anesthesia, 1st ed. St. Louis: C.V. Mosby Co., 1980.
- Dionne RA, Goldstein DS, Wirdzek PR. Effects of diazepam premedication and epinephrine-containing local anesthetic on cardiovascular and plasma catecholamine responses to oral surgery. Anesth Analg 1984;63:640–6.
- Witherspoon DE, Gutmann JL. Hemostasis in periradicular surgery. Int Endod J 1996;29:135–49.
- Jastak JT, Yagiela JA. Vasoconstrictors and local anesthesia: a review and rationale for use. J Am Dent Assoc 1983;107:623–30.
- Kim S, Rethnam S. Hemostasis in endodontic microsurgery. Dent Clin North Am 1997;41:499–511.
- Vy CH, Baumgartner JC, Marshall JG. Cardiovascular effects and efficacy of a hemostatic agent in periradicular surgery. J Endod 2004;30:379–83.
- Horsley V. Antiseptic wax. BMJ 1892;1:1165.
- Selden HS. Bone wax as an effective hemostat in periapical surgery. Oral Surg Oral Med Oral Pathol 1970;29:262–4.
- Ibarrola JL, Bjorenson JE, Austin BP, Gerstein H. Osseous reactions to three hemostatic agents. J Endod 1985;11:75–83.
- Besner E. Systemic effects of racemic epinephrine when applied to the bone cavity during periapical surgery. Va Dent J 1972;49:9–12.
- Evans BE. Local hemostatic agents. N Y J Dent 1977;47:109–14.
- Lemon RR, Steele PJ, Jeanson BG. Ferric sulfate hemostasis: effect on osseous wound healing: I. left in situ for maximum exposure. J Endod 1993;19:170–3.
- Kramper BJ, Kaminski EJ, Osetek EM, Heuer MA. A comparative study of the wound healing of three types of flap design used in periapical surgery. J Endod 1984;10:17–25.
- Velvart P. Papilla base incision: a new approach to recession-free healing of the interdental papilla after endodontic surgery. Int Endod J 2002;35:453–80.
- Gutmann JL, Harrison JW. Surgical Endodontics. Boston: Blackwell Scientific Publications, 1991.
- Lubow RM, Wayman BE, Cooley RL. Endodontic flap design: analysis and recommendations for current usage. Oral Surg 1984;58:207–12.
- Zimmermann U, Ebner JP, Velvart P. Papilla healing following sulcular full thickness flap in endodontic surgery. J Endod 2001;27:219.
- Velvart P, Ebner-Zimmermann U, Ebner JP. Comparison of long-term papilla healing following sulcular full thickness flap and papilla base flap in endodontic surgery. Int Endod J 2004;37:687–93.
- Velvart P, Peters CI. Soft tissue management in endodontic surgery. J Endod 2005;31:4–16.

46. Boyne P, Lyon H, Miller C. The effects of osseous implant materials on regeneration of alveolar cortex. *Oral Surg Oral Med Oral Pathol* 1961;xx:369–78.
47. Hjorting-Hansen E. Studies on implantation of anorganic bone in cystic jaw lesions. (Thesis) Munksgaard, Copenhagen, 1970.
48. Hjorting-Hansen E, Andreasen JO. Incomplete bone healing of experimental cavities in dog mandibles. *Br J Oral Surg* 1971;9:33–40.
49. Rud J, Andreasen JO. A study of failures after endodontic surgery by radiographic, histologic and stereomicroscopic methods. *Int J Oral Surg* 1972;1:311–28.
50. Gutmann JL, Harrison JW. Posterior endodontic surgery: anatomical considerations and clinical techniques. *Int Endod J* 1985;18:8–34.
51. Gutmann JL, Pitt Ford TR. Management of the resected root end: a clinical review. *Int Endod J* 1993;26:273–83.
52. Gutmann JL, Harrison JW. Periradicular curettage, root-end resection, root-end filling. In: Gutmann JL, Harrison JW, eds. *Surgical endodontics*. Boston: Blackwell Scientific Publications, 1991:208–213.
53. Kim S. Endodontic microsurgery. In: Cohen S, Burns R, eds. *Pathways of the pulp*, 8th ed. St Louis: Mosby, 2002:683–721.
54. Gilheany PA, Figdor D, Tyas MJ. Apical dentin permeability and microleakage associated with root end resection and retrograde filling. *J Endod* 1994;20:22–6.
55. Hsu YY, Kim S. The resected root surface. The issue of canal isthmuses. *Dent Clin North Am* 1997;41:529–40.
56. Altonen M, Mattila K. Follow-up study of apicoectomized molars. *Int J Oral Surg* 1976;5:33–40.
57. Lustmann J, Friedman S, Shaharabany V. Relation of pre- and intraoperative factors to prognosis of posterior apical surgery. *J Endod* 1991;17:239–41.
58. Rahbaran S, Gilthorpe MS, Harrison SD, Gulabivala K. Comparison of clinical outcome of periapical surgery in endodontic and oral surgery units of a teaching dental hospital: a retrospective study. *Oral Surg Oral Med Oral Pathol Oral Radiol Endod* 2001;91:700–9.
59. Rapp EL, Brown CE Jr, Newton CW. An analysis of success and failure of apicoectomies. *J Endod* 1991;17:508–12.
60. August DS. Long-term, postsurgical results on teeth with periapical radiolucencies. *J Endod* 1996;22:380–3.
61. Merriam Webster's Collegiate Dictionary 10th ed. Springfield, Merriam Webster 1993.
62. Green D. Double canals in single roots. *Oral Surg Oral Med Oral Pathol* 1973;35:689–96.
63. Pineda F. Roentgenographic investigation of the mesiobuccal root of the maxillary first molar. *Oral Surg Oral Med Oral Pathol* 1973;36:253–60.
64. Vertucci FJ. Root canal anatomy of the human permanent teeth. *Oral Surg Oral Med Oral Pathol* 1984;58:589–99.
65. Weller RN, Niemczyk SP, Kim S. Incidence and position of the canal isthmus: part 1. Mesiobuccal root of the maxillary first molar. *J Endod* 1995;21:380–3.
66. Cambuzzi JV, Marshall FJ. Molar endodontic surgery. *J Can Dent Assoc* 1983;1:61–6.
67. Carr GB. Ultrasonic root end preparation. *Dent Clin North Am* 1997;41:541–4.
68. Von Arx T, Kurt B. Root-end cavity preparation after apicoectomy using a new type of sonic and diamond-surfaced retrotip: a 1-year follow-up study. *J Oral Maxillofac Surg* 1999;57:656–61.
69. Richman MJ. The use of ultrasonics in root canal therapy and resection. *J Dent Med* 1957;12:12–8.
70. Engel TK, Steiman HR. Preliminary investigation of ultrasonic root-end preparation. *J Endod* 1995;21:443–8.
71. Wuchenich G, Meadows D, Torabinejad M. A comparison between two root end preparation techniques in human cadavers. *J Endod* 1994;20:279–82.
72. Saunders WP, Saunders M, Gutmann JL. Ultrasonic root end preparation: part 2-microleakage of EBA root end fillings. *Int Endod J* 1994;27:325–9.
73. Layton CA, Marshall G, Morgan L, Baumgartner C. Evaluation of cracks associated with ultrasonic root end preparations. *J Endod* 1996;22:157–60.
74. Waplington M, Lumley PJ, Walmsley AD, Blunt L. Cutting ability of an ultrasonic retrograde cavity preparation instrument. *Endod Dent Traumatol* 1995;11:177–80.
75. Min MM, Brown CE Jr, Legan JJ, Kafrawy AH. In vitro evaluation of effects of ultrasonic root end preparation on resected root surfaces. *J Endod* 1997;23:624–8.
76. Gray JG, Hutton J, Holtzmann DJ, Jenkins DB, Neilsen CJ. Quality of root end preparations using ultrasonic and rotary instrumentations in cadavers. *J Endod* 2000;26:281–3.
77. Calzonetti KJ, Iwanowski T, Komorowski R, Friedman S. Ultrasonic root-end cavity preparation assessed by an in situ impression technique. *Oral Surg Oral Med Oral Pathol Oral Radiol Endod* 1998;85:210–5.
78. Morgan LA, Marshall JG. A scanning electron microscopic study of in vivo ultrasonic root-end preparations. *J Endod* 1999;25:567–70.
79. Navarre SW, Steiman R. Root-end fracture during retropreparation: a comparison between zirconium nitride-coated and stainless steel microsurgical ultrasonic instruments. *J Endod* 2002;28:330–2.
80. Peters CI, Peters OA, Barbakow F. An in vitro study comparing root-end cavities prepared by diamond coated and stainless steel ultrasonic retrotips. *Int Endod J* 2001;34:142–8.
81. Brent PD, Morgan LA, Marshall JG, Baumgartner JC. Evaluation of diamond-coated ultrasonic instruments for the root-end preparation. *J Endod* 1999;25:672–5.
82. Zuolo ML, Ferreira MO, Gutmann JL. Prognosis in periradicular surgery: a clinical prospective study. *Int Endod J* 2000;33:91–8.
83. Torabinejad M, Pitt Ford TR. Root end filling materials: a review. *Endod Dent Traumatol* 1996;12:161–78.
84. Szeremeta-Brower TL, VanCura JE, Zaki AE. A comparison of the sealing properties of different retrograde techniques: an autoradiographic study. *Oral Surg Oral Med Oral Pathol* 1985;59:82–7.
85. Bondra DL, Hartwell GR, MacPherson MG, Portell FR. Leakage in vitro with IRM, high copper amalgam, and EBA cement as retrofilling materials. *J Endod* 1989;15:157–60.
86. Pitt Ford TR, Andreasen JO, Dorn SO, Kariyawasam SP. Effect of IRM root-end fillings on healing after replantation. *J Endod* 1994;20:381–5.
87. Pitt Ford TR, Andreasen JO, Dorn SO, Kariyawasam SP. Effect of Super EBA as a root-end filling on healing after replantation. *J Endod* 1995;21:13–5.
88. Torabinejad M, Hong CU, Pitt Ford TR, Kettering JD. Cytotoxicity of four root end filling materials. *J Endod* 1995;21:489–92.
89. Torabinejad M, Hong CU, Pitt Ford TR, Kariyawasam SP. Tissue reaction to implanted super-EBA and mineral trioxide aggregate in the mandible of guinea pigs: a preliminary report. *J Endod* 1995;21:569–71.
90. Torabinejad M, Rastegar AF, Kettering JD, Pitt Ford TR. Bacterial leakage of mineral trioxide aggregate as a root-end filling material. *J Endod* 1995;21:109–12.
91. Torabinejad M, Chivian N. Clinical applications of mineral trioxide aggregate. *J Endod* 1999;25:197–205.
92. Torabinejad M, Pitt Ford TR, McKendry DJ, Abedi HR, Miller DA, Kariyawasam SP. Histologic assessment of mineral trioxide aggregate as a root-end filling in monkeys. *J Endod* 1997;23:225–8.
93. Thomson TS, Berry JE, Somerman MJ, Kirkwood KL. Cementoblasts maintain expression of osteocalcin in the presence of mineral trioxide aggregate. *J Endod* 2003;29:407–12.
94. Baek SH, Plenk H Jr, Kim S. Periapical tissue responses and cementum regeneration with amalgam, SuperEBA, and MTA as root-end filling materials. *J Endod* 2005;31:444–9.
95. Shin S. In vitro studies addressing cellular mechanisms underlying the bone and dentin inductive property of mineral trioxide aggregate. Master thesis in oral biology. (Thesis) University of Pennsylvania, 2004.
96. Camilleri J, Montesin FE, Brady K, Sweeney R, Curtis RV, Ford TR. The constitution of mineral trioxide aggregate. *Dent Mater* 2005;21:297–303.
97. Asgary S, Parirokh M, Eghbal MJ, Brink F. Chemical differences between white and gray mineral trioxide aggregate. *J Endod* 2005;31:101–3.
98. Pérez AL, Spears R, Gutmann JL, Opperman LA. Osteoblasts and MG-63 osteosarcoma cells behave differently when in contact with ProRoot MTA and White MTA. *Int Endod J* 2003;36:564–70.
99. Camilleri J, Montesin FE, Papaioannou S, McDonald F, Pitt Ford TR. Biocompatibility of two commercial forms of mineral trioxide aggregate. *Int Endod J* 2004;37:699–704.
100. Moghaddame-Jafari S, Mantellini MG, Botero TM, McDonald MJ, Nor JE. Effect of ProRoot MTA on pulp cell apoptosis and proliferation in vitro. *J Endod* 2005;31:387–91.
101. Ferris D, Baumgartner JC. Perforation repair comparing two types of mineral trioxide aggregate. *J Endod* 2004;30:422–4.
102. Al-Hezaimi K, Naghshbandi J, Oglesby S, Simon J, Rotstein I. Human saliva penetration of root canals obturated with two types of mineral trioxide aggregate cements. *J Endod* 2005;31:453–6.
103. Holland R, de Souza V, Nery MJ, et al. Reaction of rat connective tissue to implanted dentin tube filled with mineral trioxide aggregate, Portland cement or calcium hydroxide. *Braz Dent J* 2001;12:3–8.
104. Holland R, de Souza V, Nery MJ, et al. Reaction of rat connective tissue to implanted dentin tubes filled with a white mineral trioxide aggregate. *Braz dent J* 2002;13:23–6.
105. Faraco Junior IM, Holland R. Response of the pulp of dogs to capping with mineral trioxide aggregate or calcium hydroxide cement. *Dent Traumatol* 2001;17:163–6.
106. Faraco Junior IM, Holland R. Histomorphological response of dogs' dental pulp capped with white mineral trioxide aggregate. *Braz Dent J* 2004;15:104–8.
107. Phillips JL, Weller RN, Kulild JC. The mental foramen: 1. Size, orientation, and positional relationship to the mandibular second premolar. *J Endod* 1990;16:221–3.
108. Phillips JL, Weller RN, Kulild JC. The mental foramen: part 2. Radiographic position in relation to mandibular second premolar. *J Endod* 1992;18:271–4.
109. Meechan JG, Blair GS. The effect of two different local anaesthetic solutions on pain experience following apicectomy. *Br Dent J* 1993;175:410–3.

110. Kvist T, Reit C. Postoperative discomfort associated with surgical and nonsurgical endodontic retreatment. *Endod Dent Traumatol* 2000;16:71–4.
111. Tsesis I, Fuss Z, Lin S, Tilinger G, Peled M. Analysis of postoperative symptoms following surgical endodontic treatment. *Quintessence Int* 2003;34:756–60.
112. Wong WS, Rosenberg PA, Boylan RJ, Schulman A. A comparison of the apical seal achieved using retrograde amalgam fillings and the Nd:YAG laser. *J Endod* 1994;20:595–7.
113. Bader G, Lejeune S. Prospective study of two retrograde endodontic apical preparations with and without the use of CO₂ laser. *Endod Dent Traumatol* 1998;14:75–8.
114. Maillet WA, Torneck CD, Friedman S. Connective tissue response to root surfaces resected with Nd:YAG laser or burs. *Oral Surg Oral Med Oral Pathol* 1996;82:681–90.
115. Paghdiala AF. Root resection of endodontically treated teeth by erbium: YAG laser radiation. *J Endod* 1993;19:91–4.
116. Komori T, Tokoyama K, Takate T, Matsumoto K. Clinical application of the Erbium: YAG laser for apicoectomy. *J Endod* 1997;23:748–50.
117. Gouw-soares S, Tanji E, Haypek P, Cardoso W, Eduarso CP. The use of Er:YAG, Nd:YAG and Ga-Al-As lasers in periapical surgery: a 3-year clinical study. *J Clin Laser Med Surg* 2001;19:193–8.
118. Maddalone M, Gagliani M. Periapical endodontic surgery: a 3-year follow-up study. *Int Endod J* 2003;36:193–8.
119. Schwartz-Arad D, Yarom N, Lustig JP, Kaffe I. A retrospective radiographic study of root-end surgery with amalgam and intermediate restorative material. *Oral Surg Oral Med Oral Pathol Oral Radiol Endod* 2003;96:472–7.
120. Von Arx T, Gerber C, Hardt N. Periradicular surgery of molars: a prospective clinical study with a 1-year follow up. *Int Endod J* 2001;34:520–5.
121. Wesson CM, Gale TM. Molar apicoectomy with amalgam root-end filling: results of a prospective study in two district general hospitals. *Br Dent J* 2003;195:707–14.
122. Rubinstein RA, Kim S. Long-term follow-up of cases considered healed 1 year after apical microsurgery. *J Endod* 2002;28:378–83.
123. Rahbaran S, Gilthorpe MS, Harrison SD, Gulabivala K. Comparison of clinical outcome of periapical surgery in endodontics and oral surgery units of a teaching dental hospital: a retrospective study. *Oral Surg Oral Med Oral Pathol Oral Radiol Endod* 2001;91:700–9.
124. Rud J, Rud V, Munksgaard EC. Periapical healing of mandibular molars after root-end sealing with dentine bonded composites. *Int Endod J* 2001;34:285–92.
125. Halse A, Molven O, Grung B. Follow-up after periapical surgery: the value of the one-year control. *Endod Dent Traumatol* 1991;7:246–50.
126. Rahbaran S, Gilthorpe MS, Harrison SD, Gulabivala K. Comparison of clinical outcome of periapical surgery in endodontic and oral surgery units of a teaching dental hospital: a retrospective study. *Oral Surg Oral Med Oral Pathol Oral Radiol Endod* 2001;91:700–9.
127. Danin J, Linder LE, Lundqvist G, Ohlsson L, Ramsköld L, Strömberg T. Outcomes of periradicular surgery in cases with apical pathosis and untreated canals. *Oral Surg Oral Med Oral Pathol Oral Radiol Endod* 1999;87:227–232.
128. Molven O, Halse A, Grung B. Surgical management of endodontic failures. Indications and treatment results. *Int J Dent* 1991;41:33–42.
129. Harty FJ, Parkins BJ, Wengraf AM. The success rate of apicoectomy. *Br Dent J* 1970;129:407–13.
130. Frank AL, Glick DH, Patterson SS, Weine FS. Long-term evaluation of surgically placed amalgam fillings. *J Endod* 1992;18:391–8.
131. Bader G, Lejeune S. Prospective study of two retrograde endodontic apical preparations with and without the use of CO₂ laser. *Endod Dent Traumatol* 1998;14:75–8.
132. Dorn SO, Gartner AH. Retrograde filling materials: a retrospective success-failure study of amalgam, EBA, and IRM. *J Endod* 1990;16:391–3.
133. Friedman S, Lustmann J, Shaharabany V. Treatment results of apical surgery in premolar and molar teeth. *J Endod* 1991;7:30–3.