



Published for the
dental professional
community by the
American
Association of
Endodontists.

Spring/Summer
1997

ENDODONTICS

COLLEAGUES FOR EXCELLENCE

Evaluating Endodontic Treatment Risk Factors

New guidelines help practitioners decide what's best for patients

Each time you decide to treat a patient, you take a risk. As a responsible professional, you treat only those cases with which you believe you can achieve a predictable outcome.

When you decide whether to treat a patient, you factor in your level of knowledge, degree of expertise, and the available technology. You consider the specific challenges or risks presented by the patient and tooth or teeth in question. You analyze the situation,

determine your chance for success, summarize your assessment for the patient, and either proceed with your treatment plan or refer the patient to a specialist.

The process sounds simple, but how do you explain it to a second year dental student? ...to a patient who doesn't want to go to a specialist for treatment? ...to an insurance or managed care company that would rather have you treat the case, even though you feel it should be referred?

Factors that add risk to endodontic cases

PATIENT CONSIDERATIONS

- Medical History
- Local Anesthetic Considerations
- Personal Factors and General Considerations

OBJECTIVE CLINICAL FINDINGS

- Diagnosis
- Radiographic Findings
- Pulpal Space
- Root Morphology
- Apical Morphology
- Malpositioned Teeth

ADDITIONAL CONDITIONS

- Restorability
- Existing Restoration
- Fractured Tooth
- Resorptions
- Endo-Perio Lesion
- Trauma
- Previous Endodontic Treatment
- Perforations

Dentists can use a new AAE assessment form to rate the risk presented by each factor as Average (1), High (2), or Extreme (3). A case with all Average (1) ratings should be a fairly straightforward case.



**Extra
Risk**

If one or more factors present High (2) or Extreme (3) Risk, dentists can plan how to manage this extra risk prior to initiating treatment.

Educators give assessment form positive reviews

Dr. Christen J. Nielsen, Endodontic Section Head at Southern Illinois University appreciates the work the AAE put into the *Guidelines for Assessing the Difficulty of Endodontic Cases*. "It is obviously well thought out and all-inclusive," he remarks.

While he points out that students are swamped with paperwork in the clinic, he does plan to use the form when discussing treatment planning of patients. "Not only will it be used in lecture," he adds, "but I am considering distributing case scenarios with radiographs and this assessment form as homework to be treatment planned and discussed at the next class meeting."

Dental schools address risk assessment

Over the past decade, faculty at several dental schools have been studying new ways to teach students about assessing the risk involved in endodontic cases. Their goal was to define a protocol for endodontic case selection that would:

- ensure consistency in risk assessment,
- improve documentation of risk assessment,
- prevent procedural errors, and
- decrease the number of midtreatment referrals.

The protocols that developed proved to be valuable both for teaching and for instilling clinical judgment in students. In addition, they paved the way for the work required to meet a new mandate that educators must clearly define uncomplicated cases appropriate for treatment by predoctoral students.

AAE develops guidelines

The American Association of Endodontists reviewed the endodontic risk assessment systems developed by several schools, incorporated and modified elements from the best systems, and created an AAE approved system called *The American Association of Endodontists Guidelines for Assessing the Difficulty of Endodontic Cases*. The system uses a concise yet thorough assessment form that enables the practitioner to make endodontic case selection more consistent, efficient, and easier to document.

The *AAE Guidelines* and accompanying form have been made available nationally for use in predoctoral dental school settings and are included with this issue of *ENDODONTICS: Colleagues for Excellence*.

Concise, efficient assessment form

The *AAE Guidelines* provide a means of rating individual cases through the use of a one-page form called the *Endodontic Case Difficulty Assessment Form* (see opposite page). The form lists a number of categories, such as medical history, and segments the categories into subcategories as appropriate, such as cardiovascular diseases, bleeding disorders, etc.

The practitioner rates each subcategory as presenting an Average, High, or Extreme Risk using a numeric rating system on a scale of 1, 2, or 3.

- An Average Risk (1) rating indicates that the preoperative condition is of average or routine complexity. An experienced practitioner should attain a predictable treatment outcome.
- A High Risk (2) rating indicates that the preoperative condition is complicated. Achieving a predictable treatment outcome will be difficult for an experienced practitioner.
- An Extreme Risk rating (3) indicates that the preoperative condition is exceptionally complicated. Achieving a predictable outcome will be challenging for even the most highly skilled practitioner.

Using the assessment form

A user-friendly tool, the form helps practitioners record data and make a determination of risk assessment quickly and efficiently. In the span of a minute or two, ratings of Average (1), High (2), or Extreme (3) can be entered in the box next to each category. As practitioners get more familiar with the system, they may choose to expedite the process by entering numbers only in those areas that rate a 2 or 3.

If all the ratings fall in the Average category, the practitioner should feel confident treating the tooth if he or she has experience with the procedure. A combination of one or more ratings in the High area (2) or a single rating in the Extreme (3) category may be the basis for consultation with a specialist depending on the practitioner's level of experience with the particular risk(s).

Dentists can use this form to check for risks before initiating treatment. A full-size original copy of the form is included as an insert with this issue of *ENDODONTICS: Colleagues for Excellence*. The AAE has granted you permission to copy the form for use in your office.



Endodontic Case Difficulty Assessment Form

Patient Information

Name _____
 Address _____
 City/State/Zip _____
 Phone _____

PATIENT CONSIDERATIONS

Medical History
cardiovascular diseases
cerebral vascular considerations
bleeding disorders
renal dysfunction
medical prostheses
abnormalities in host defense
diabetes
mental impairment
acute systemic disease
pregnancy
need for pre-medications
other systemic conditions

Local Anesthetic Considerations

vasoconstrictor contraindication
anesthetic allergy
history of difficulty in obtaining profound anesthesia

Personal Factors and General Considerations

limited ability to open mouth
gagger
fear of dentistry
motivation to preserve dentition
physical impairment—difficulty holding film
limitation to be reclined
size of mouth

OBJECTIVE CLINICAL FINDINGS

Diagnosis
inconclusive or contradictory findings

Radiographic Findings
difficulty in obtaining films of diagnostic value

Pulpal Space
calcification
chamber
orifice
canal
number of canals

Root Morphology
curvature
dilaceration
long
recurvature
length
long
short

Apical Morphology
open

Malpositioned Teeth
buccal version
rotated or tipped
too far distally

ADDITIONAL CONDITIONS

Restorability
isolation challenge
caries
need for crown lengthening

Existing Restoration
porcelain crown
PBM/PFM
gold castings
impaired access to root canal
abutment
long axis of crown vs. long axis of root
size of crown
crown anatomy vs. original anatomy
post and core (Rate 2 or 3 only)

Fractured Tooth
crown
root

Resorptions
internal
external
apical

Endo-Perio Lesion
tooth mobility
attached gingiva minimal/inadequate
furcation involved
periodontal prognosis
root section or hemisection consideration

Trauma
avulsion
luxation

Previous Endodontic Treatment
Rate 2 or 3 only

Perforations
Rate 3 only

Disposition

Treat in Office Yes ☐ No ☐

Refer patient to: _____

Date: _____

The American Association of Endodontists' Guidelines for Assessing the Difficulty of Endodontic Cases are designed to aid the practitioner in determining appropriate case disposition. The American Association of Endodontists neither expressly or implicitly warrants any positive results associated with the use of these Guidelines. These Guidelines may be reproduced but may not be amended or altered in any way. © The American Association of Endodontists, 211 East Chicago Avenue, Suite 1100, Chicago, IL 60611-2691; 312/266-7255.

Sample cases

To become familiar with the Assessment Form, try it out on the following cases:
(Dentists may make photocopies of the form for use in their practices.)

Case A

A 28-year-old male presents with intra-oral swelling at the apex of tooth #9. The patient reports that the tooth is painful to pressure and has mild to moderate spontaneous pain. The tooth became sensitive to chewing about six days ago, and the pain has been increasing daily. Yesterday, he noticed a slight swelling above the tooth. When he woke this morning, the swelling was much worse, and he called for an emergency dental appointment.

The tooth has intact mesial and distal composite restorations that were placed three years ago. Extensive calcification of the pulp chamber and canal system is evident on the radiograph (Figure 1). When questioned, the patient reports that his front teeth received a severe blow while he was playing basketball in high school. The patient reports being allergic to several antibiotics, including penicillin and cephalosporins.

Figure 1

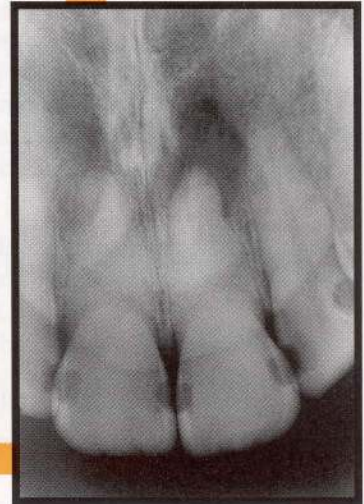
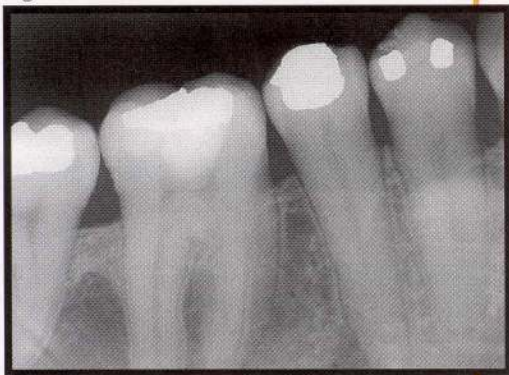

Figure 2



Case B

A 40-year-old male presents for routine examination. The medical history reveals no complications, and there are no present dental concerns. A full mouth radiographic survey indicates a radiolucency at the apex of the mandibular second premolar. The canal space is large and patent to the apex, and an angled radiograph confirms the likelihood of dealing with only a single canal (Figure 2). There is a moderately deep occlusal alloy restoration. The patient states that he has never had any pain in that tooth.

Case C

During her first appointment as a new patient, a 67-year-old female reports pain to cold and chewing from her lower right first molar. She states that these symptoms began about six months ago and that the sensitivity to cold has been increasing recently. She now avoids this side of her mouth when eating or drinking. The tooth has a large MODBL amalgam restoration with defective margins and a severe distal overhang. She states that the filling was placed many years ago. Radiographically, the chamber and canals in the mandibular second molar are easily visible, but the distal canal of the first molar appears calcified (Figure 3).

The patient suffers from arthritis, hypertension, depression, and diabetes. She takes Voltarin®, Lopressor®, Prozac®, insulin, and Premarin®. She mentions that she is difficult to numb and, at times, has not felt completely numb during previous dental visits.

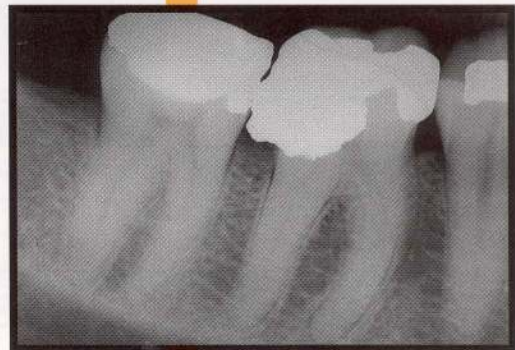


Figure 3

Case D

A 21-year-old male presents immediately after being hit in the mouth with a pool cue. The right maxillary central incisor is sheared off slightly below the gum line, and the pulp is exposed (Figure 4a). The patient has no pain except when breathing through his mouth. Radiographically there are no other fractures of tooth or bone noted. The tooth is stable in the arch, and the canal space appears patent to the apex (Figure 4b). Besides a deep lip laceration, there are no medical considerations.

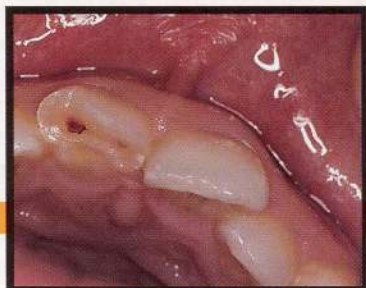

Figure 4a

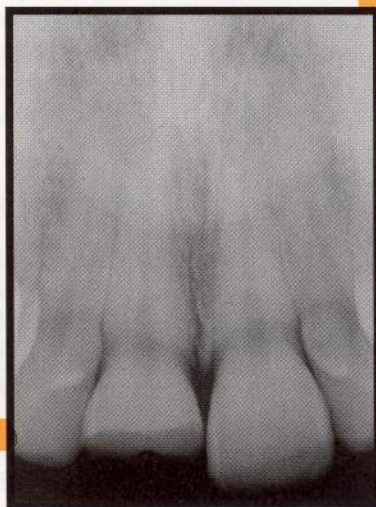


Figure 4b

Case E

A 32-year-old female reports a spontaneous toothache that woke her from sleep last night. The pain was only partially relieved by acetaminophen with codeine #3, which she had on hand from a previous dental emergency. Today, tooth #30 is extremely sensitive to pressure.

Your records indicate that five years ago an exposure of the MB pulp horn occurred during caries removal. A calcium hydroxide direct pulp cap and MO amalgam were placed. From the time that restoration was placed until last night, the tooth had been asymptomatic. A radiograph taken today shows that the pulp chamber and canals have narrowed since the pulp cap was performed. You also notice on today's radiograph the presence of a separate distolingual root (Figure 5).

This patient has mitral valve prolapse with valvular regurgitation and requires SBE prophylaxis before most dental procedures. She also has trouble opening her mouth very wide.

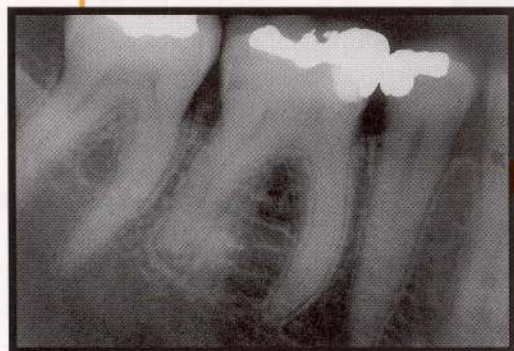

Figure 5

Private practice perspectives

Dr. Rod P. Strickland, a recent dental school graduate in private practice in Indianapolis, thinks the form will make a good reference chart. "I really enjoy endodontics and do about 90 percent of my own cases, so I probably wouldn't fill it out every time. But it would be nice to hang on the wall for reference, and it will be a good teaching aid for the schools."

Dr. Strickland says the new AAE form lists most of the risks he looks for when making endodontic treatment decisions. "If the patient is very apprehensive or the case is not particularly straightforward, I consider referral, or if there is a severe medical complication, a molar with a crown, or severely curved roots."

Dr. Strickland refers those cases to Indianapolis endodontist Dr. Charles L. Steffel, who thinks the form will help communication in a variety of ways. He points out, "Almost all general dentists treat at least some endodontic cases. Almost all general dentists refer at least some. The question is *How do you decide where to draw the line and how do you support your decision to the patient?*"

Dr. Steffel points out that the decision is never as simple as 'I do all anteriors and premolars.' "What about three-rooted premolars? What about the anterior tooth that is completely calcified due to trauma? All the risk factors like these have been consolidated on the AAE form to help with the decision."

Issues to consider when evaluating cases

Medical History

Many medical conditions, such as the allergies in Case A do not overly complicate treatment. However, the severity of each condition should be carefully evaluated. A potential complication, such as the multiple medications taken by the patient in Case C, can add extra risk to a case.

Another example would be a patient with uncontrolled diabetes. In such a circumstance, the case should receive a rating of 2 or 3 in this category, and consultation with the patient's physician prior to treatment would be advisable.

Local Anesthetic Considerations

Cases where profound anesthesia may be difficult to achieve should receive a higher rating, such as in Cases C and E. In Case C, the patient's history indicates difficulty in obtaining profound anesthesia. In Case E, the practitioner will be dealing with a "hot" tooth.

Personal Factors and General Considerations

These areas consider the patient's ability to assist, mentally and physically, in his/her treatment. Many patients simply have small mouths or limited opening, as in Case E. Since access to the root canals can be difficult in these patients, the predictability of the treatment outcome may be altered.

Radiographic and Diagnostic Issues

Prior to treatment, the practitioner should consider the question, "Will it be difficult to obtain images of diagnostic value?" For instance, the lower first premolar, while not generally a difficult tooth to treat is a very difficult tooth to radiograph because of its position in the mandible.

Before initiating endodontics, the most probable pulpal and periradicular diagnosis must be determined. If the practitioner is unsure of the diagnosis, referral to an appropriate specialist should be sought. (For a review of endodontic diagnosis, see the Fall/Winter 1996 *ENDODONTICS: Colleagues for Excellence*.)

Pulpal Space

As people age, their canals normally narrow as secondary and tertiary dentin are deposited. The calcification process can be accelerated by irritating stimuli such as trauma, caries, or the placement of restorations. Accelerated calcification is seen in Cases A, C, and E.

Calcification can dramatically affect the difficulty of endodontic treatment. Because experience is a major factor in locating calcified canals, the practitioner should consider his or her own degree of experience if the radiograph suggests difficulty in locating the canals.

Another factor to be rated is the number of canals. As the number of canals increases, so does the difficulty of the case due to increased chance for perforation or other procedural errors while searching for each canal. A good rule to follow is to *expect the extra canal*. For example, anatomical studies have shown that mandibular incisors often have two canals. In fact, advances in technique, magnification, and illumina-

tion have led to the discovery that root canal systems are often anatomically complex.

The most commonly missed canal is the mesiopalatal canal of maxillary molars. Historically, these canals were thought to be of minimal importance because it was believed that they were seldom present. When the canals

were present, dentists thought that they probably joined the mesiobuccal canal which, if sealed, would render the presence of the mesiopalatal canal unimportant. With increased lighting and magnification, however, dentists are finding mesiopalatal canals in the vast majority of first molar cases (Figure 6) and frequently in the maxillary second molar. The mesiopalatal canal often has a separate apical exit and is difficult to manage in even the most skilled of hands. Therefore, the ratings given maxillary molars should

reflect the likelihood of having to deal with four separate canal systems.

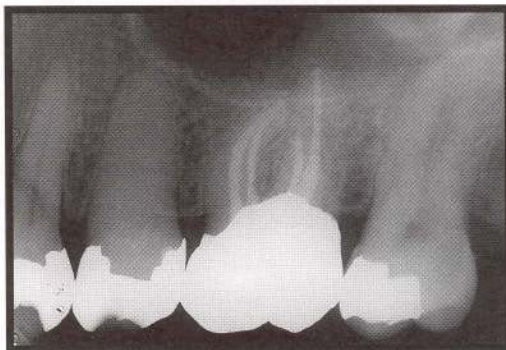

Figure 6. Four canal systems in maxillary first molars is the rule rather than the exception.

Root and Apical Morphology

No root canal is completely straight; an infinite variety of curvatures may be found. A gradual, gentle curve is to be expected from most canals. The more severe the curvature, the greater the likelihood of encountering a problem during cleaning and shaping. In addition, the mesial roots of mandibular molars often have a recurvature.

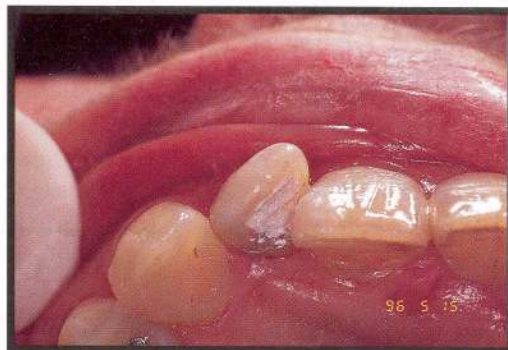Length must also be considered in rating risks presented by root morphology. Teeth that are either very short (less than 13 mm) or long (more than 24 mm) present greater degrees of difficulty.

Teeth with open apices present long-term management scenarios if apexification procedures are to be performed. The treatment may not always be difficult, but problems may arise in following the case to a conclusion over several years. Potential long-term management risks should be factored into the rating.

Malpositioned Teeth

Rotated teeth may present coronal access challenges that can affect treatment outcomes (Figure 7). The practitioner should look closely to see if straight line access to the canals can be obtained. For example, the maxillary second molar is occasionally positioned buccal to the rest of the arch, making access difficult. Because the maxillary second molar is already difficult for a number of reasons, a buccal version may rate a 2 or 3.

Figure 7. Rotation of the lateral incisor increases the case difficulty.



Restorability

Endodontically treated teeth will need a final restoration, and posterior teeth require the occlusal coverage provided by a cast restoration. Often teeth in need of endodontic treatment have considerable structure loss due to caries. When restoring these teeth, the concept of biological width is extremely important.

The distance between the restoration margin and the alveolar crest should be a minimum of 2-3 mm. When this amount of tooth structure is not present, the possibility of crown-lengthening or orthodontic extrusion should

be evaluated. These procedures may even be necessary prior to root canal treatment to ensure proper placement of the dental dam.

Even if the practitioner can achieve an excellent endodontic result, if the tooth cannot be properly restored then prognosis for the tooth is poor. Therefore, issues of restorability deserve proper evaluation prior to the initiation of treatment. (For a review of considerations for restoration of endodontically treated teeth, see the Fall/Winter 1995 *ENDODONTICS: Colleagues for Excellence*.)

Existing Restorations

Often, a tooth needing endodontics will already have a cast restoration. Most nonsurgical endodontics can be performed through the existing restoration. Possible problems lie in the fact that the restoration may not represent the anatomy of the natural crown. Thus, landmarks for making an access cavity and locating

canals may be misleading. These factors should be reflected in the rating.

When the tooth is a bridge abutment, it may have tilted mesially due to a previous extraction. In these instances, the long axis of the crown may not be in the long axis of the root. This can severely complicate treatment.

Applications for insurance

Dr. Howard B. Fine, an endodontist and member of the American Dental Association Advisory Committee on the Code to the Council on Dental Benefit Programs, points out the value of the form for communications with insurance companies and managed care entities. "Current insurance codes don't address degree of difficulty, but these companies make decisions on referral based on the degree of difficulty. They are creating their own criteria.

"By taking the initiative to create a universal codification for risk," Dr. Fine continues, "the AAE is ensuring that risk will be defined by the dental profession, not by plan managers. The AAE has given dentists a consistent means to support clinical decisions when they feel cases need specialty care."

Retreatments, Perforations

Any tooth that has been previously treated presents at least a High Risk (2) situation, and the majority present Extreme Risk (3). Additionally, perforated cases always present an Extreme Risk (3). Experience, advances in magnification and illumination, and instruments made specifically for retreatment and perforation repair are providing promising treatment modalities for many of these situations, but there is still progress to be made.

Other Possible Complications

Subgingival and certainly subcrestal fractures may present difficult or impossible treatment situations. They rate an Extreme Risk (3).

Internal non-perforating resorption may or may not present treatment complications. However, external resorption can be quite complicated and almost always deserves an Extreme (3) rating. Accurate diagnosis of the type of resorption is imperative and can be challenging in many cases.

Trauma, as seen in Case D, may require extensive care, posing increased risk of treatment failure. While the severity of the particular injury must be taken into account, traumatic injury generally places a tooth in a higher risk category than if it required endodontics for nontraumatic reasons.

A tooth with a marginal periodontal prognosis should receive further evaluation. Where periodontal problems exist, a team approach, possibly in consultation with a periodontist and endodontist, may improve predictability. In some cases, extraction may be recommended after consultation if the risk factors outweigh the possible benefits of treatment.

Practical advice

"We don't expect every dentist to fill out the form on every case," AAE President Dr. Jerome V. Pisano clarifies. "The form simply lists the risks we all learned to check for before initiating endodontic treatment."

Dr. Pisano recommends using the form on a few cases to refresh or simplify your approach. "Because dozens of risks must be considered on each case," Dr. Pisano says, "the value of the form is that the risks are all organized and categorized in a simple format."

"After you've streamlined your risk assessment process," he continues, "you could just use the form as necessary, when a case is particularly complex, when you need to explain your decision, or when you need a record of the assessment."

Summary

The *AAE Endodontic Case Difficulty Assessment Form* and *Guidelines* are enclosed for your use. Practitioners may duplicate the enclosed form for use in their practices. Our common goal is the optimum dental health of our patients, and accurate assessment of risk will bring us all closer to that goal.

While there is no guarantee of success in every case, the American Association of Endodontists (AAE) hopes this issue of *ENDODONTICS: Colleagues for Excellence* will aid the practitioner in assessing the risk involved in endodontics cases. Practitioners must always use their best professional

judgment in individual situations. The AAE neither expressly nor implicitly warrants any positive results nor expressly nor implicitly warrants against any negative results associated with the application of this information.

If you would like more information on risk assessment, call your local endodontist or contact the American Association of Endodontists, 211 E. Chicago Ave., Ste. 1100, Chicago, IL 60611-2691, 312/266-7255, fax 312/266-9867, e-mail ebaldwin@aae.org.

References are available upon request.

Comments? Did you enjoy this issue of *ENDODONTICS*? Did the information have a positive impact on your practice? Are there topics you would like *ENDODONTICS* to cover in the future? We want to hear from you! Send your comments, questions, and suggestions to:

ENDODONTICS

American Association of Endodontists
211 East Chicago Avenue, Suite 1100
Chicago, IL 60611-2691



**Spring/Summer 1997 ENDODONTICS: *Colleagues for Excellence*
Evaluating Endodontic Treatment Risk Factors Selected References**

- Barr JH, Stephens RG (eds). Dental radiology. Philadelphia: Saunders; 1980:381-4.
- Benjamin KA, Dowson, J. Incidence of two root canals in human mandibular incisor teeth. Oral Surg Oral Med Oral Pathol 58(5): 589, 1984.
- Benjamin KA, Dowson J. Incidence of two root canals in human mandibular incisor teeth. Oral Surg Oral Med Oral Pathol 1974;32:122-6.
- Burns R, Buchanan LS. Tooth morphology and access opening. In Cohen, S., Burns, RC (eds). Pathways of the Pulp, 6th ed. St. Louis, CV Mosby, 1994, p. 131.
- Cohen S, Burns, RC (eds). Pathways of the pulp. 5th ed. St. Louis: Mosby; 1991.
- Cohen S, Schwartz S. Endodontic complications and the law. J Endodont 13:191, 1987.
- CRES Manual. University of California School of Dentistry; 1989: 1-8.
- DiPrio JT, Talbert RL, Yee GC, Posey LM (eds). Pharmacotherapy, a pathophysiologic approach. New York: Loevier; 1989:642-59.
- Ericksen H. Endodontology - epidemiologic consideration. Endodont Dent Trauma 7:189, 1991.
- Kramer S. Communications regarding referrals. Risk Management Report 1(IV):4, 1989.
- Kuyk J, Walton R. Comparison of radiographic appearance of root canal size to its actual diameter. J Endodont 16:528, 1990.
- Molven O. The frequency, technical standard and results of endodontic therapy. Nor Tannlasg Tidsskr. 86:142, 1976.
- Natkin E. Bases for referral of endodontic cases. Instructional Syllabus, University of Washington, Department of Endodontics 4:43, 1976.
- Rosenberg RJ, Goodis HE. Endodontic Case Selection: To treat or to refer. J Am Dent Assoc., 1992; 123(12) 57-63.

Sarner H. Dental jurisprudence. Philadelphia: Saunders; 1963:13-21.

Scharwatt BR. The general practitioner and endodontists. Dent Clin Noth Am 23:747, 1974.

Seltzer S, Bender IB (eds). The dental pulp biologic considerations in dental practice. 3rd ed. St. Louis: Ishiyaku Euro-America; 1990:127-8.

Seltzer S, Bender IB. The Dental Pulp: Biologic Considerations in Dental Practice, 3rd ed. St. Louis, Ishiyaku Euro-America, 1990, p. 127.

Vertucci, FJ. Root canal morphology of mandibular premolars. JADA 1978;97(1):47-50.

Vertucci, FJ. Root canal anatomy of human permanent teeth. Oral Surg Oral Med Oral Pathol 1984;58(5):589-99.

Walton R, Fouad A. Endodontic inter-appointment flare-ups: A prospective study of incidence and related factors. J Endodont 18:172, 1992.

Walton R, Torabinejad M, (eds). Principles & Practice of Endo 2nd ed. Philadelphia: Saunders; 1996.