

ENDODONTICS



Colleagues for Excellence

PUBLISHED FOR THE DENTAL PROFESSIONAL COMMUNITY BY THE AMERICAN ASSOCIATION OF ENDODONTISTS

Fall/Winter 2004

Disassembly of Endodontically Treated Teeth: *The Endodontist's Perspective, Part 2*

Welcome to *ENDODONTICS: Colleagues for Excellence*...the newsletter covering the latest in endodontic treatment, research and technology. We hope you enjoy our coverage on the full scope of options available for patients through endodontic treatment and that you find this information valuable in your practice. Future issues of *ENDODONTICS* will keep you up to date on the state of the art and science in endodontic treatment.

Studies have shown that root canal treatment, when properly done, leads to healing in well over 95 percent of cases. Outcome studies vary based on different parameters, such as whether or not complete histologic healing is classified as success, or whether survivability is the definition of success. With more than 24 million endodontic procedures being performed in the United States each year, there is also a wide variation in the skill levels of treating practitioners. Some endodontically treated teeth will not heal. Thus, the challenge facing the practitioner is to remove the variables that affect (impede or impact) success. The objective of retreatment is to return the treated tooth to function and repair the supporting structures.

Reasons for nonhealing include leakage of the coronal restoration, incomplete removal of infected pulp tissue, apical leakage or fracture. Once the etiology for nonhealing has been determined, the root canal system can be retreated and the tooth restored, thereby eliminating the contributing pathologic factors. New techniques, instruments and materials have greatly enhanced the endodontist's proficiency to disassemble sophisticated restorative dentistry, as well as treat calcified canals, remove separated instruments, remove root canal filling materials and repair perforations. Modern armamentarium and techniques enable the endodontist to find canals that were previously not identified and to clean, shape and obturate the canal system in a more thorough, three-dimensional manner.

Investigations have shown that even a well-obtured root canal system can break down when bacteria are reintroduced to the

coronal portion of the tooth. Root canal filling materials do not provide an adequate biological seal when they become exposed to oral bacteria; periradicular diseases develop when microorganisms and their by-products contaminate sealed root canal spaces. An obtured root canal space can be recontaminated by recurrent decay, leakage of the restoration, loss of an interim temporary, delayed placement of a permanent restoration, contributory periodontal disease or a fracture. If a previously obtured root canal system is exposed to salivary contamination for as little as a few days, the canal system should be retreated, as the ingress of bacteria to the periradicular tissues often follows. To eliminate the potential for leakage, it is of paramount importance that an endodontically treated tooth be properly restored in a timely manner.

Indications for surgical retreatment include complex root canal anatomy, irretrievable instruments or blockages in the canal, previously retreated teeth, resorptive defects precluding three-dimensional sealing, certain types of perforations, symptomatic gross overfills and overextensions, or the need to biopsy a lesion. Many teeth will have a better prognosis if retreated nonsurgically than surgically, especially when extra canals or lateral canals are present, when perforations in the pulp chamber or coronal third of the canal system are present, and when there is persistent coronal leakage that will only be corrected with disassembly.

Since the advent of the operating microscope in endodontics in the early 1990's, the technology available for saving teeth has improved dramatically. Utilizing magnification and increased

light for visualization, endodontists can more meticulously disassemble a tooth consisting of restorations, posts and endodontic obturation materials to remove decay, eliminate leakage and check for fractures. Retreatment, or re-engineering, of the root canal system can then lead to a healthy, natural tooth that will heal and support a new restoration.

Difference Between Retreatment, Complete Disassembly and Partial Disassembly

The intent of retreatment is to eliminate any nidus of bacteria in the root canal system. The intent of disassembly is to eliminate the coronal portal of leakage. Complete disassembly of the tooth is ideal when retreatment of the root canal is being done, and involves complete removal of all restorative materials on the tooth.

There are times when partial disassembly is preferable (Figs. 1A, B and C).

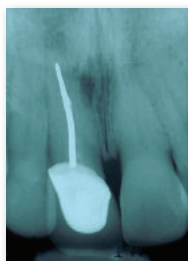


Fig. 1A: Maxillary central incisor with silver cone and lateral lesion

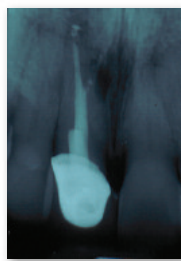


Fig. 1B: Silver cone retrieval and retreatment through palatal crown access opening

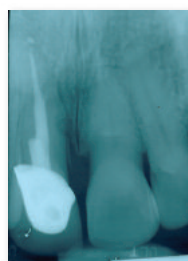


Fig. 1C: One-year postoperative image showing healing

An example is when the patient has an extensive fixed partial denture and the tooth in question does not exhibit any signs of leakage around the crown. In this instance, access can be made through the crown to remove posts and other restorative materials before retreatment of the root canal. Modern techniques utilizing the dental operative microscope, piezoelectric ultrasonic instruments and various post-removing instruments allow endodontists to gain access to the root canals without removing the prosthesis.

Post Removal

Endodontically treated teeth often contain posts. Endodontic disassembly frequently involves post removal to facilitate successful nonsurgical retreatment. Several factors should be considered for the safe and successful removal of posts.

Angulated preoperative radiographs will help determine post direction, length and diameter. In addition, radiographs can provide information regarding the root anatomy, including root concavities, remaining root wall thickness, canal shape and curvature. Identifying these factors preoperatively can minimize the risk of root fracture or perforation during the removal effort.

Post systems are generally parallel, tapered or threaded, and are comprised of precious metals, nonprecious metals or nonmetallic elements. Post cementing agents include zinc phosphate, duralon, epoxies, composite resins and glass ionomers. Threaded and bonded posts are much more difficult to safely and successfully remove. More posterior teeth with reduced interocclusal space and posts far below the occlusal surface make post removal increasingly challenging.

The removal of cemented posts has been made more predictable by the use of enhanced illumination, magnification and piezoelectric ultrasonic units matched with appropriately designed ultrasonic tips (Figs. 2A and B). Ultrasonic technology allows for the safer removal of pulp chamber dental materials, as well as the breakup of cement particles adhering to the post. In addition, these newer methods allow more tooth structure to be preserved. Aside from ultrasonic technologies, several instruments have been developed to engage a post and unscrew it, or remove it.

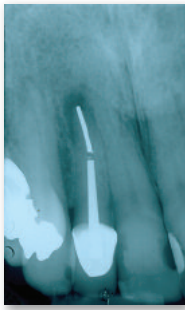

Fig. 2A: Maxillary lateral incisor with a post, sectioned silver cone and periradicular lesion

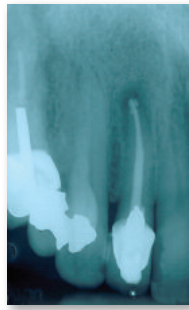


Fig. 2B: Fine, ultrasonic tips under microscopic visualization enhanced removal of these materials to facilitate retreatment

Obstructions in the Canal

Various objects can obstruct a canal and make it nonnegotiable. The most common are separated files, but obstructions can also be caused by other instruments such as broken burs, explorer tips, paste that has hardened, silver cones, restorative materials, such as amalgam, composites and resins, or even a pulp stone. Many of these obstructions can be removed with fine ultrasonic tips under microscopic visualization.

Fractured nickel-titanium instruments are more challenging to remove in that ultrasonic vibration can both heat and disintegrate the metal. When removing nickel-titanium instruments, troughing around the instrument without metal contact and minimizing heat buildup with water irrigation are important considerations. Gutta-percha, paste and cement obturation materials can be removed by a combination of mechanical, ultrasonic and chemical methods. Various solvents can soften gutta-percha and paste, and help dissolve cement.

Perforations

When a tooth is disassembled, a perforation is sometimes discovered either in the chamber or in the canal. Perforation repair is more effective and predictable when performed under the microscope. Perforations can be classified by size, location, type, amount of bone loss and length of time before repair. Larger, supracrestal, strip-type perforations with bone loss and delayed repair have the most guarded prognosis. Conversely, small, subcrestal, furcal-type perforations with little bone loss and immediate repair have the best prognosis.

Ideally, a perforation is repaired with a material that is biocompatible, can support new tissue growth, does not resorb, is radiopaque, and maintains a fluid tight seal. Restorative materials such as amalgam, composites and zinc oxide eugenol cements (IRM and SuperEBA) all require the challenge of securing a dry field in a bleeding perforation site. In addition, none of these can promote new tissue formation.

A new material, Mineral Trioxide Aggregate (MTA), has dramatically improved the prognosis for these situations. MTA is endodontic cement consisting of trioxides and other hydrophilic particles that set in the presence of moisture. As a result, MTA is distinct from other perforation sealing materials. In terms of biocompatibility, it has been demonstrated histologically that MTA can support the growth of cementum, allowing the re-establishment of the periodontal ligament. At this time, MTA is the material of choice for sealing perforations due to its biocompatibility properties, sealing ability and hydrophilic nature.

Evaluating a Tooth for Disassembly

If the treatment plan calls for a new restoration and the present endodontic treatment is deemed to be inadequate, then disassembly and retreatment should be incorporated into the plan. However, if the restoration is adequate, with no signs of leakage, but the tooth is symptomatic or has a radiolucent lesion that is increasing in size, treatment options should include retreatment with full or partial disassembly, endodontic surgery, extraction-replantation (intentional replantation) or extraction.

The clinician should consider the following when making a recommendation to the patient:

- *The restorative prognosis*
Is this tooth strategically necessary for the patient's dentition? In a complex treatment plan, other dentists and specialists may need to be consulted. Is this tooth restorable? Will there be enough remaining tooth structure to have a ferrule on the crown preparation?
- *The periodontal prognosis*
Is the periodontal support around this tooth adequate? Will crown lengthening procedures be necessary? The crown-root ratio, pocket depths and mobility should be evaluated.
- *The skill of the clinician*
Does the clinician have the training and skill to

disassemble this tooth? Does the clinician have the training and skill to find and treat additional canals, treat perforations, negotiate ledges, remove old endodontic filling materials and blockages such as files?

- *Available technology*

Does the clinician have the optical magnification with enhanced illumination, ultrasonics and specialized instruments that may be needed?

- *The patient's desires*

Is this patient motivated to save the tooth? What is the patient's oral hygiene, age and remaining dentition? The patient should be the one to make the final decision after being fully informed of the risks, costs and benefits of all options.

Conclusion

Today, patients expect to keep their teeth for a lifetime. With new knowledge and technology, we are able to keep many teeth that in the past would have been extracted and possibly replaced with an implant or a fixed or removal partial denture. When we encounter previously treated teeth that are not healing, we now have the knowledge and technology to disassemble and retreat them with a very high rate of success. Discussing this option with your endodontic specialist and communicating this option to your patients can result in the more frequent preservation of natural teeth.

The AAE Public and Professional Affairs Committee and the Board of Directors developed this issue with special thanks to the co-authors, Drs. Samuel O. Dorn and Les H. Kravitz, and reviewer, Dr Tanya Machnick.

The information in this newsletter is designed to aid dentists. Practitioners must use their best professional judgment, taking into account the needs of each individual patient when making diagnoses/treatment plans. The AAE neither expressly nor implicitly warrants any positive results, nor expressly nor implicitly warrants against any negative results, associated with the application of this information. If you would like more information, call your endodontic colleague or contact the AAE.

Did you enjoy this issue of *ENDODONTICS*? Did the information have a positive impact on your practice? Are there topics you would like *ENDODONTICS* to cover in the future? We want to hear from you! Send your comments and questions to the American Association of Endodontists at the address below.



ENDODONTICS: *Colleagues for Excellence*

American Association of Endodontists
211 E. Chicago Ave., Suite 1100
Chicago, IL 60611-2691
www.aae.org