

Efficacy of Articaine versus Lidocaine as a Supplemental Buccal Infiltration in Mandibular Molars with Irreversible Pulpitis: A Prospective, Randomized, Double-blind Study

Brandon S. Rogers, DDS, MS, Tatiana M. Botero, DDS, MS, Neville J. McDonald, BDS, MS, Richard J. Gardner, DDS, MS, and Mathilde C. Peters, DMD, PhD

Abstract

Introduction: Profound pulpal anesthesia in mandibular molars with irreversible pulpitis (IP) is often difficult to obtain and often requires supplemental injections after an ineffective inferior alveolar nerve block (IANB). The purpose of this prospective, randomized, double-blind study was to compare the efficacy of 4% articaine with 2% lidocaine for supplemental buccal infiltrations (BIs) after an ineffective IANB in mandibular molars with IP. In addition, the use of articaine for IANB and intraosseous injections was investigated. **Methods:** One hundred emergency patients diagnosed with IP of a mandibular molar were selected and received an IANB with 4% articaine. All injections were 1.7 mL with 1:100,000 epinephrine. All patients reported profound lip numbness after IANB. Patients with ineffective IANB (positive pulpal response to cold or pain on access) randomly received 4% articaine or 2% lidocaine as a supplemental BI. Endodontic access was initiated 5 minutes after deposition of the infiltration solution. Success was defined as no pain or no more than mild pain during endodontic access and instrumentation as measured on a visual analogue scale. **Results:** Seventy-four patients failed to achieve pulpal anesthesia after IANB with 4% articaine, resulting in IANB success rate of 26%. Success rates for supplemental BIs were 62% for articaine and 37% for lidocaine ($P < .05$). This effect was most pronounced in second molars ($P < .05$). **Conclusions:** Supplemental BI with articaine was significantly more effective than lidocaine. The IANB success rate of 4% articaine confirmed published data. (*J Endod* 2014;40:753–758)

Key Words

Articaine, IANB, infiltration, irreversible pulpitis, lidocaine

From the Department of Cariology, Restorative Sciences, and Endodontics, University of Michigan School of Dentistry, Ann Arbor, Michigan.

Address requests for reprints to Dr Mathilde C. Peters, Department of Cariology, Restorative Sciences, and Endodontics, School of Dentistry, University of Michigan, 1011 N University, Room 2391, Ann Arbor, MI 48109-1078. E-mail address: mcpete@umich.edu
0099-2399/\$ - see front matter

Copyright © 2014 American Association of Endodontists.
<http://dx.doi.org/10.1016/j.joen.2013.12.022>

Achieving complete pulpal anesthesia in teeth diagnosed with irreversible pulpitis (IP) is often difficult (1). Numerous clinical trials spanning the previous 2 decades have studied anesthetic success in teeth with IP (1–17). Most previous studies investigated anesthesia of mandibular posterior IP teeth by using the inferior alveolar nerve block (IANB) (2–4) and supplementary techniques after IANB failure (5–12).

A correctly administered IANB does not always result in successful pulpal anesthesia in IP molars. After an unsuccessful IANB injection, the clinician has several options by using the same or a different anesthetic: an additional volume could be given via the same or a different IANB technique (eg, Gow Gates or Akinosi) or via a supplemental technique (infiltration, intraosseous [IO], or intrapulpal).

In healthy mandibular molars, a supplemental buccal infiltration (BI) with 4% articaine after IANB increased pulpal anesthetic success by 17%–36% (18, 19). A recent meta-analysis (including studies with healthy and IP teeth) concluded that articaine was 3.8 times more effective as an infiltration than lidocaine (20). One of these clinical trials combined IANB of 2% lidocaine solution with 4% articaine as a supplemental BI of mandibular posterior IP teeth (6). The initial IANB injection with 2% lidocaine was 30% successful in mandibular IP molars. The 70% failed IANB molars received BI of 4% articaine, resulting in an additional 53% of cases with pulpal anesthesia. Until recently, no study compared articaine with lidocaine in supplemental BIs in mandibular IP molars.

A matched IANB and BI solution (either articaine or lidocaine for both injections) demonstrated the articaine combination (71%) to be superior to lidocaine (29%) (5). Even though articaine does not show greater efficacy as IANB in IP teeth (2, 4), it was more effective as IANB in healthy posterior teeth (20), and the IANB solution could potentially play a role in the overall outcome. In maxillary IP teeth, lidocaine and articaine were equally effective (13).

Clinical studies are lacking that evaluate the efficacy of different solutions for supplemental BI as the only variable in mandibular IP molars after a failed IANB by using articaine. The primary purpose of this prospective, double-blind, randomized, controlled clinical trial was to compare the efficacy of a supplemental BI of either 4% articaine or 2% lidocaine after an unsuccessful IANB with articaine in mandibular molars with IP. In addition, the incidence of unsuccessful IANB and successful IO injections was evaluated.

Methods

One hundred one adult patients (18 years or older) of record at the University of Michigan School of Dentistry participated in this trial. Institutional Review Board approval was obtained, and each patient signed informed consent. Patients with allergies to local anesthetics or sulfites, significant medical conditions, taking any medications that might affect anesthetic assessment, or with inability to give informed consent were excluded.

To qualify for the study, patients presented with a vital mandibular permanent molar, with fully formed roots (confirmed by periapical radiograph), who were experiencing greater than moderate pain and spontaneous and prolonged response to cold testing with Endo-Ice (1,1,1,2 tetrafluoroethane; Hygenic Corp, Akron, OH). Patients

CONSORT Randomized Clinical Trial

with delayed or no response to cold testing, periradicular pathosis (other than a widened periodontal ligament), or no vital coronal pulp tissue on access were excluded from the study. Thus, every patient had a mandibular molar that fulfilled the criteria of symptomatic IP (21). In addition, periapical diagnosis was recorded (normal or symptomatic apical periodontitis).

Patients rated their pretreatment, post-injection, and intra-treatment pain on a Heft-Parker Visual Analogue Scale (VAS) by touching an iPad (Apple Inc, Cupertino, CA) screen showing a labeled VAS pain scale with full set of pain descriptors. In this study the VAS data collection was divided into 4 categories as previously described. No pain corresponded to 0 mm. Mild pain was defined as >0 mm and ≤54 mm, which included the descriptors of faint, weak, and mild pain. Moderate pain was defined as >54 mm but <114 mm. Severe pain was defined as any score >114 mm that included the descriptors of strong, intense, and maximum possible (2, 5–7, 14, 15, 18, 22).

Figure 1 presents the flow diagram of study events. The 101 enrolled patients received 1.7 mL 4% articaine with 1:100,000 epinephrine (Articadent; Dentsply Pharmaceutical, York, PA) by using a conventional IANB injection after a 60-second application of topical anesthetic gel (20% benzocaine; Centrix, Shelton, CT). The block was administered with a 27-gauge, long (32 mm) needle (Monoject; Tyco Healthcare Group LP, Mansfield, MA) inserted slightly laterally at the middle portion of pterygomandibular raphe to contact bone, with the needle bevel directed toward the bone, slightly withdrawn, and aspirated, and solution was deposited with the Midwest Comfort Control syringe (Dentsply Professional, Des Plaines, IL) by selecting “block” injection speed at a rate of 0.020 mL/s.

At 15 minutes after injection, the patient was questioned regarding lip numbness. If profound lip numbness was not reported, the block was considered missed, and the patient was transferred out of the study. If lip numbness was reported, the diagnosed symptomatic IP molar as well as the nearest molar and premolar were cold-tested. A positive cold response on the IP molar was considered a failed IANB, and the patient received a randomly assigned supplemental BI. If negative to cold, the

tooth was isolated with a rubber dam, and endodontic access was initiated. During the access, patients were instructed to report any discomfort. Success was defined as the ability to access and instrument the tooth with no pain or no more than mild pain (VAS rating ≤ 54 mm). Pain beyond our success criteria was considered a failed IANB, and the patient was randomized to the supplemental BI group.

The 1.7-mL articaine carpules (Articadent) and 1.7-mL lidocaine carpules (Henry Schein, Dentsply Pharmaceutical, York, PA) were subjected to block randomization (Urbaniak and Plous, Research Randomizer 3.0, 2011). All injections were given by a single operator (B.R.). Randomized numbered carpules were used to mask both operator and patients to the anesthetic solution. After a failed block (lip numbness with a positive response to cold or greater than mild pain on access), the assigned carpule was placed into the Midwest Comfort Control syringe with the “infiltration” selection. Topical gel was placed for 60 seconds. A supplemental BI injection was given adjacent to the IP molar, bisecting the approximate location of the mesial and distal roots at the mucobuccal fold. The needle was advanced to estimated depth just superior to the apices of the mandibular molar, and solution was deposited at a rate of 0.017 mL/s.

At 5 minutes after injection, the tooth was again cold-tested, recording the infiltration result by using the same success criteria. Rescue anesthesia, which was provided to all failures, consisted of an IO injection by using the X-tip system (Dentsply International) per the manufacturer’s recommendations. The Midwest Comfort Control syringe was used on the “intraosseous” selection at a rate of 0.020 mL/s with 1.7 mL 4% articaine with 1:100,000 epinephrine. If the X-tip was contraindicated (eg, root proximity), an intrapulpal or periodontal ligament injection was given. Otherwise, distal to the mandibular first molar served as the X-tip injection site for both first and second inflamed molars (12). Intrapulpal anesthesia was given as needed to any patient with anesthesia failure after the IO injection with articaine.

A previous infiltration study (23) was used to calculate 80% power by using SPSS version 16.0 (SPSS Inc, Chicago, IL), and sample size was

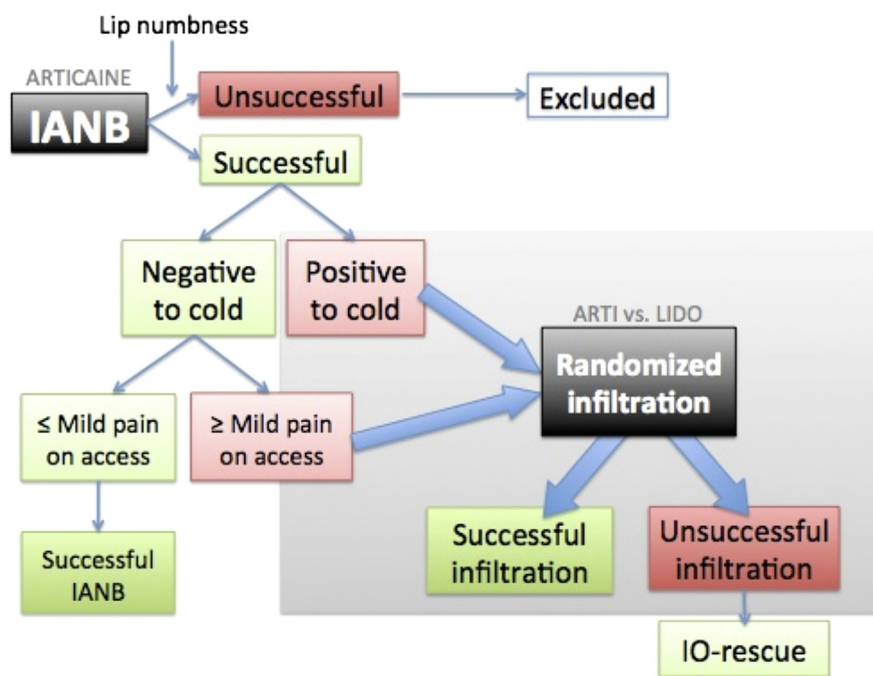


Figure 1. Study flow chart.

adjusted by 24% to account for expected successful IANB administrations (2). Our power analysis required 100 total patients with adequate lip numbness. All patient data were entered into an online data input and management system (Snapdragon Media, LLC, Ann Arbor, MI) by using an Apple iPad 2 (Apple Inc) and statistically analyzed. Comparative effectiveness data for articaine and lidocaine solutions were analyzed by using the χ^2 test. Comparisons were considered significant if $P < .05$.

Results

One hundred one mandibular IP molars were tested; one showed inadequate lip numbness, and 26 IANB injections were successful, resulting in 74 teeth being randomized for supplemental BI (Fig. 2).

The age, gender, tooth type, and initial pain level were not statistically different ($P > .05$) between the various patient groups (Table 1).

In addition, patients in both randomized groups experienced similar mean pain levels at each injection phase from preoperative pain status to IO injection, if given ($P > .05$, Table 2). The study included 69 teeth with symptomatic apical periodontitis (69%), ranging from 62%–79% ($P > .05$) for the various groups (successful IANB, articaine BI, lidocaine BI, and rescue groups). Even with profound pulpal anesthesia (successful IANB) some patients may still experience minor pain sensation. Six successful IANB patients (23%) experienced no more than mild pain on access (mean VAS, weak pain). Both articaine and lidocaine BI groups had 8% success, with a mean VAS of faint-weak pain. None of the successful rescue injections reported any pain.

Table 3 shows success rates and group characteristics of the overall and randomized supplemental BI groups. Articaine showed a significantly higher success rate of 62% compared with 37% for lidocaine ($P = .036$). Although the gender distribution in the overall successful BI group showed no difference (male 52% versus female 49%), the BI administration of articaine in male patients was twice as successful (65%) compared with the lidocaine BI (33%). The difference in anesthetic solution was less notable in female patients. However, neither of these differences was significant ($P > .05$). The study included 35

mandibular first molars, 38 mandibular second molars, and 1 mandibular third molar showing success rates of 57%, 42%, and 100%, respectively. More specifically, 61% of mandibular first molars were successful with articaine and 53% with lidocaine ($P > .05$). However, comparing mandibular second molars, articaine (62%) achieved significantly greater success compared with lidocaine (18%, $P = .006$) (Table 4).

Of the 37 infiltration failures, 2 were contraindicated for IO injection because of inadequate bone width between adjacent roots. Thirty-one of the remaining 35 (89%) were successfully anesthetized by using the X-tip IO system with 4% articaine. The 4 failures were successfully debrided without pain after an intrapulpal injection. The Comfort Control syringe was successfully used in the clinical protocol to achieve optimal standardization. The controlled injection method was not further evaluated in this study.

Three modes of clinical testing were used to confirm the efficacy of anesthesia administered at different injection phases. The correlation between a negative cold test and subsequent successful access and instrumentation was only 49% for IANB, 89% for articaine BI, 57% for lidocaine BI, and 89% for IO injections.

Fourteen percent of patients reported no medication history. The majority of patients, 44%, reported taking an over-the-counter analgesic such as ibuprofen or acetaminophen. The next most prevalent group (28%) took an over-the-counter analgesic combined with a narcotic or controlled substance such as hydrocodone. A combination of medications including an antibiotic was taken less frequently (14%).

Discussion

This investigation aimed to find the best supplemental BI strategy after a failed IANB in symptomatic mandibular molars diagnosed with IP. In addition, we reported the success rate of the IANB (1 carpule of 4% articaine, 1:100,000 epinephrine) and the IO rescue injections given. The supplemental infiltrations included 1 carpule of 4% articaine or 2% lidocaine with 1:100,000 epinephrine. The rescue anesthesia after a failed supplemental technique was an IO injection with 1 carpule of 4%

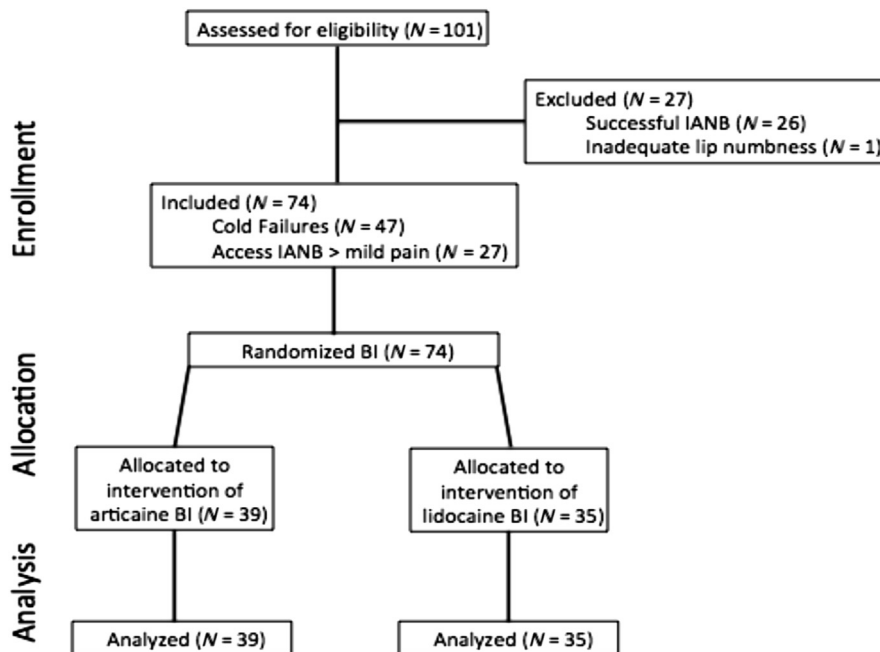


Figure 2. CONSORT flow chart.

CONSORT Randomized Clinical Trial

TABLE 1. Patient/Tooth Characteristics in IANB and BI Groups

| | IANB (4% articaine) | | BI | | |
|--|---------------------|---------------------------------|------------------|-----------------------|-----------------------|
| | Overall (n = 100) | Successful access test (n = 26) | Overall (n = 74) | 4% Articaine (n = 39) | 2% Lidocaine (n = 35) |
| Mean age ± standard deviation (y) | 38 ± 14 | 43 ± 16 | 36 ± 13 | 36 ± 14 | 36 ± 12 |
| Gender (n, %) | | | | | |
| Male | 43 (43) | 14 (54) | 29 (39) | 17 (44) | 12 (34) |
| Female | 57 (57) | 12 (46) | 45 (61) | 22 (56) | 23 (66) |
| Tooth type (n, %) | | | | | |
| First molar | 47 (47) | 12 (46) | 35 (47)* | 18 (46) | 17 (49)* |
| Second molar | 52 (52) | 14 (54) | 38 (51)* | 21 (54) | 17 (49)* |
| Third molar | 1 (1) | — | 1 (1)* | — | 1 (3)* |
| Mean initial VAS score ± standard deviation (mm) | | | | | |
| Total (mean VAS) | 132 ± 27 | 133 ± 25 | 131 ± 27 | 131 ± 28 | 131 ± 28 |
| Gender (mean VAS) | | | | | |
| Male | 130 ± 30 | 133 ± 26 | 129 ± 32 | 134 ± 27 | 121 ± 37 |
| Female | 133 ± 24 | 133 ± 26 | 133 ± 24 | 128 ± 28 | 137 ± 20 |
| Tooth type (mean VAS) | | | | | |
| First molar | 138 ± 22 | 132 ± 25 | 139 ± 21 | 137 ± 27 | 142 ± 12 |
| Second molar | 127 ± 29 | 133 ± 27 | 125 ± 30 | 126 ± 28 | 123 ± 34 |
| Third molar | 85 | — | 85 | — | 85 |

*Rounding to nearest whole number ≠ 100%.

articaine by using the X-tip system. Here we found that supplemental infiltration with 4% articaine was significantly more effective than lidocaine.

The patients' age, gender, tooth type, and initial pain were not significantly different between groups at the start of the study (IANB), for the supplemental BI, and for each of the 2 randomized anesthetic solutions (BI with articaine or lidocaine). Therefore, the effect of the variables age, gender, tooth type, and initial pain on the results of this study was expected to be minimal. The mean initial pain rating of VAS = 132 mm correlates to severe pain and was the same for patients in the articaine and lidocaine groups. This pain is representative of patients with a symptomatic IP (12, 14, 16) who present for emergency treatment.

Articaine was selected as IANB anesthetic to augment information to the limited data available compared with lidocaine about the success rate of articaine IANB in mandibular IP molars. The IANB success rate in posterior IP teeth showed no difference between articaine and lidocaine (2, 4, 20). An IANB success rate of 24% (2) was used to adjust our sample size to obtain a power of 80% at 95% confidence interval in the 2 randomized infiltration treatment groups.

Variation in the IANB injection speed can produce a significantly different outcome (24). Therefore, all study injections were standardized by using the Midwest Comfort Control syringe. This digitally

controlled injection system was used at the recommended standardized injection rate of 0.020 mL/s for the “block” and “intraosseous” and 0.017 mL/s for supplementary “infiltration” injection.

Lip numbness, the clinical indicator of a successful block, is not a guaranteed sign of successful pulpal anesthesia (2, 4–6, 12, 14, 16, 22). In addition, pulp tests (electric pulp tester and Endo-Ice) showed poor reliability because 80% of mandibular IP teeth with negative response after IANB required supplemental injection (12). Omitting pulp tests, recent studies used pulpal access to determine success (5, 6). There is a lack of data about the reliability of a cold test in IP-diagnosed molars after articaine IANB and supplemental BI. Therefore, we elected to use the following pulp testing strategy before access. After IANB, if either adjacent tooth was positive to cold, excluding the IP-diagnosed tooth, the block was considered missed and not a failure. Resulting IANB pulp-tested failures were confined solely to the IP-diagnosed molars. To our knowledge, there are no published data validating the IANB success, or differentiating a missed IANB from an otherwise unsuccessful IANB in mandibular IP molars, by verifying a negative cold response on the nearest vital molar and premolar.

The IANB success rate in our present study was 26%, an outcome anticipated from literature data about mandibular IP molars after 1

TABLE 2. Mean VAS Pain Rating for 4% Articaine and 2% Lidocaine for Each Injection Phase (n = 74)

| Injection phase | Test phase | Mean VAS | | | |
|-------------------|-----------------|--------------------|---------------------------|--------------------|---------------------------|
| | | Articaine (n = 39) | | Lidocaine (n = 35) | |
| | | n | ± standard deviation (mm) | n | ± standard deviation (mm) |
| Preoperative IANB | Preinjection | 39 | 131 ± 28 | 35 | 131 ± 28 |
| | Injection | 39 | 64 ± 38 | 35 | 62 ± 36 |
| | Access | 14 | 84 ± 13 | 13 | 105 ± 28 |
| BI | Injection* | 39 | 64 ± 46 | 35 | 66 ± 47 |
| | Access | 27 | 12 ± 28 | 23 | 42 ± 50 |
| | Access failures | 3 | 85 ± 15 | 10 | 95 ± 25 |
| IO | Injection* | 15 | 19 ± 40 | 20 | 2 ± 8 |
| | Access | 15 | 10 ± 37 | 20 | 10 ± 26 |
| | Access failures | 1 | 144 | 3 | 70 ± 0 |

*Includes cold and access failures.

TABLE 3. Success Rate and Patient/Tooth Characteristics in Successful Supplemental BI Groups after Failed IANB (*n* = 37)

| | Overall BI (<i>n</i> = 74) | Articaine (<i>n</i> = 39) | Lidocaine (<i>n</i> = 35) | <i>P</i> value |
|-------------------------------|-----------------------------|----------------------------|----------------------------|-------------------|
| | <i>n</i> (%) | <i>n</i> (%) | <i>n</i> (%) | |
| BI success | 37 (50) | 24* (62) | 13* (37) | .036* |
| Gender | | | | |
| Male (<i>n</i> = 29) | 15 (52) | 11/17 (65) | 4/12 (33) | .096 |
| Female (<i>n</i> = 45) | 22 (49) | 13/22 (59) | 9/23 (39) | .181 |
| Tooth type | | | | |
| First molar (<i>n</i> = 35) | 20 (57) | 11/18 (61) | 9/17 (53) | .625 |
| Second molar (<i>n</i> = 38) | 16 (42) | 13/21 [†] (62) | 3/17 [†] (18) | .006 [†] |
| Third molar (<i>n</i> = 1) | 1 (100) | — | 1/1 (100) | — |

*Significant difference, IANB.

[†]Significant difference, BI.

carpule of anesthetic (2, 5, 6, 12). The primary outcome of our study indicated that a supplemental BI of articaine (62%) was superior to lidocaine (37%, *P* = .036). The 62% success rate for articaine supplemental BI anesthesia in mandibular IP molars is within the expected range and between data reported by Matthews et al (6) (53%) and Ashraf et al (5) (71%). The lidocaine BI outcome (37%) is higher than the value reported by Ashraf et al (29%), who combined IANB and supplemental BI by using either lidocaine or articaine. In our study, we always used articaine IANB before randomizing the BI administration. The difference in the starting IANB anesthetic solution may have continued to affect the lidocaine outcomes in the 2 studies. Kanaa et al (10) reported pulp extirpation success rates in mandibular IP molars supplemented with 4 different techniques after a failed 2.0 mL 2% lidocaine (1:80,000 epinephrine) IANB. The techniques and success rates included 2 mL 4% articaine supplemental BI (85%), 1 mL 2% lidocaine IO (73%) after 0.2 mL for soft tissue, 2 mL repeat lidocaine IANB (43%), and 0.18 mL lidocaine periodontal ligament per root (38%). The increase in the articaine supplemental BI success rate compared with our study could potentially be due to the 15%–20% increase in volume of anesthetic used in both injections (IANB and supplemental BI). Supplemental infiltrations on the lingual side were not included in the present study protocol to minimize the number of variables and because in healthy molars the difference in efficacy of articaine infiltration between buccal-only (64.5%) and two-sided (67.7%) administration was minimal (25).

In male patients, twice as many articaine BI administrations (65%) were effective when compared with lidocaine BI (33%), with only a 20% difference in female patients. There was no statistical difference in either group (*P* > .05). Simonton et al (26) studied gender differences in anatomic distance for IAN and buccal plate to root apices. Female patients had significantly shorter vertical distances in all dimensions in the mandibular first molars. This shorter vertical and horizontal bone distance to the deposited solution in female patients could obscure a potential difference in penetration efficiency between articaine and lidocaine solutions.

Interestingly, articaine as supplemental BI maintained a similar success rate of 62% for mandibular second molars as it did for first molars. The success rate of lidocaine dropped from 53% in first molars to only 18% in second molars. This difference was significant (*P* = .006). We speculate that the greater bone diffusion of articaine (27) compared with lidocaine results in faster and deeper pulpal anesthesia for second mandibular molars. An anatomic study showed the mean horizontal distance from the mesial root apex to the buccal cortical plate for the second molar to be significantly greater than for the first molar (28). This difference in bone thickness and distance to root apices is a likely explanation for the poor lidocaine BI success. On the contrary, articaine, which was shown to be 3.8 times more effective as an infiltration in general (20), could maintain similar success for all mandibular IP molars.

The present study used the X-tip IO system as rescue anesthesia protocol. Intrapulpal rescue anesthesia would have been only useful in cases with exposed pulps, leaving 32% of teeth failing the cold test after the supplemental BI without profound anesthesia. Soft tissue anesthesia resulting from the supplemental BI reduced the discomfort and aided the IO rescue. After a failed supplemental BI, the IO rescue injections in this study produced an 89% success rate. All 4 failures of the IO were access failures during actual pulp extirpation and were easily anesthetized by using an intrapulpal injection. This IO rescue injection result corroborates the 79%–98% previously reported outcomes for IP teeth (10, 12, 15–17). Interestingly, 75% of the IO failures were in the lidocaine supplemental BI group, and 75% were mandibular second molars.

The cold test was used throughout all injection phases in this study. Articaine and lidocaine supplemental BI resulted in a similarly negative response to cold; however, 89% of infiltrations with articaine were actually successful compared with only 57% with lidocaine. Lidocaine seemed to produce enough pulpal anesthesia to achieve a negative cold test similar to articaine but was unable to achieve a similar success rate for profound pulpal anesthesia. The IO articaine injection produced a 100% negative response to cold but had the same rate of 89% of pulpal anesthesia on access as the supplemental articaine BI. Even though the cold test is not 100% at predicting complete pulpal anesthesia on access (12), it will allow the clinician, after any positive cold test, to give a supplemental injection with a high chance of profound pulpal anesthesia. By using preexisting armamentarium, the cold test appeared to be a simple and efficient aid for optimizing anesthetic success.

The present study included a random population of patients with IP who would present for emergency treatment. Potential variables in their medication history were not controlled because this was outside the aims of this study.

TABLE 4. Clinical Testing Mode and Success Rate per Injection Phase

| Injection phase | Test mode | Success rate | |
|-----------------|--------------------------------|--------------|-----|
| | | <i>n</i> | % |
| IANB | Lip numbness (<i>n</i> = 100) | 100 | 100 |
| | Cold (<i>n</i> = 100) | 53 | 53 |
| | Access (<i>n</i> = 53) | 26 | 49 |
| BI | Cold (<i>n</i> = 74) | 50 | 68 |
| | Access (<i>n</i> = 50) | 37 | 74 |
| ABI | Cold (<i>n</i> = 39) | 27 | 69 |
| ABI | Access (<i>n</i> = 27) | 24 | 89 |
| LBI | Cold (<i>n</i> = 35) | 23 | 66 |
| | Access (<i>n</i> = 23) | 13 | 57 |
| IO | Cold (<i>n</i> = 35) | 35 | 100 |
| | Access (<i>n</i> = 35) | 31 | 89 |

ABI, articaine buccal infiltration; LBI, lidocaine buccal infiltration.

Paresthesia, a persistent anesthesia, or altered sensation (tingling or itching) well beyond the expected duration of anesthesia (29) has been suggested as a risk when articaine is used for IANB injection. There was no incidence of paresthesia or any other side effect reported in our study (140 articaine injections). Our data confirmed reported safety of articaine in IANB and supplemental BI and IO administrations (30).

In conclusion, for mandibular molars with IP, the IANB success rate after 1 carpule of 4% articaine with 1:100,000 epinephrine was comparable to previous reports for 2% lidocaine IANB. As a supplemental BI, 4% articaine was significantly more effective than 2% lidocaine. The superiority of articaine was most evident in second molars. Cold testing should be used before access in mandibular IP molars and is a reliable indicator of pulpal anesthesia after a 4% articaine supplemental BI.

Acknowledgments

Supported by Dentsply Pharmaceutical providing materials and supplies and by the Endodontic Graduate Student Research fund, School of Dentistry (University of Michigan).

The authors thank Thomas Braun, PhD, for his statistical assistance. This article was adapted from a thesis submitted by Brandon Rogers in partial fulfillment of the requirements for the MS degree at the University of Michigan.

The authors deny any conflicts of interest related to this study.

References

- Nusstein JM, Reader A, Drum M. Local anesthesia strategies for the patient with a "hot" tooth. *Dent Clin North Am* 2010;54:237–47.
- Claffey E, Reader A, Nusstein J, et al. Anesthetic efficacy of articaine for inferior alveolar nerve blocks in patients with irreversible pulpitis. *J Endod* 2004;30:568–71.
- Sampaio RM, Carnaval TG, Lanfredi CB, et al. Comparison of the anesthetic efficacy between bupivacaine and lidocaine in patients with irreversible pulpitis of mandibular molar. *J Endod* 2012;38:594–7.
- Tortamano IP, Siviero M, Costa CG, et al. A comparison of the anesthetic efficacy of articaine and lidocaine in patients with irreversible pulpitis. *J Endod* 2009;35:165–8.
- Ashraf H, Kazem M, Dianat O, Noghrehkar F. Efficacy of articaine versus lidocaine in block and infiltration anesthesia administered in teeth with irreversible pulpitis: a prospective, randomized, double-blind study. *J Endod* 2013;39:6–10.
- Mathews R, Drum M, Reader A, et al. Articaine for supplemental buccal mandibular infiltration anesthesia in patients with irreversible pulpitis when the inferior alveolar nerve block fails. *J Endod* 2009;35:343–6.
- Aggarwal V, Jain A, Kabi D. Anesthetic efficacy of supplemental buccal and lingual infiltrations of articaine and lidocaine after an inferior alveolar nerve block in patients with irreversible pulpitis. *J Endod* 2009;35:925–9.
- Dreven LJ, Reader A, Beck M, et al. An evaluation of an electric pulp tester as a measure of analgesia in human vital teeth. *J Endod* 1987;13:233–8.
- Fan S, Chen WL, Pan CB, et al. Anesthetic efficacy of inferior alveolar nerve block plus buccal infiltration or periodontal ligament injections with articaine in patients with irreversible pulpitis in the mandibular first molar. *Oral Surg Oral Med Oral Pathol Oral Radiol Endod* 2009;108:e89–93.
- Kanaa MD, Whitworth JM, Meechan JG. A prospective randomized trial of different supplementary local anesthetic techniques after failure of inferior alveolar nerve block in patients with irreversible pulpitis in mandibular teeth. *J Endod* 2012;38:421–5.
- Nusstein J, Claffey E, Reader A, et al. Anesthetic effectiveness of the supplemental intraligamentary injection, administered with a computer-controlled local anesthetic delivery system, in patients with irreversible pulpitis. *J Endod* 2005;31:354–8.
- Nusstein J, Reader A, Nist R, et al. Anesthetic efficacy of the supplemental intraosseous injection of 2% lidocaine with 1:100,000 epinephrine in irreversible pulpitis. *J Endod* 1998;24:487–91.
- Kanaa MD, Whitworth JM, Meechan JG. A comparison of the efficacy of 4% articaine with 1:100,000 epinephrine and 2% lidocaine with 1:80,000 epinephrine in achieving pulpal anesthesia in maxillary teeth with irreversible pulpitis. *J Endod* 2012;38:279–82.
- Kennedy S, Reader A, Nusstein J, et al. The significance of needle deflection in success of the inferior alveolar nerve block in patients with irreversible pulpitis. *J Endod* 2003;29:630–3.
- Nusstein J, Kennedy S, Reader A, et al. Anesthetic efficacy of the supplemental X-tip intraosseous injection in patients with irreversible pulpitis. *J Endod* 2003;29:724–8.
- Reisman D, Reader A, Nist R, et al. Anesthetic efficacy of the supplemental intraosseous injection of 3% mepivacaine in irreversible pulpitis. *Oral Surg Oral Med Oral Pathol Oral Radiol Endod* 1997;84:676–82.
- Parente SA, Anderson RW, Herman WW, et al. Anesthetic efficacy of the supplemental intraosseous injection for teeth with irreversible pulpitis. *J Endod* 1998;24:826–8.
- Haase A, Reader A, Nusstein J, et al. Comparing anesthetic efficacy of articaine versus lidocaine as a supplemental buccal infiltration of the mandibular first molar after an inferior alveolar nerve block. *J Am Dent Assoc* 2008;139:1228–35.
- Kanaa MD, Whitworth JM, Corbett IP, Meechan JG. Articaine buccal infiltration enhances the effectiveness of lidocaine inferior alveolar nerve block. *Int Endod J* 2009;42:238–46.
- Brandt R, Anderson P, McDonald N, et al. The pulpal anesthetic efficacy of articaine versus lidocaine in dentistry: a meta-analysis. *J Am Dent Assoc* 2011;142:493–504.
- American Association of Endodontists. *Endodontic Glossary*. Chicago, IL: American Association of Endodontists; 2012.
- Mikesell P, Nusstein J, Reader A, et al. A comparison of articaine and lidocaine for inferior alveolar nerve blocks. *J Endod* 2005;31:265–70.
- Robertson D, Nusstein J, Reader A, et al. The anesthetic efficacy of articaine in buccal infiltration of mandibular posterior teeth. *J Am Dent Assoc* 2007;138:1104–12.
- Kanaa M, Meechan J, Corbett I, Whitworth J. Speed of injection influences efficacy of inferior alveolar nerve blocks: a double-blind randomized controlled trial in volunteers. *J Endod* 2006;32:919–23.
- Corbett I, Kanaa M, Whitworth J, Meechan J. Articaine infiltration for anesthesia of mandibular first molars. *J Endod* 2008;34:514–8.
- Simonton JD, Azevedo B, Schindler WG, Hargreaves KM. Age- and gender-related differences in the position of the inferior alveolar nerve by using cone beam computed tomography. *J Endod* 2009;35:944–9.
- Vree TB, Gielen MJ. Clinical pharmacology and the use of articaine for local and regional anaesthesia. *Clin Anaesth* 2005;19:293–308.
- Frankle KT, Seibel W, Dumsha TC. Anatomical study of the position of the mesial roots of mandibular molars. *J Endod* 1990;16:480–5.
- Malamed SF. *Handbook of Local Anesthesia*. St Louis: CV Mosby; 1997.
- Katyal V. The efficacy and safety of articaine versus lignocaine in dental treatments: a meta-analysis. *J Dent* 2010;38:307–17.