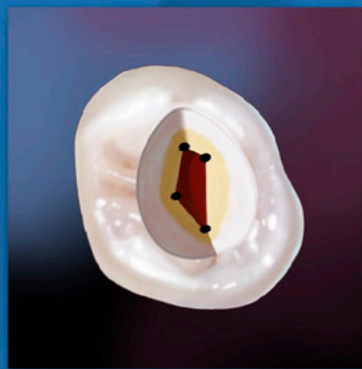


ENDODONTICS



*Colleagues for
Excellence*

Spring 2010

Access Opening and Canal Location



Published for the Dental Professional Community by the
American Association of Endodontists

The endodontic triad consisting of biomechanical preparation, microbial control and complete obturation of the canal space remains the basis of endodontic therapy.¹ However, unless access to the canal orifices and the apical foramina are done properly, achieving the goals of the triad will be difficult and time consuming. The ultimate goal of endodontic treatment is to create an environment in which the body can heal itself. Adequate access is the key to achieving this and, therefore, the key to achieving endodontic success. The purpose of this newsletter is to help the practitioner develop an understanding of how to access the pulp chamber and find the orifices of the root canals. To do so, a systematic method for accessing the pulp complex and locating root canal orifices is presented.

Basic Concepts

The pulp complex should be conceptualized as a continuum beginning occlusally at the pulp horns and ending at the apical foramina.¹ In order to remove pulp tissue entirely from the pulp complex, the coronal portion of the complex must be accessed in a manner that will permit pulp removal and facilitate the location and debridement of the root canals without compromising the strength of the coronal enamel and dentin.

This process of cleaning and shaping the pulp complex can be broken down into four stages—pre-access analysis, removal of the pulp chamber roof, identification of the pulp chamber and floor root canal orifices, and instrumentation of the root canals.

Pre-Access Analysis

Removal of the pulp tissue begins with an analysis of the anatomy of the tooth being treated and the anatomy of the surrounding tissues.

In order to remove the contents of the root canal system, the coronal portion of the system, the pulp chamber and the radicular pulp must be identified. According to Krasner and Rankow², the pulp chamber of every tooth is in the center of the tooth at the level of the cementoenamel junction; they described this as “The Law of Centrality.” The validity of this law can be seen in Figures 1a and 1b.

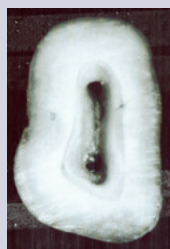

Fig. 1a.

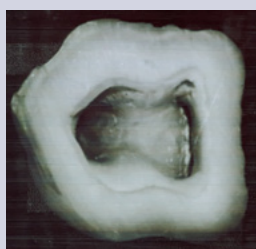


Fig. 1b.

Cut specimens showing Law of Centrality.

The Law of Centrality can be used as a guide for the beginning of access. However, it is critical that the operator understand that the law is consistently true only at the level of the CEJ and unrelated to the occlusal anatomy.²

Since we know that the pulp chamber is always in the center of the tooth at the level of the CEJ, the initial penetrating bur should be directed towards the center of the CEJ. Therefore, in a counterintuitive method, access should be initiated by mentally ignoring the clinical or restored crown of the tooth and looking beyond the crown to the mentally imaged CEJ.² As can be seen in Figure 2, prosthetic crowns can mislead a clinician because the crown's anatomy is not always centered over the CEJ.

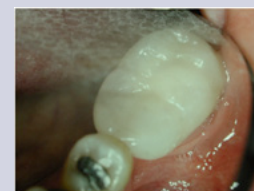

Fig. 2. Location of CEJ unrelated to oversized crown.

Step 1

The first step in accessing any tooth begins with the physical identification of the shape and position of the CEJ. This can be accomplished by using a periodontal probe to explore the complete circumference of the CEJ in order to form a mental picture of its extent as shown in Figures 3a-d.

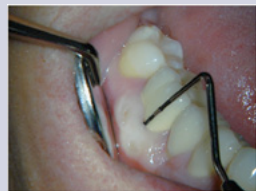

Fig. 3a.

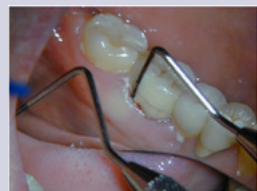

Fig. 3b.

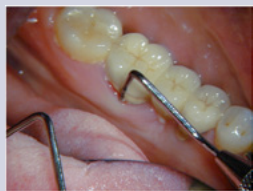

Fig. 3c.

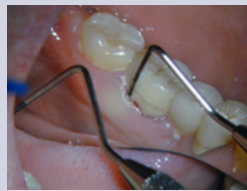

Fig. 3d.

Periodontal probing to locate the CEJ.

Once the CEJ is visualized, a penetration point on the occlusal surface can be selected. On a restorative surface this point may be unrelated to the occlusal anatomy present. This can be seen in Figure 3e, on page 3, where the correct penetration point on the oc-

clusal surface is indicated by the blue circle. This point has been determined by radiographic examination, periodontal probing and the mental picture of the CEJ perimeter.

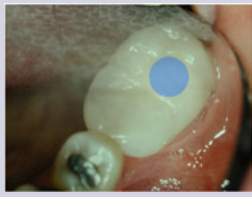

Fig. 3e. Location of initial penetration point based on the CEJ perimeter.

The visualization of the ultimate outline of the pulp chamber can be aided by utilizing another law of pulp chamber anatomy, The Law of Concentricity.² This law states that “the walls of the pulp chamber are concentric to the external outline of the tooth at the level of the CEJ.” The Law of Concentricity is illustrated in Figure 4.

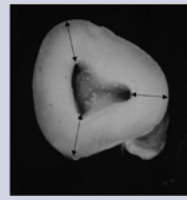


Fig. 4.

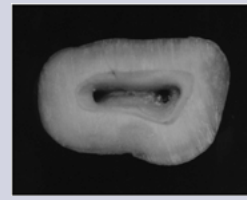


Fig. 5a.

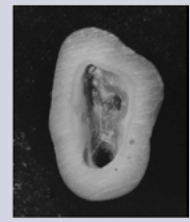


Fig. 5b.

Cut specimens showing the Law of Concentricity.

The Law of Concentricity will help the clinician to extend his access properly. If there is a bulge of the CEJ in any particular direction the pulp chamber also will extend in that direction. For example, if the tooth is narrow mesiodistally, then the clinician will know that the pulp chamber will be narrow mesiodistally, as shown in Figures 5a and 5b.

Step 2

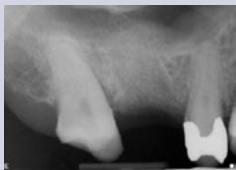

Fig. 6. Determining angulation with radiograph. Note mesial tipping of the maxillary second molar.

The second step is to determine the angulation of the tooth. This can be done by use of radiographs (Figure 6) and clinical observation. Cone beam tomography can aid in this determination in a faciolingual direction.

Step 3

The third step, shown in Figure 7, is to measure, on the radiograph, the distance from the cusp tip to the furcation. Once the cusp tip-pulp floor distance (CPFD) has been determined, a bur can be set in the handpiece short of this length and, thereby, prevent perforation in the furcation.

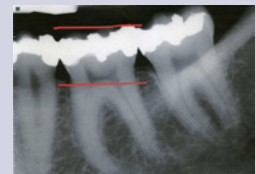


Fig. 7. Measuring the occlusal-furcal distance.

If the bur is directed towards the center of the CEJ, parallel to the long axis of the tooth and set short of the furcation, perforation of the chamber is unlikely.³

Step 4

Following the identification of the CEJ perimeter, the angulation of the long axis of the tooth and the CPFD, an initial occlusal penetration point can be selected. Thus, the entry point on the occlusal surface of the tooth is variable and will be completely dependent on all of these factors. All recommendations about beginning at a particular point on an occlusal surface such as a pit or fossa relationship can be misleading. In some bizarre circumstances, the access starting point can even be on a cusp. The underlying concept for this is: the internal anatomy of the pulp chamber dictates the ultimate outline form. This outline form may be triangular, trapezoidal or irregular.

Technique of Access

Step 1

Before beginning the mechanical portion of the access, all defective restorations and caries should be removed. Leaving leaky restorations or caries can permit bacterial contamination during and following treatment.

Step 2

The shape and type of bur to be used is completely up to the clinician. A #4 carbide or round diamond or #557 taped fissure bur are commonly used. For prosthetic crowns, special metal cutting fissure burs are available. Whichever bur is selected should penetrate the occlusal surface at the point determined by the pre-access factors (CEJ perimeter, tooth angulation, CPFD). The bur should be advanced towards the center of the mentally imaged CEJ until a drop is felt or the head of the handpiece touches the cusp. However, a word of caution—a drop-off will only be felt when the pulp chamber is at least 2mm deep.

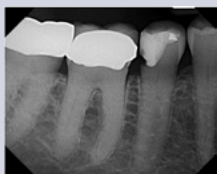

Fig. 8. Radiograph of calcified canals in a molar.

When evaluating a tooth for treatment or referral, the pulp chamber roof to floor distance should influence this decision. Teeth that appear to have calcified pulp chambers, such as in Figure 8, should be considered for referral.

Step 3

The goal of every access is to remove the pulp chamber roof completely.⁴ Until the roof is completely removed, a conscious effort should be made to avoid looking for orifices because there is a great danger of gouging either the floor or walls leading to a perforation. Orifices will be revealed once the roof has been removed and access is complete. This can be seen in “The Access Box: an Ah-Ha Phenomenon,”⁵ included in the online bonus materials.

The two ways to unroof the chamber are to either place a straight bur and move it laterally while keeping it parallel to the long axis of the tooth, or place a round bur into the access engaging laterally under the remaining overhang and then withdrawing the bur occlusally, illustrated in Figure 9.

The roof is continually shaved away until the access is complete.

One of the most difficult steps during this process is determining when the access is complete. In order to know when an access is finished, the clinician needs to know another law, the Law of Color Change.² This law states that the color of the pulp chamber is always darker than the surrounding walls. The Law of Color Change provides guidance to determine when the access is complete. Since the walls are lighter, there will be a junction at which the light walls meet the dark floor. This junction, the floor-wall junction shown in Figure 10, traverses the entire pulp chamber floor.

An operator knows that the access is complete when he can see the floor-wall junction 360 degrees around the chamber floor as shown in Figure 11.

Because a distinct light-dark junction is always present, if it is not seen in one portion of the chamber floor, the operator knows that additional overlying structure must be removed. This structure could be restorative material, reparative dentin or overlying pulp chamber roof. This interference with the complete visualization of the walls can be seen in Figure 12. **The clear identification of the floor-wall junction is the single most important aspect of the accessing phase of endodontic treatment.**

If this can't be achieved, the case should be strongly considered for referral. Figure 12 is an example of an incomplete access. Notice how you cannot see the floor meeting the walls 360 degrees around.

Figure 13 illustrates a complete access. Notice how the walls can be seen meeting the floor around the entire perimeter of the pulp chamber.

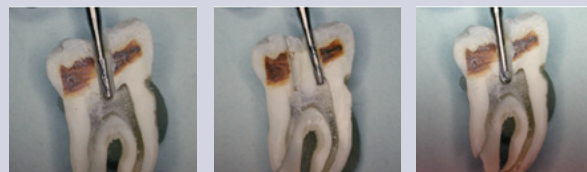


Fig. 9a. Fig. 9b. Fig. 9c.
Using different burs to unroof the pulp chamber.

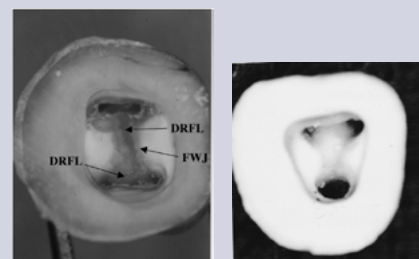


Fig. 10. Cut specimen showing floor-wall junction. Fig. 11. Cut specimen showing complete access.

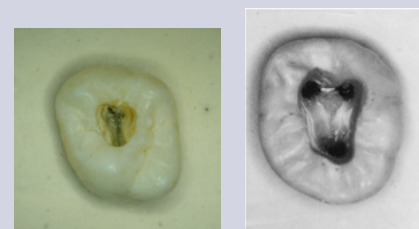


Fig. 12. An example of incomplete access. Fig. 13. An example of complete access.

Orifice Location

The number of root canal orifices in a particular tooth can never be known prior to the commencement of treatment. Although radiographs are helpful and can sometimes indicate the number of roots, and averages have been enumerated,^{6, 7, 8, 9} most of the time the number or position of the root canal orifices cannot be identified.

So how does a clinician determine the exact number of orifices in a tooth without causing iatrogenic tooth destruction? The only effective and safe way is to visualize the full extent of the pulp chamber floor and use a variety of anatomic landmarks.

In a previous article,² it was demonstrated that a set of laws can be used to identify where orifices exist on the pulp chamber floor. These laws are:

Law of Symmetry 1: Except for the maxillary molars, the orifices of the canals are equidistant from a line drawn in a mesial-distal direction through the center of the pulp chamber floor (Figure 14).

Law of Symmetry 2: Except for the maxillary molars, the orifices of the canals lie on a line perpendicular to a line drawn in a mesial-distal direction through the center of the pulp chamber floor (Figure 15).

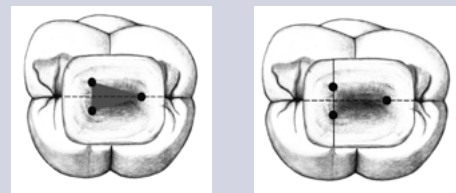


Fig. 14. A diagram of the Law of Symmetry 1. Fig. 15. A diagram of the Law of Symmetry 2.

Law of Color Change: The color of the pulp chamber floor is always darker than the walls (Figures 16a and 16b).

Law of Orifice Location 1: The orifices of the root canals are always located at the junction of the walls and the floor (Figure 17).

Law of Orifice Location 2: The orifices of the root canals are located at the vertices of the floor-wall junction (Figure 18). After the floor-wall junction is clearly seen, all of the Laws of Symmetry and Orifice Location can be used to identify the exact position and number of orifices.

Look at the position of the orifices on the pulp chamber floor in Figure 19. Knowledge of the Laws of Symmetry 1 and 2 immediately indicates the presence of a fourth orifice. Indeed, it not only implies the presence of a fourth orifice but exactly where it is located.

The Law of Orifice Locations 1 and 2 can be used to identify the number and position of the root canal orifices of the tooth. Because all of the orifices can only be located along the floor-wall junction, black dots, indentations or white dots that are observed anywhere else (*e.g.*, the chamber walls or in the dark chamber floor) must be ignored to avoid possible perforation. The Law of Orifice Location 2 can help to focus on the precise location of the orifices. The vertices or angles of the geometric shape of the dark chamber floor will specifically identify the position of the orifice. If the canal is calcified, then this position at the vertex will indicate with certainty where the clinician should begin to penetrate with his bur to remove reparative dentin from the upper portion of the canal (Figure 20).

The Law of Orifice Locations 1 and 2, in conjunction with the Law of Color Change, is often the only reliable indicator of the presence and location of second canals in mesiobuccal roots of maxillary molars (Figure 16). Look at the floor anatomy in Figure 16a. Along the floor-wall junction, there is an angle in the floor geometry between the mesiobuccal and palatal orifices. The Laws of Orifice Locations 1 and 2 dictate the presence of a mesiopalatal (MB2) orifice, seen in Figure 16b. This orifice, present in the overwhelming majority of maxillary molars,¹⁰ can be any distance from either orifice but must be along this junction line.

The Laws of Symmetry 1 and 2 (except for the maxillary molars), Color Change, and Orifice Locations 1 and 2 can be applied to any tooth. They are especially valuable when unexpected or unusual anatomy is present. Notice the diagrammatic representation of a chamber floor of a maxillary second premolar in Figure 21a. Knowledge of the chamber-floor-anatomy laws immediately leads the observer to realize that there are three canals in this tooth (Figure 21b).

Another example of the value of chamber floor anatomy knowledge can be seen in Figure 22a, which shows a mandibular molar that has been sectioned at the CEJ. Using the laws of chamber-floor anatomy, the observer is guided to realize that there are only two orifices in this tooth. Their positions

are indicated in Figure 22b. The observer should be cautioned that the number of orifices does not necessarily correlate to the number of canals. Sometimes, more than one canal can be present in a single orifice.

In spite of all of our best efforts, problems during treatment can occur. Following is a description of the most common problems that a practitioner might encounter and how to remedy them.

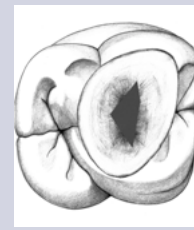


Fig. 16a.

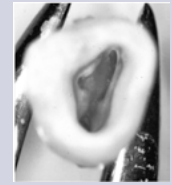


Fig. 16b.

Examples of the Law of Color Change.

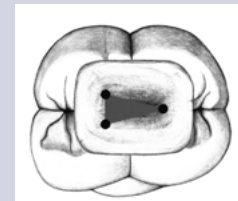


Fig. 17. A diagram of the Law of Orifice Location 1.

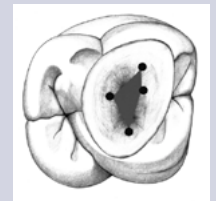


Fig. 18. A diagram of the Law of Orifice Location 2.

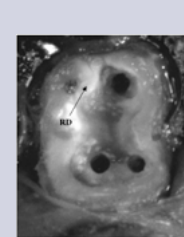


Fig. 19. Orifice location using the Laws of Symmetry.

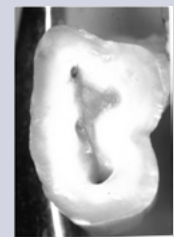


Fig. 20. Cut specimen showing the vertices on the pulp chamber floor.

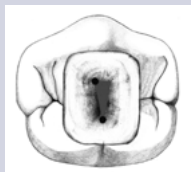


Fig. 21a.

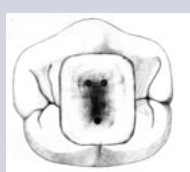


Fig. 21b.

Location of a third orifice on a maxillary premolar using the Laws of Floor Anatomy.

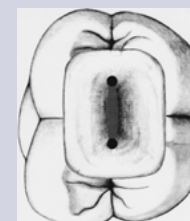


Fig. 22a.

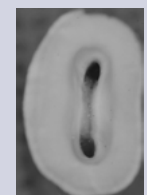


Fig. 22b.

Floor anatomy showing 2 orifices in a mandibular molar.

Problem-Solving Flowchart

PROBLEM: *Unable to observe the pulp chamber floor due to excessive bleeding*

Cause

- This is usually caused by pulp tissue either in the chamber or in the canals

Remedy

- Enlarge the access by removing the pulp chamber roof without touching the chamber floor (Never touch the pulp chamber floor unless the floor-wall junction is fully seen)
- Place hemostatic agents in the chamber
- Use a barbed broach to remove the tissue

PROBLEM: *Unable to observe the pulp chamber floor due to inadequate removal of pulp chamber roof*

Cause

- Improper selection of the initial access penetration point
- Inability to see the floor-wall junction 360 degrees around

Remedy

- Return to previous bur (either round or tapered) and continue to shave back until the floor-wall junction is visualized

PROBLEM: *Unable to observe the pulp chamber floor due to restorative materials impinging onto the pulp chamber*

Cause

- Inadequate removal of all restorative material before access has begun (in particular, Class V restoration may impinge onto the pulp chamber floor)

Remedy

- Remove all restorative material before beginning the access

PROBLEM: *Calcification/pulp stones*

Cause

- Degenerating pulp

Remedy

- Following the complete removal of the pulp chamber roof and cessation of bleeding, a large smooth round bur (#6) can be used to smooth the pulp chamber floor to remove the calcification and delineate the floor-wall junction clearly

PROBLEM: *Unable to observe the pulp chamber floor due to inadequate light*

Cause

- Access too small
- Presence of crowns or restorative materials
- Lack of smooth surfaces of walls or pulp chamber floor (usually caused by too small round burs)

Remedy

- Enlarge access until floor-wall junction can be seen
- Remove restorative materials
- Use accessory light (LED headlight or surgical operating microscope) when crown is present¹¹
- Smooth all irregularities on walls and pulp chamber floor with round burs

PROBLEM: *Unable to observe the pulp chamber due to loss of orientation*

Cause

- Using occlusal surface as reference point
- Failure to observe tooth orientation such as rotated or tilted tooth
- Losing sight of CEJ circumference
- Improper angulation of initial access

Remedy

- Proper pre-access observation of tooth orientation
- Proper mental imaging of the CEJ
- Remove rubber dam during access to regain orientation
- Appropriate angle of penetration of initial access bur

PROBLEM: *Floor perforation*

Cause

- Premature attempt to identify orifices
- Failing to measure occlusal-furcal distance
- Improper identification of the floor-wall junction
- Inadequate access

Remedy

- Remove entire pulp chamber roof before identifying orifice location
- Observe floor-wall junction 360 degrees around
- Set bur at length less than occluso-furcal distance
- Direct accessing bur towards center of the CEJ perimeter

PROBLEM: *Lateral chamber wall perforation*

Cause

- Failing to mentally image the CEJ
- Improper angle of access entry
- Using occlusal anatomy to begin access penetration

Remedy

- Remove entire pulp chamber roof before identifying orifice location
- Observe floor-wall junction 360 degrees around
- Direct accessing bur towards center of the CEJ perimeter
- Choose initial penetrating access point based on CEJ imaged perimeter

PROBLEM: *Unable to identify all orifices*

Cause

- Failure to establish a complete access
- Lack of delineation of a distinct floor-wall junction
- Presence of restorative materials
- Presence of calcifications

Remedy

- Make sure a complete access is performed
- Smooth the pulp chamber floor to remove calcifications and delineate floor-wall junction
- Use laws of pulp chamber floor anatomy to identify the positions of orifices

Summary

In order to increase the success rate of endodontically treated teeth, as much of the pulp complex should be removed as is possible. In order to accomplish this, all of the root canal orifices in a pulp chamber must be found. The only rational way to do this is by utilizing the laws of anatomy of the pulp chamber floor. The only way to utilize these laws is by having an access that permits the visualization of the pulp chamber walls meeting the floor 360 degrees around. This newsletter has demonstrated and provided solutions to all of the clinical conditions that may hinder this visualization. In addition, we have presented a problem-solving flowchart that addresses all of the common pitfalls during access and orifice location that may confront a general practitioner.

References

1. Cohen S, Hargreaves K. Pathways of the Pulp 9th ed. Mosby, St. Louis, MO, 2006.
2. Krasner P, Rankow HJ. Anatomy of the pulp chamber floor. J Endodon 2004; 30(1):5.
3. Moreinis SA. Avoiding perforation during endodontic access, J Am Dent Assoc 1979; 98:707.
4. Weller RN, Hartwell G. The impact of improved access and searching techniques on detection of the mesiolingual canal in maxillary molars. J Endodon 1989; 15:82.
5. Rankow HJ, Krasner P. The Access Box: An Ah-Ha Phenomenon. J Endodon 1995; 21(4):212-214.
6. Hess W, Zurcher E. The Anatomy of Root Canals of the Teeth of the Permanent and Deciduous Dentitions. William Wood, New York, NY, 1925.
7. Nattress BR, Martin DM. Predictability of radiographic diagnosis of variations in root canal anatomy in mandibular incisor and premolar teeth, In Endod J 1991; 24(2):58.
8. Pineda F, Kuttler Y. Mesiodistal and buccolingual roentgenographic investigation of 7275 root canals. Oral Surg Oral Med Oral Pathol Oral Radio Endod 1972; 33:10.
9. Vertucci F. Root canal anatomy of the human permanent teeth. Oral Surg Oral Med Oral Pathol Oral Radio Endod 1984; 58:58.
10. Kulild JC, Peters DD. Incidence and configuration of canal systems in the mesiobuccal root of maxillary molar first and second molars. J Endodon 1990; 16(7):311-16.
11. Buhrey IJ, Barrows MJ, BeGole EA, Wenckus CS. Effect of magnification on locating the MB-2 canal in maxillary molars. J Endodon 2002; 28(4):324.

The AAE wishes to thank Drs. Paul Krasner, Henry J. Rankow and Edward S. Abrams for authoring this issue of the newsletter, as well as the following reviewers: Drs. James A. Abbott, Reid El-Attrache, Gerald N. Glickman, William T. Johnson and James F. Wolcott.

AAE COLLEAGUES ONLINE

Exclusive Bonus Materials

This issue of the *ENDODONTICS: Colleagues for Excellence* newsletter is available online at www.aae.org/colleagues with the following **exclusive bonus materials**:

- The Access Box: An Ah-Ha Phenomenon
- Anatomy of the Pulp-Chamber Floor
- "Ask the Author" Discussion Board for all of your questions and comments

All back issues of this newsletter are also available for your ongoing reference online.

New!

Earn CE Online

Earn CE credit for the *ENDODONTICS: Colleagues for Excellence* newsletter series via the AAE Live Learning Center at www.aae.org/livelearningcenter.

LIVE LEARNING
CENTER

The information in this newsletter is designed to aid dentists. Practitioners must use their best professional judgment, taking into account the needs of each individual patient when making diagnosis/treatment plans. The AAE neither expressly nor implicitly warrants against any negative results associated with the application of this information. If you would like more information, consult your endodontic colleague or contact the AAE.

American Association of Endodontists
211 E. Chicago Ave., Suite 1100
Chicago, IL 60611-2691
info@aae.org • www.aae.org

Did you enjoy this issue of *ENDODONTICS*? Are there topics you would like *ENDODONTICS* to cover in the future? We want to hear from you! Send your comments and questions to the American Association of Endodontists at the address at left.