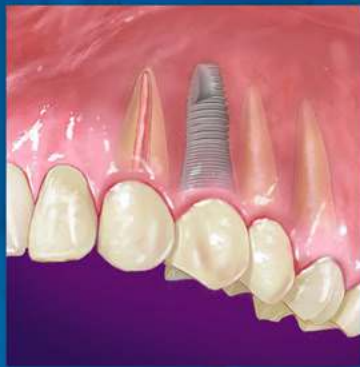

ENDODONTICS



*Colleagues for
Excellence*

Spring 2015

*Treatment Planning: Retention of the
Natural Dentition and the Replacement
of Missing Teeth*



Published for the Dental Professional Community by the
American Association of Endodontists

www.aae.org/colleagues

Preservation of the natural dentition is the primary goal of dentistry. Published surveys indicate that patients generally value teeth and express a desire to save their natural dentition in favor of extraction whenever possible (1,2). Significant technological and biological improvements have been made in all disciplines of dentistry, making long-term retention of natural teeth more attainable. Patients entrust dental professionals to make appropriate recommendations regarding the maintenance and restoration of their oral health and function. It is essential to employ an evidence-based, interdisciplinary approach that addresses the interests of the patient when determining the best possible course of treatment.

In July 2014, the American Association of Endodontists, in collaboration with the American College of Prosthodontists and the American Academy of Periodontology, hosted a two-day Joint Symposium titled *Teeth for a Lifetime: Interdisciplinary Evidence for Clinical Success*. Approximately 375 general dentists and specialists assembled in Chicago to focus on preserving the natural dentition. The educational program included evidence-based presentations on advanced regenerative techniques, improvements in technology, minimally invasive restorative methods and best practices for interdisciplinary treatment planning. Dr. Alan Gluskin, chair of the 2014 Joint Symposium Planning Committee, concluded that the current evidence directs clinicians to consider saving the natural dentition as the first option when developing treatment plans.

Dental implants are one of the most significant advancements in contemporary dentistry. This innovation has had profound effects on endodontic, periodontic and prosthodontic treatment planning for the rehabilitation of edentulous spaces and for teeth with an unfavorable prognosis (3). Implant-supported restorations minimize unnecessary preparation of intact abutment teeth and allow fixed prosthodontic replacement when suitable abutments are absent. With appropriate usage and case selection, implant dentistry provides a viable option for the replacement of missing teeth (4, 5).

There has been an increasing trend towards replacing diseased teeth with dental implants. Often, an inadequate or inappropriate indication for tooth extraction has resulted in the removal of teeth that may have been salvageable (6). Teeth compromised by pulpal or periodontal disease have value and should not be extracted without thoroughly evaluating restorability and potential retention therapies (7).

A recent systematic review published in the *Journal of the American Dental Association* highlights a key question: “Is the long-term survival rate of dental implants comparable to that of periodontally compromised natural teeth that are adequately treated and maintained?” (8). Nineteen studies with a follow-up period of at least 15 years were included in the analysis. The results show that implant survival rates do not exceed those of compromised but adequately treated and maintained teeth. These findings support other studies comparing long-term survival of implants and natural teeth (9, 10), providing an important message: periodontally compromised teeth can be retained with quality treatment and appropriate maintenance. Therefore, it may be advisable to postpone implant consideration for the periodontitis-susceptible patient to fully utilize and extend the capacity of the natural dentition (11).

Treatment Planning Options

A key focus of the Joint Symposium involved treatment planning decisions regarding endodontic treatment and implant therapy. Should a tooth with pulpal disease be retained with root canal treatment and restoration, or be extracted and replaced with an implant-supported restoration? This assessment involves a challenging and complex decision-making process that must be customized to suit the patient’s needs and desires (12-14). The topic has received considerable attention in the literature, the media and at dental continuing education courses.

Endodontic treatment and implant therapy should not be viewed as competing alternatives, rather as complementary treatment options for the appropriate patient situation (Figure 1). Root canal treatment is indicated for restorable, periodontally sound teeth with pulpal and/or apical pathosis. Endodontic treatment on teeth with nonrestorable crowns or teeth with severe periodontal conditions is contraindicated, and other options such as implant placement should be considered (15). When making treatment decisions, the clinician should consider factors including outcome assessment, local and systemic case-specific issues, costs, the patient’s desires and needs, esthetics, potential adverse outcomes and ethical factors (16).

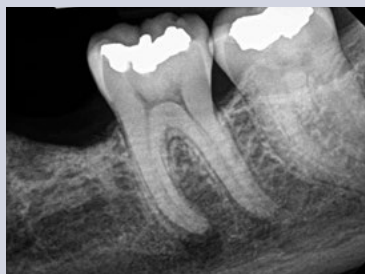

Fig. 1A. Pre-op image of tooth #19 with pulp necrosis and symptomatic apical periodontitis. The patient is interested in rehabilitation of the edentulous space.

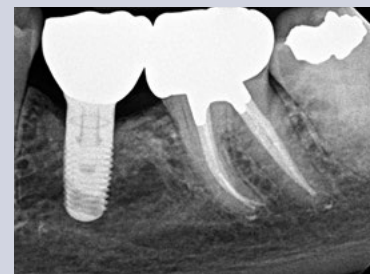


Fig. 1B. Three-year recall image. The patient has benefited from both root canal treatment and implant therapy. Courtesy of Dr. Tyler Peterson and the University of Minnesota School of Dentistry.

Outcome Assessment: Success and Survival

Treatment outcomes play a key role in the assessment of different treatment options. Patients often ask whether a procedure is going to be successful or not. This question can be challenging for a clinician to answer due to the variety of reported outcomes in the literature (17). There are differences in the methodology and criteria used to evaluate the outcomes for root canal treatment and implant prosthetics, which makes comparisons between success rates difficult, if not impossible (18). Endodontic studies have historically used “success” and “failure” as outcome measures and have focused on a strict combination of radiographic and clinical criteria (19). In contrast, the implant literature has primarily reported “survival” (20, 21), *i.e.*, the implant is either present or absent. Therefore, implant studies that solely evaluate survival as an outcome measure will likely publish higher success rates than endodontic studies that rely on biologic healing and factors related to the entire restored tooth. To establish more valid and less biased comparisons, the same outcome measures should be used. A more patient-centered measure is to compare the outcome of survival, which is considered to be an asymptomatic tooth/implant that is present and functioning in the patient’s mouth (22, 23).

Multiple large-scale studies including millions of teeth have used survival to assess the outcome following root canal treatment. An investigation using an insurance database of more than 1.4 million root canal-treated teeth demonstrated that 97 percent were retained within an eight-year follow-up period (24). Other studies show similarly high survival rates (25, 26) (Table 1). An epidemiological approach allows for the assessment of tooth retention from a large sample of patients

experiencing actual care in private practices. Systematic reviews (27) and controlled studies from academic settings complement the previous findings. Two prospective trials each reported 95 percent survival rates at four years (28) and four to six years (29) for teeth after initial root canal treatment.

Authors	Number of Teeth	Follow-up (years)	Survival (percent)
Salehrabi and Rotstein (24)	1,463,936	8	97
Chen et al. (25)	1,557,547	5	93
Lazarski et al. (26)	44,613	3.5	94.4

Table 1. Survival rates following initial nonsurgical root canal treatment

Predictable Tooth Retention: Nonsurgical Root Canal Treatment and Restoration

The majority of endodontic treatment is performed by general dentists with a high degree of success (26). For complex cases, referral to an endodontist with additional training and expertise may result in more favorable outcomes (30) and positive patient experiences (31). Interdisciplinary care is important for the management of endodontically treated teeth. The restorative dentist plays a significant role in the outcome by providing an appropriate and timely restoration (32). Root canal treatment is not complete until the tooth is coronally sealed and restored to function. Multiple studies have confirmed that a definitive restoration has a significant impact on survival (24, 25, 27, 28, 33). Therefore, the likelihood of a favorable outcome increases with both skillful endodontic care and prompt restorative treatment (34) (Figure 2).

Advancements in technology aid in attaining high levels of tooth retention. The dental operating microscope, nickel-titanium instruments, apex locators, enhanced irrigation protocols, and dentin preservation strategies are examples of improvements that allow clinicians to predictably manage a greater range of treatment options. Additionally, cone beam-computed tomography facilitates more accurate diagnosis and improved decision-making for the management of endodontic problems (35, 36).

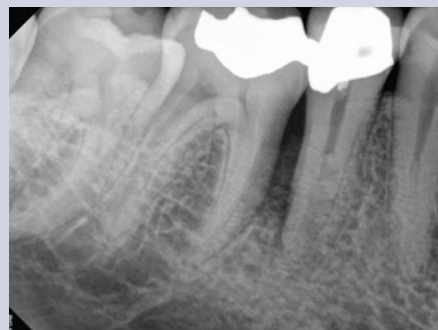

Fig. 2A. Pre-op image of tooth #29. Note lateral radiolucency and complex canal anatomy.

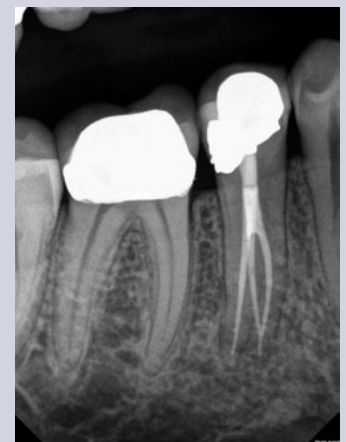

Fig. 2B. Two-year recall image reveals both excellent endodontic and restorative treatment. Note healing of lateral radiolucency. Courtesy of Dr. Joe Petrino.

Comparative Studies: Endodontically Treated Teeth and Single-Tooth Implants

Large-scale systematic reviews have addressed the relative survival rates of endodontically treated teeth and single-tooth implants. The Academy of Osseointegration conducted a meta-analysis using 13 studies (approximately 23,000 teeth) on restored endodontically treated teeth and 57 studies (approximately 12,000 implants) on single-tooth implants. The outcome data demonstrated no difference between the two groups during any of the observation periods (37). Another systematic review supported by the American Dental Association compared the outcomes of endodontically treated teeth with those of a single-tooth implant-restored crown, fixed partial denture, and no treatment after extraction. At 97 percent, the long-term survival rate was essentially the same for implant and endodontic treatments. Both options were superior to extraction and replacement of the missing tooth with a fixed partial denture (38).

Retrospective studies also have compared the outcomes for the two treatment options. A study conducted at the University of Minnesota compared the outcomes of 196 restored endodontically treated teeth with 196 matched single-tooth implants (39). Both groups had 94 percent survival rates. The survival curves for these two groups are provided in Figure 3. Another investigation from the University of Alabama provided similar results (40).

Based upon similar survival rates, the decision to treat a compromised tooth endodontically or replace it with an implant must be based on factors other than treatment outcome (37, 41). Several factors influence the decision-making process (42-44). The following lists provide an overview of case-specific factors that should be considered in making this treatment decision.

Systemic Factors:

- The list of potential risk factors for peri-implantitis or implant failure is extensive. It includes systemic disease, genetic traits, chronic drug or alcohol consumption, smoking, periodontal disease, radiation therapy, diabetes, osteoporosis, dental plaque and poor oral hygiene (45).
- There are few medical conditions that directly affect endodontic treatment outcomes. Risk factors that may be associated with decreased survival of root canal-treated teeth include smoking (46), diabetes (28, 46), systemic steroid therapy (28) and hypertension (47).
- Patients taking antiangiogenic or antiresorptive (*i.e.*, bisphosphonates) medications may have an increased risk for developing medication-related osteonecrosis of the jaw. This may affect treatment planning for both implant and endodontic treatment.
- It is generally recommended to wait for the completion of dental and skeletal growth prior to implant placement (48).

Local Factors:

- Accurate diagnosis
- Restorability assessment: removal of caries/restorations; adequate ferrule
- Strategic nature of the tooth as it fits into the comprehensive restorative plan
- Caries risk and oral hygiene
- Periodontal assessment: tissue biotype, adequate biologic width
- Presence of crack(s), root fracture(s), resorption
- Occlusion and parafunction

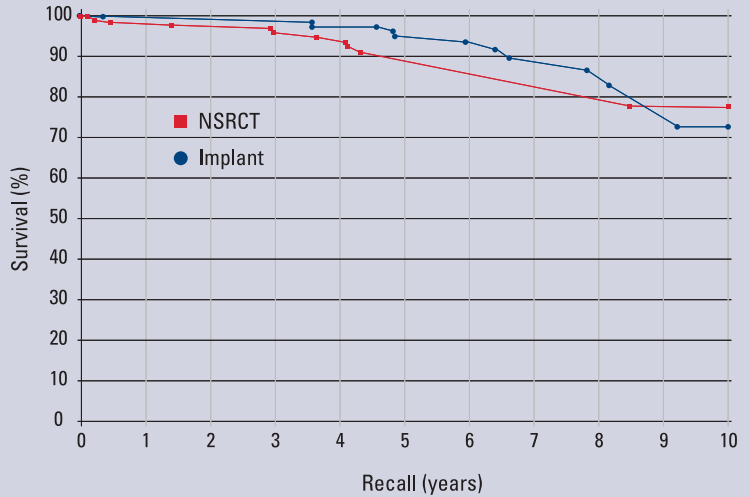


Fig. 3. A matched-case comparison of survival rates after treatment with either a restored endodontically treated tooth (n=196) or a restored single-tooth implant (n=196) performed at the same institution. J Endod 2006;31.

- Teeth with less than two proximal contacts and those serving as fixed partial denture abutments may have lower survival (27)
- Need for adjunctive treatment (crown lengthening, orthodontic extrusion, sinus lift, bone graft, etc.) which may impact financial cost and time to function
- Quantity and quality of bone
- Proximity to anatomical structures (maxillary sinus, inferior alveolar nerve, etc.)
- Implant esthetics in the anterior region may be challenging (49)

In addition to systemic and local factors, it is critical to include the patient's concerns during treatment planning. Common patient-centered factors include costs, treatment duration, satisfaction with treatment and the potential for adverse outcomes.

Financial considerations can influence a patient's decision when weighing treatment options. The availability of dental insurance may also impact choices (50). Endodontic treatment and restoration offer considerable economic advantages to the patient (51-53). A benefit of root canal treatment is the short time frame required to completely restore both dental function and esthetics. In one study of about 400 patients, the restored single-tooth implant showed a longer average and median time to function than similarly restored endodontically treated teeth. Additionally, the implant group had a higher incidence of post-treatment complications requiring subsequent treatment interventions (39). This increased post-operative care can impact patients in terms of additional visits, lost wages and unforeseen costs.

Clinicians should consider the patient's preferences, which are often related to function, comfort and esthetics. Tooth loss is associated with an impaired quality of life (54), and surveyed patients express a clear desire to save their natural dentition whenever possible (2). Large-scale surveys of post-endodontic patients have demonstrated that endodontic treatment not only preserves the natural tooth, but also significantly improves patients' quality of life (55). More than 97 percent of patients report being satisfied with their endodontic treatment (31). If an implant is used to restore an edentulous space, a similarly high percentage of patients have a positive experience with implant therapy (56). Furthermore, comparative studies demonstrate that patients report a high degree of satisfaction with the overall experience following both procedures (2, 15).

Despite high survival rates, both endodontically treated teeth and implants are susceptible to complications. Nonrestorable caries, prosthetic failures, periodontal disease, crown/root fractures and specific endodontic factors are examples of complications following root canal treatment (57). Complications associated with implants and related prostheses include: surgical, implant loss, bone loss, peri-implant soft-tissue, mechanical and esthetic/phonetic (58). A retrospective study directly compared the rates of additional interventions related to complications. Implant cases had a substantially higher need for subsequent intervention and maintenance visits than endodontically treated teeth (40). However, a more recent prospective study suggests that patients from both groups have minimal complications at one-year follow-up (15).

Endodontic Retreatment Options

The consequences of failure and subsequent treatment differ between endodontics and implants. Endodontic failure can usually be addressed successfully by retreatment, microsurgery, or by extraction and potential implant placement. Intervention after implant failure may vary from minimal restorative repairs to multiple corrective surgeries and/or the use of a different prosthesis (59).

Nonsurgical retreatment, or revision, is often the first choice to address post-treatment apical periodontitis (60, 61), provided that the tooth is suitable for further restoration and that the restoration will have a good long-term prognosis (62) (Figure 4). Current best

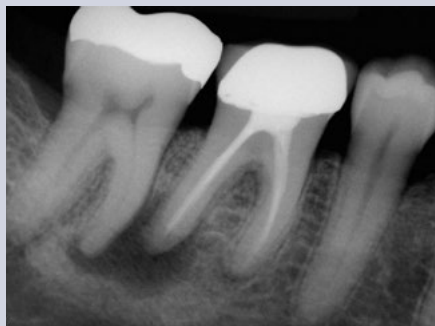

Fig. 4A. Pre-op image of tooth #30 with previous endodontic treatment and persistent apical periodontitis. A dentist initially recommended extraction and replacement of this tooth with an implant. The patient requested a second opinion from an endodontist who determined the tooth to be treatable.

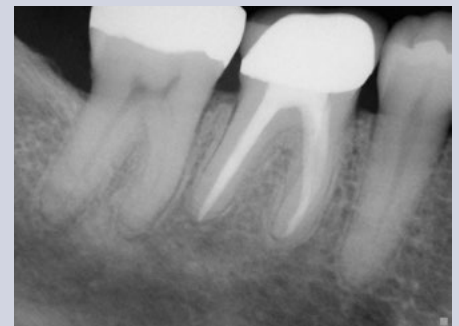

Fig. 4B. Four-year recall image demonstrates apical healing following nonsurgical retreatment. Accurate diagnosis prevented the unnecessary treatment of tooth #31. *Courtesy of Dr. Martin Rogers.*

evidence indicates that the survival of nonsurgical retreatment is similar to that of primary treatment, and that the two treatments share similar prognostic factors (63). Two studies specifically evaluated survival following retreatment. An epidemiological study using an insurance database of 4,744 retreated teeth reported an 89 percent survival rate at five years (64) and a prospective trial of 858 retreated teeth reported a 95 percent survival at four years (28).

Modern techniques and rationale contribute to excellent potential outcomes for retreatment. An important factor when considering retreatment is the ability to identify and address the etiology of post-treatment disease (63). Primary sources of nonhealing are persistent intracanal microorganisms or ingress of microorganisms following treatment. If the etiology of the problem is deemed correctable via an orthograde approach, retreatment is often the first choice. If not, a surgical approach may be the more predictable option (65).

Contemporary endodontic microsurgery has undergone significant technological and procedural advancements (66, 67). Recently performed studies suggest that microsurgical techniques using biocompatible root-end filling materials provide significant improvements over traditional methods. A meta-analysis showed contemporary microsurgical techniques to have a significantly improved outcome (94 percent) compared to older techniques and instruments (59 percent) (68). A recent systematic review investigating current microsurgery found survival rates of 94 percent at two to four years and 88 percent at four to six years, indicating that teeth treated with endodontic microsurgery tended to be lost at low rates over the time studied (69). Microsurgery, with appropriate case selection, is a predictable procedure for teeth that may have been considered for extraction in the past.

Ethics and Interdisciplinary Consultation

Clinicians are ethically bound to inform patients of all reasonable treatment options, explain the risks and benefits involved with the available treatment options, and obtain informed consent before initiating treatment. This information should be conveyed in an impartial manner (1). Patients value participation in the decision-making process and should be encouraged to exercise autonomy by communicating their preferences (70). Clinical treatment decisions regarding either endodontic treatment or tooth extraction with implant therapy must always be made in the best interest of the patient using the best, most current evidence.

Should it be necessary, experts from the dental team may need to be called upon to assist the clinician in rendering the highest quality of care (Figure 5). The standard of care must be applied equally to all clinicians, generalists and specialists alike. The AAE's *Endodontic Case Difficulty Assessment Form and Guidelines* provides valuable information to aid the clinician in case selection and determining whether to treat or refer. Patients are deserving of the best possible

outcome for each case. Interdisciplinary communication and collaboration during treatment planning maximizes this likelihood.

Specialists and restorative dentists should be viewed as partners in the treatment planning team. Endodontists are uniquely positioned to evaluate the restorability and prognostic longevity of teeth and recommend whether to attempt natural tooth preservation or consider extraction and replacement with an implant (71). Likewise, the endodontist should be well-versed

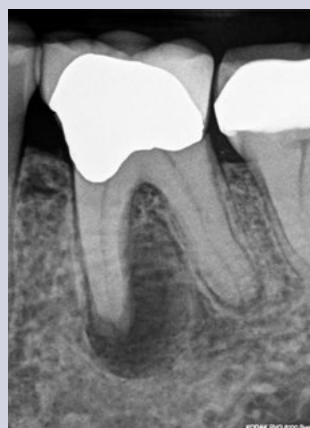

Fig. 5A. Pre-op image of tooth #19 with pulp necrosis and chronic apical abscess.

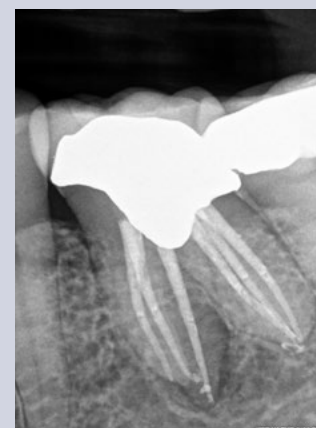


Fig. 5B. Two-year recall image demonstrates excellent endodontic treatment and healing of apical periodontitis. Courtesy of Dr. Deb Knaup.

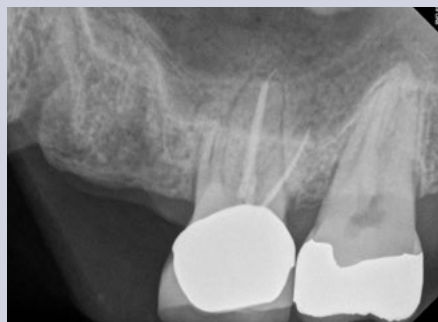

Fig. 6A. Pre-op image. Tooth #14 was determined to have a vertical root fracture of the MB root. The patient expressed a strong desire to retain the natural dentition but also to rehabilitate the edentulous space.

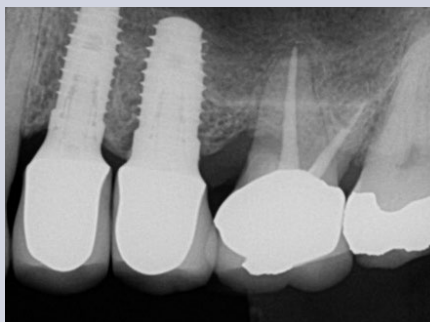


Fig. 6B. Two-year recall image. Tooth #14 had retreatment and resective surgery on the MB root. Two dental implants have restored the edentulous space. Courtesy of Dr. Brian Barsness and the University of Minnesota School of Dentistry.

in implant treatment planning to assist patients and referring colleagues in making an informed choice regarding all replacement options (72, 73).

If a tooth has a questionable prognosis, the endodontic specialist becomes an indispensable part of the treatment planning team. The endodontist has experience with various treatment options that have potential to preserve the natural dentition. Consultation regarding a questionable tooth is often in the patient's best interest prior to considering extraction. If the prognosis of a restorable tooth is categorized as questionable or unfavorable in multiple areas of evaluation, extraction should be considered after appropriate consultation with all relevant specialists. Only then is the decision to extract an informed choice. Extraction is an irreversible treatment, but if necessary, dental implants provide an excellent option to replace missing teeth (Figure 6).

Conclusion

Patients are living longer; therefore, preservation of the natural dentition is more important than ever. Helping patients maintain their "Teeth for a Lifetime" is the fundamental goal of dentistry and often aligns with the desires of the patient. A wide range of endodontic procedures result in a high level of tooth retention and patient satisfaction. Large-scale studies provide strong support that the restored endodontically treated tooth offers a highly predictable, long-term approach to preserving "nature's implant"—a tooth with an intact periodontal ligament. Thus, excellent endodontic treatment followed by an immediate restoration of equal quality promises to give patients service and function while maintaining their esthetics for years. The results of multiple studies indicate that the high survival rates for the natural tooth are similar to those reported for the restored single-tooth implant. Therefore, clinicians must consider additional factors when making treatment planning decisions, all of which must be in the best interest of the patient. Endodontic treatment and implant therapy should not be viewed as competing alternatives, rather as complementary treatment options for the appropriate patient situation.

References

For the complete list of references for this newsletter, please visit www.aae.org/colleagues.

Exclusive Online Bonus Materials: Treatment Planning

This issue of the *Colleagues* newsletter is available online at www.aae.org/colleagues with the following *exclusive bonus materials*:

- Full-Text Article: Setzer FC, Kim S. Comparison of long-term survival of implants and endodontically treated teeth. *J Dent Res* 2014;93:19-26.
- Implants. Position Statement of the American Association of Endodontists 2007.
- Full-Text Article: Iqbal MK, Kim S. For teeth requiring endodontic treatment, what are the differences in outcomes of restored endodontically treated teeth compared to implant-supported restorations? *Int J Oral Maxillofac Implants* 2007;22(Suppl):96-116.
- Full-Text Article: Torabinejad M, Anderson P, Bader J, et al. Outcomes of root canal treatment and restoration, implant-supported single crowns, fixed partial dentures, and extraction without replacement: a systematic review. *J Prosthet Dent* 2007;98:285-311.
- Full-Text Article: Doyle SL, Hodges JS, Pesun IJ, et al. Retrospective cross-sectional comparison of initial nonsurgical endodontic treatment and single-tooth implants. *J Endod* 2006;32:822-7.

The AAE wishes to thank Dr. Scott L. Doyle for authoring this issue of the newsletter, as well the following article reviewers: Drs. Peter J. Babick, Linda G. Levin, Robert S. Roda, Tavis M. Sisson and Kenneth W. Tittle.

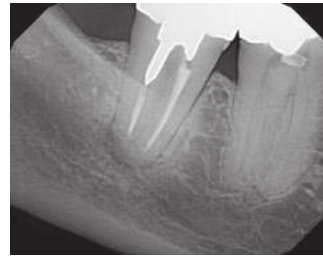
Endodontic Case Study

This new feature in *Colleagues for Excellence* highlights endodontic treatment that demonstrates the benefits of treatment planning and partnership with an endodontist to improve patient outcomes.

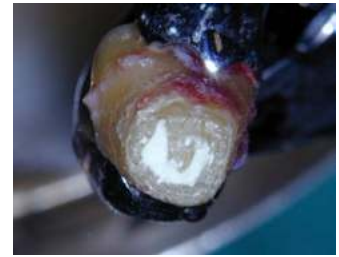This case report demonstrates an alternative treatment option for a patient to save their natural tooth. A 70-year-old female presented to an endodontist's office with a complaint of persistent pain to biting. Tooth #31 had a history of root canal treatment and coronal restoration. A thorough examination, including CBCT, led to the diagnosis of previously treated tooth #31 with symptomatic apical periodontitis. A detailed explanation of the risks and benefits associated with all treatment options was presented. The patient expressed a strong desire to save her tooth and consented to intentional replantation. Tooth #31 was atraumatically extracted and continuously hydrated with Hanks' Balanced Salt Solution. No cracks or fractures were visible. Apical microsurgery was performed extraorally. The root end was resected, ultrasonically prepared and filled with mineral trioxide aggregate. The tooth was replanted. The patient remains asymptomatic and very satisfied with her treatment.

A recent systematic review and meta-analysis revealed a mean survival rate of 88 percent for intentional replantation (1). With careful case selection, intentional replantation may allow for a reasonable, cost-effective treatment option for teeth that do not heal following endodontic treatment. Clinicians are advised to explore all options before recommending extraction. Referral to an endodontist can aid in the retention of a compromised tooth. *Contributed by Dr. Robert S. Roda*

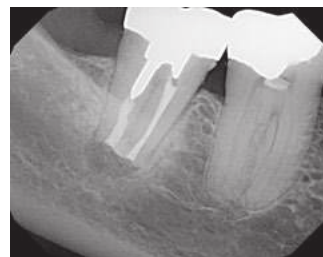1. Torabinejad M et al. Survival of intentionally replanted teeth and implant-supported single crowns: a systematic review. *J Endod* 2015 (in press).



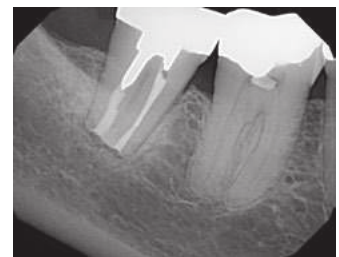
Pre-op image



Root-end filling with MTA



Post-op image



Seven-month recall image



LIVE LEARNING CENTER *Endodontic education online, on demand.*

Earn online CE credit when you enjoy two articles from **Colleagues for Excellence!**
www.aae.org/LiveLearningCenter

Information in this newsletter is designed to aid dentists. Practitioners must use their best professional judgment, taking into account the needs of each individual patient when making diagnosis/treatment plans. The AAE neither expressly nor implicitly warrants against any negative results associated with the application of this information. If you would like more information, consult your endodontic colleague or contact the AAE.




Did you enjoy this issue of *Colleagues*? Are there topics you would like to cover in the future? We want to hear from you! Send your comments and questions to the American Association of Endodontists at the address below, and visit the *Colleagues* online archive at www.aae.org/colleagues for back issues of the newsletter.



©2015, American Association of Endodontists
211 E. Chicago Ave., Suite 1100
Chicago, IL 60611-2691

Phone: 800/872-3636 (U.S., Canada, Mexico) or 312/266-7255
Fax: 866/451-9020 (U.S., Canada, Mexico) or 312/266-9867

Email: info@aae.org Website: www.aae.org

 www.facebook.com/endodontists
 @savingyourteeth
 www.youtube.com/rootcanalspecialists