

Anatomy of the Pulp-Chamber Floor

Paul Krasner, DDS, and Henry J. Rankow, DDS

Locating the number and position of orifices on pulp-chamber floors can be difficult. This is especially true when the tooth being treated is heavily restored, malposed, or calcified. After evaluating 500 pulp chambers of extracted teeth, new laws for finding pulp chambers and root-canal orifices are proposed. The use of these laws can aid in the determination of the pulp-chamber position and the exact location and number of root canals in any individual tooth.

Endodontic therapy is essentially a surgical procedure, a micro-neurologic surgical procedure. Because the fundamental foundation on which all surgical procedures are performed is an intimate knowledge of anatomy, any attempt to perform endodontic therapy must be preceded with a thorough understanding of the anatomy of both the pulp chamber and the root-canal system. Attempting to treat the root-canal system without detailed anatomic description would be the equivalent of a physician looking for an appendix without ever having read *Gray's Anatomy*.

Literature describing pulp-chamber anatomy in the past has been very general and offered little specificity for determining orifice number and location. Discussions, in print and in the classroom, typically present generalizations about the average number of canals in different teeth. However, the average number of canals in a tooth is of no value when dealing with an individual tooth. Likewise, the description of the location of canal orifices has often been presented in a nonsystematic manner. Essentially, most advice has been to make an access in an appropriate position in the clinical crown and look for the orifices in the hope that they are seen. If they are not easily seen, there is little guidance for safely locating them without the danger of excessive tooth destruction or even perforation. As any experienced operator knows, looking for root-canal orifices in teeth that are heavily restored, cariously broken down, or gouged by previous accessing is very difficult. In these cases, normal anatomy is often severely distorted and the advice given in articles and textbooks is of little value.

We felt, after accessing thousands of teeth in our practices, that there are consistent, identifiable, anatomic configurations of the pulp chamber and the pulp-chamber floor. This study was undertaken to observe the anatomy of the pulp chamber and the pulp-chamber floor and to see if specific, consistent landmarks or configurations exist and are quantifiable. If these landmarks exist, then the task of locating orifices can be made more systematic and,

therefore, with greater certainty. This could aid in a rational approach to root-canal therapy.

MATERIALS AND METHODS

A total of 500 extracted, permanent, human teeth were used. The teeth were equally distributed between maxillary and mandibular anteriors, premolars, and molars. The teeth had a wide variety of crown conditions: virgin crowns, small restorations, large restorations, metal and porcelain crowns, and caries. A total of 400 teeth had their crowns cut off horizontally at the level of the CEJ so that the outline of the pulp chamber relative to the external surface of the tooth could be observed. Fifty teeth were sectioned in a buccolingual direction through the crown and the roots. Fifty teeth were sectioned in a mesiodistal direction through the crown and the roots. Each cut section was irrigated with water, dried, and examined. Two observers examined each specimen independently and recorded all observed anatomical relationships. These relationships included orifice location, size, color, and shape. These observations were then correlated and any consistent patterns were listed. Lines were drawn on horizontal sections to observe the relationships more easily.

RESULTS

Two categories of anatomic patterns were observed: relationships of the pulp chamber to the clinical crown and relationships of orifices on the pulp-chamber floor.

Relationships of the Pulp Chamber to the Clinical Crown

The following observations were noted:

1. The pulp chamber was always in the center of the tooth at the level of the CEJ (Figs. 1–3).
2. The walls of the pulp chamber were always concentric to the external surface of the crown at the level of the CEJ (Fig. 2).
3. The distance from the external surface of the clinical crown to the wall of the pulp chamber was the same throughout the circumference of the tooth at the level of the CEJ (Fig. 3).

These observations were consistent enough that several anatomic laws could be formulated:

Law of centrality: the floor of the pulp chamber is always located in the center of the tooth at the level of the CEJ (Figs. 1–3).

Law of concentricity: the walls of the pulp chamber are always

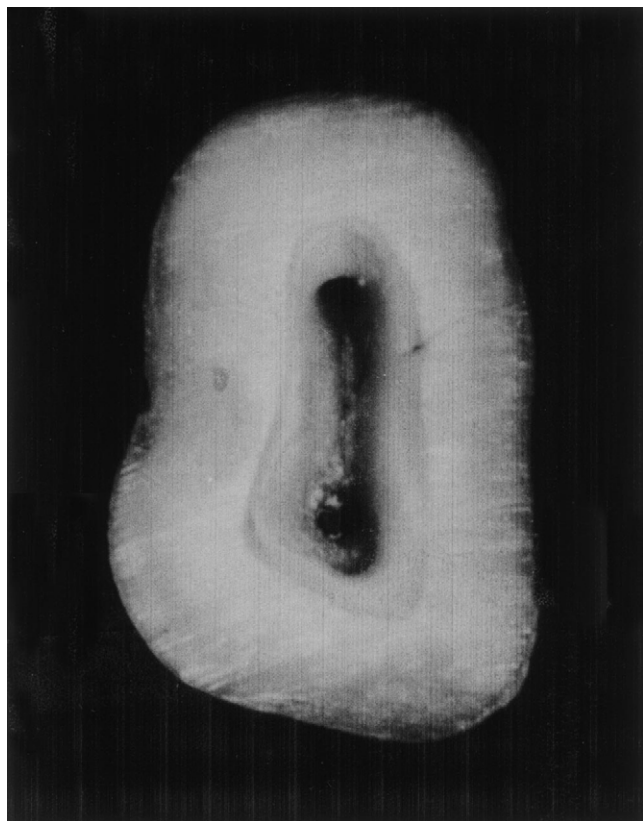

FIG 1. Cut specimen of a mandibular molar showing the centrality of the pulp chamber.

concentric to the external surface of the tooth at the level of the CEJ (Figs. 1–3).

Law of the CEJ: the CEJ is the most consistent, repeatable landmark for locating the position of the pulp chamber.

Relationships on the Pulp-chamber Floor

The following observations were noted relative to all teeth:

1. The floor of pulp chamber is always a darker color than the surrounding dentinal walls (Fig. 4A).
2. This color difference creates a distinct junction where the walls and the floor of the pulp chamber meet (Figs. 4B and 5).
3. The orifices of the root canals are always located at the junction of the walls and floor (Figs. 5 and 6).
4. The orifices of the root canals are located at the angles in the floor wall junction [Fig. 6 (A and B)].
5. The orifices lay at the terminus of developmental root fusion lines, if present [Fig. 7 (A–C)].
6. The developmental root fusion lines are darker than the floor color (Fig. 7A).
7. Reparative dentin or calcifications are lighter than the pulp-chamber floor and often obscure it and the orifices (Fig. 8).

The following observations were noted relative to all teeth except maxillary molars:

1. If a line is drawn in a mesial-distal direction across the center of the floor of the pulp chamber, the orifices of the canals on either side of the line are equidistant [Fig. 9 (A and B)].

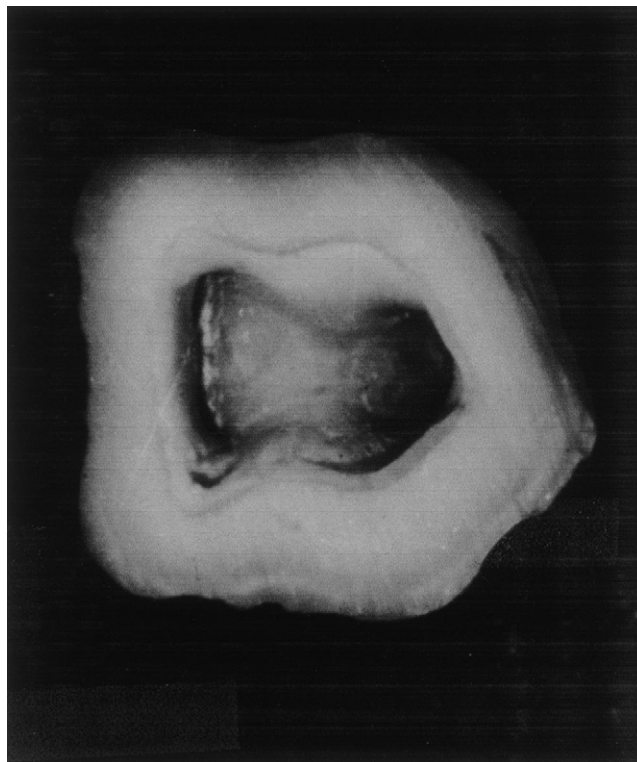


FIG 2. Cut specimen of a mandibular molar showing the concentricity of the pulp-chamber walls to the external tooth surface at the CEJ.

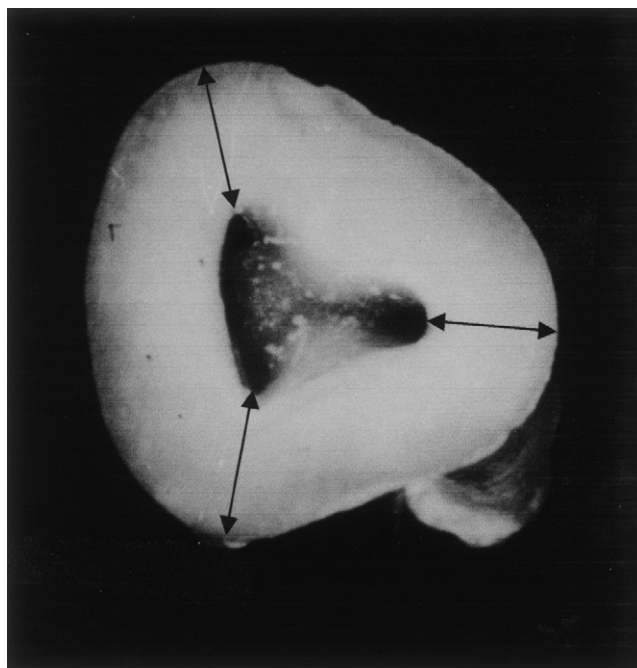


FIG 3. Cut specimen of a mandibular molar showing the equality of the distance of the pulp chamber walls from the external root surface (arrows).

2. If a line is drawn in a mesial-distal direction across the center of the floor of the pulp chamber, the orifices of the canals on either side are perpendicular to it [Fig. 9 (C and D)].

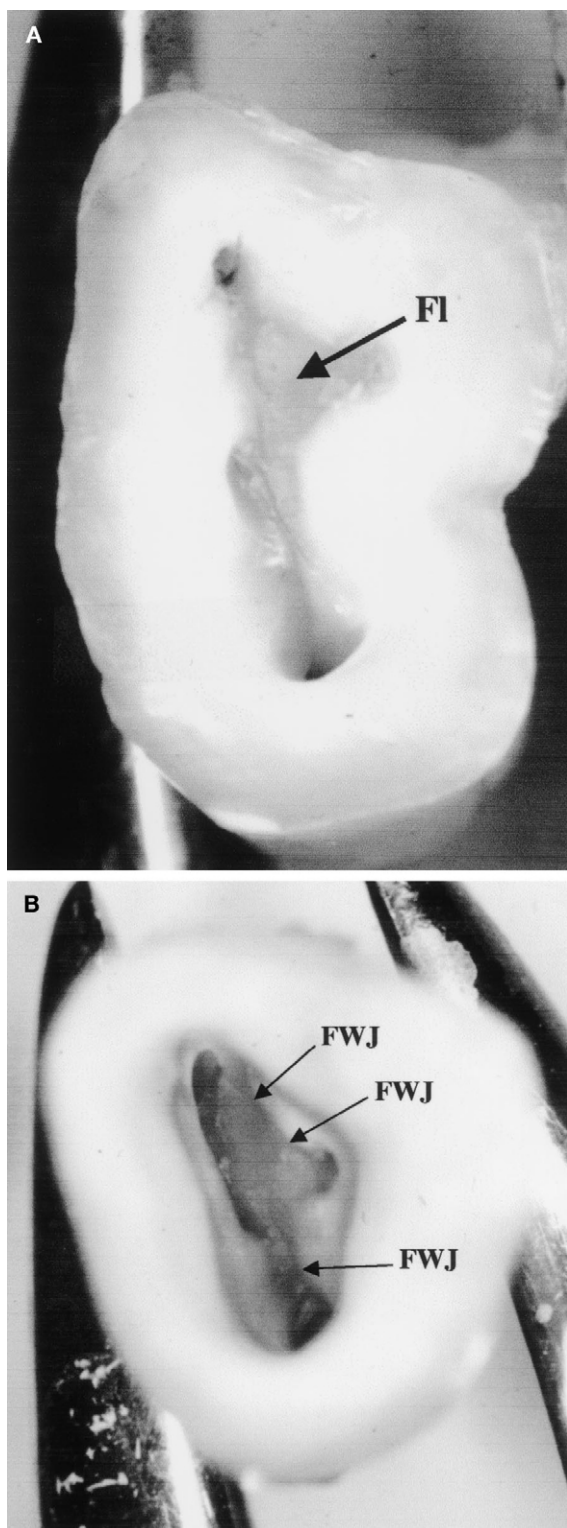


FIG 4. (A) Cut specimen showing the dark chamber floor (FI). (B) Cut specimen showing the junction of the light walls and the dark floor (FWJ).

These observations were consistent enough that several anatomic laws regarding the pulp chamber floor can now be proposed:

Law of symmetry 1: except for maxillary molars, the orifices of the canals are equidistant from a line drawn in a mesial distal direction through the pulp-chamber floor [Fig. 9 (A and B)].

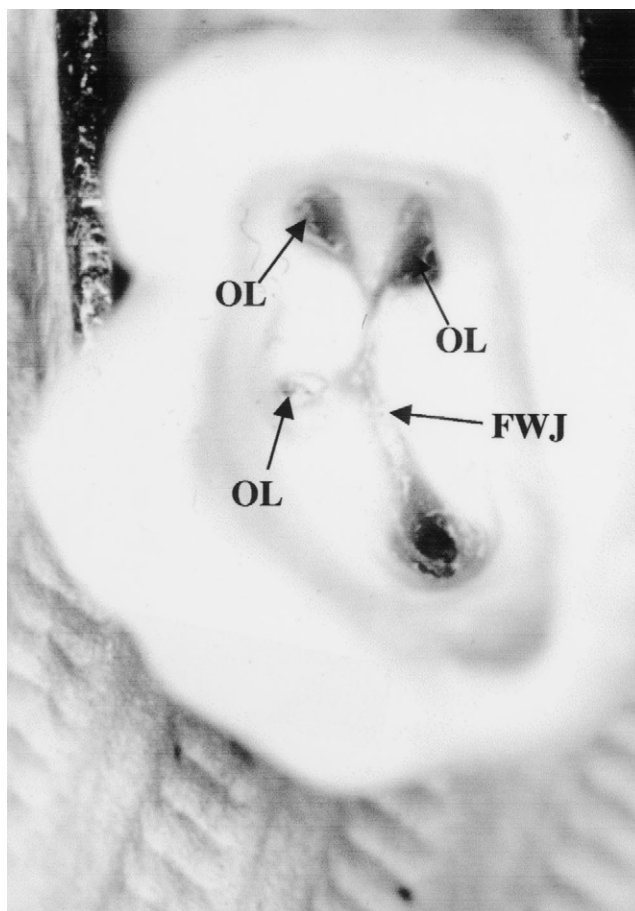


FIG 5. Cut specimen showing the orifices (OL) located at the junction of the floor and walls (FWJ).

Law of symmetry 2: except for the maxillary molars, the orifices of the canals lie on a line perpendicular to a line drawn in a mesial-distal direction across the center of the floor of the pulp chamber [Fig. 9 (C and D)].

Law of Color Change: the color of the pulp-chamber floor is always darker than the walls (Fig. 4A).

Law of orifice location 1: the orifices of the root canals are always located at the junction of the walls and the floor (Fig. 5).

Law of orifice location 2: the orifices of the root canals are located at the angles in the floor-wall junction (Figs. 5 and 6A).

Law of orifice location 3: the orifices of the root canals are located at the terminus of the root developmental fusion lines (Fig. 7A).

A summation of all of the laws and rules are shown in [Fig. 10 (A and B)].

DISCUSSION

Definite patterns and relationships of the pulp chamber and on the pulp-chamber floor were observed. From these observations, specific laws have been proposed to help the clinician more systematically locate pulp chambers and the number and position of root-canal orifices on the pulp-chamber floor.

Most practitioners begin root-canal treatment with preconceived ideas about the anatomy and position of pulp chambers and roots canals. These ideas are based on stylized pictures of virgin teeth presented in textbooks. Access to the pulp chamber is usually

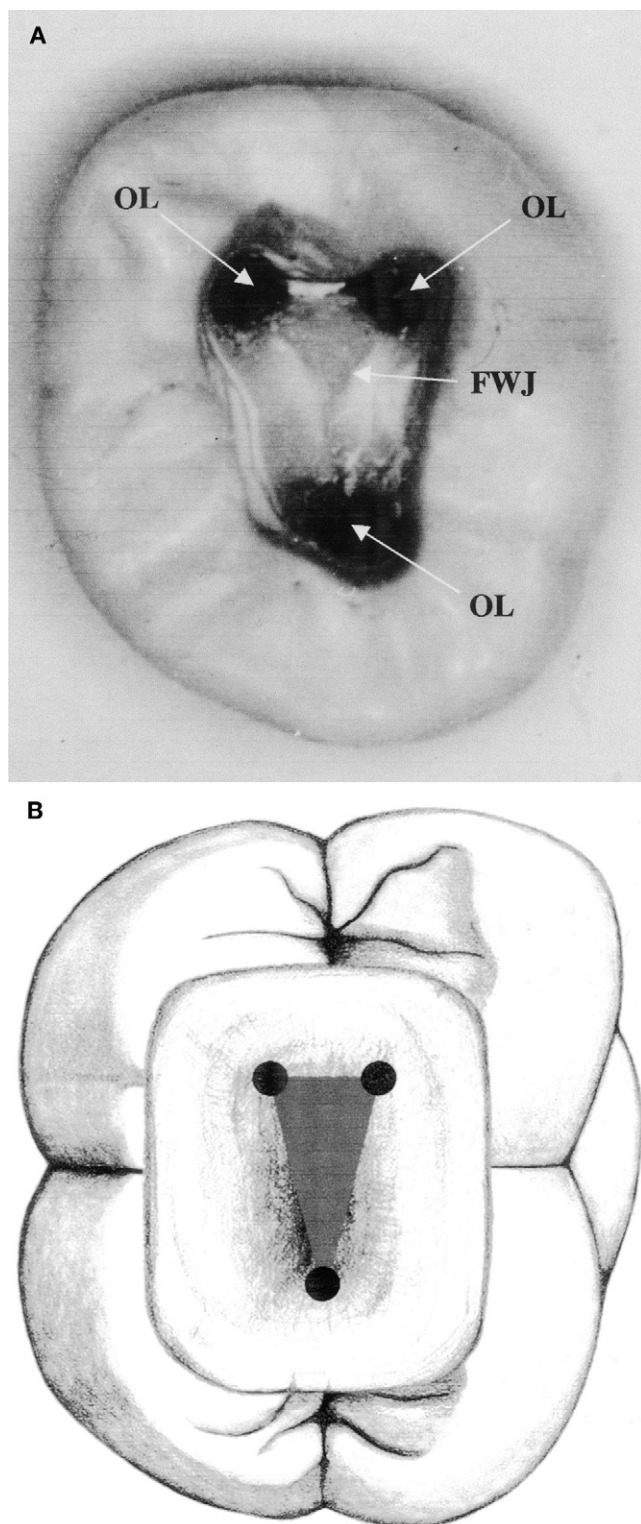


FIG 6. (A) Cut specimen showing the orifices located (OL) at the angles in the chamber floor and floor-wall junction (FWJ). (B) Diagram of mandibular molar showing orifice location at the angles of the chamber floor and floor-wall junction.

recommended based on this ideal anatomy and the clinician works from "outside-in." However, after restoration of a tooth, the occlusal anatomy may have no relevance to the position of the underlying pulp chamber (e.g. that of a porcelain-fused-to-gold

crown). Using this artificial anatomy as a guide to where to begin accessing the tooth may lead to perforation in a lateral direction. In this study, the CEJ was the most consistent anatomic landmark observed. Regardless of how much clinical crown was lost or how extensive the crown restoration, the CEJ could always be observed. Given the observation that the CEJ is the most reliable guide for access, we encourage the clinician to ignore the clinical crown as a guide in directing access, and instead, recommend the use of the CEJ as the ultimate "Northstar" for locating the pulp chamber.

Knowledge of the law of centrality will help prevent crown perforations in a lateral direction. Because the pulp chamber is always centrally located at the level of the CEJ, the operator can use the CEJ as a circular target regardless of how nonanatomic the clinical crown or restoration may be. Even if the crown sits at an obtuse angle to the root, the CEJ can still be a reliable landmark for locating the pulp chamber.

The law of concentricity will help the clinician to extend his access properly. When the clinician observes a bulge of the CEJ to the mesiobuccal (Fig. 11), either visually or by probing, he will then know that the pulp chamber also will extend in that direction. If the tooth is narrow mesiodistally, then the clinician will know that the pulp chamber will be narrow mesiodistally (Fig. 12).

This study has resulted in observations regarding the pulp-chamber floor that have not been previously described. These observations were correlated to propose laws that can aid practitioners in determining the number and position of orifices of root canals of any tooth. Use of these laws takes the guesswork out of the task of finding canals. The only requirement for proper use is that the access to the chamber be completed so that the entire floor of the pulp chamber is visible without any overlying obstruction.

The law of color change provides guidance to determine when the access is complete. Proper access is complete only when the entire pulp-chamber floor can be visualized. The operator knows that he has completed the access when he can delineate the junction of the pulp-chamber floor and the walls 360 degrees around the chamber floor (Fig. 13). Because a distinct light-dark junction is always present, if it is not seen in one portion of the chamber floor, the operator knows that additional overlying structure must be removed. This structure could be restorative material, reparative dentin, or even overlying pulp chamber roof. This interference with the complete visualization of the walls can be seen in Figs. 8 and 14.

After this junction is clearly seen, all of the laws of symmetry and orifice location can be used to locate the exact position and number of orifices. The laws of symmetry can be invaluable in determining the exact position of canals and often indicate the presence of an additional unexpected canal. Look at the position of the orifices on the pulp chamber floor in [Fig. 15 (A and B)]. Knowledge of the laws of symmetry 1 and 2 immediately indicates the presence of a fourth canal. Indeed, it not only implies the presence of a fourth canal but exactly where it is located [Fig. 15 (C and D)].

The law of orifice locations 1 and 2 can be used to identify the number and position of the root-canal orifices of the tooth. Because all of the orifices can only be located along the floor-wall junction, black dots, indentations, or white dots that are observed anywhere else (e.g. the chamber walls or in the dark chamber floor) must be ignored to avoid possible perforation. The law of orifice location 2 can help to focus on the precise location of the orifices. The vertices or angles of the geometric shape of the dark chamber floor will specifically identify the position of the orifice. If the canal is calcified, then this position at the vertex will indicate with certainty

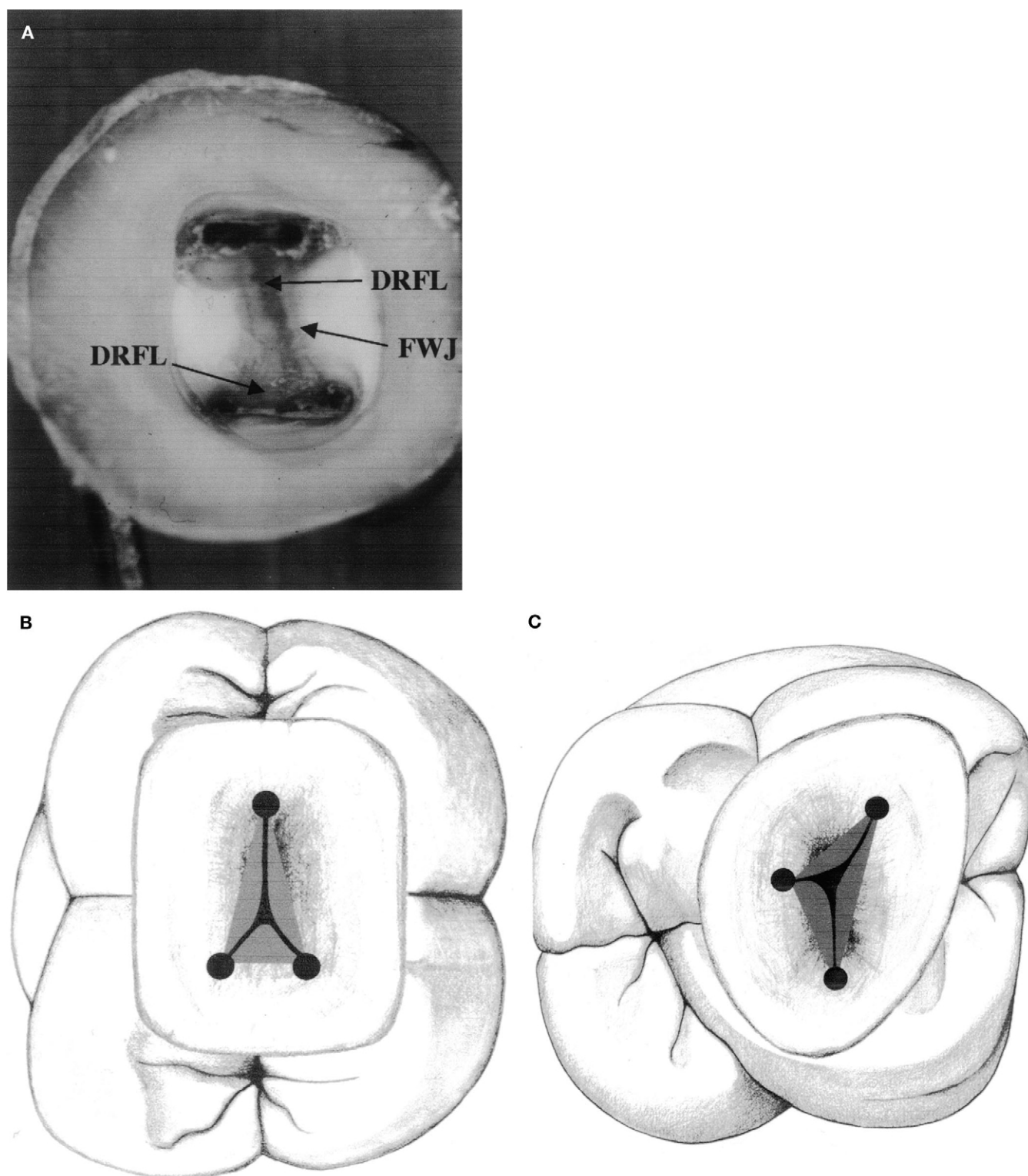


FIG 7. (A) Cut specimen showing the developmental root fusion lines (DRFL) and the floor-wall junction (FWJ). (B) Developmental root fusion lines of a mandibular molar. (C) Developmental root fusion lines of a maxillary molar.

where the operator should begin to penetrate with his bur to remove reparative dentin from the upper portion of the canal (Fig. 15A,E). The law of orifice locations 1 and 2, in conjunction with the law of color change, is often the only reliable indicator of the

presence and location of second canals in mesiobuccal roots of maxillary molars [Fig. 16 (A and B)]. Look at the floor anatomy in Fig. 17A. Along the floor-wall junction, there is an angle in the floor geometry between the mesiobuccal and palatal orifices. The

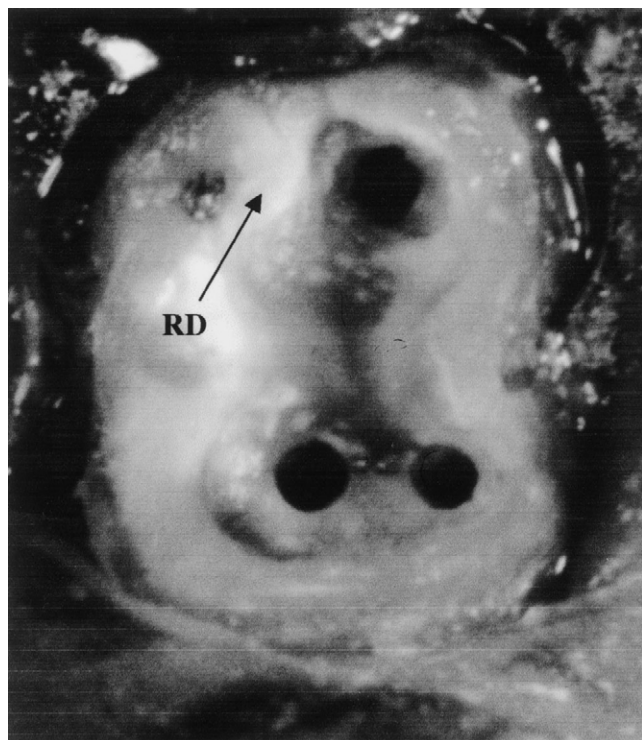


FIG 8. Cut specimen of a mandibular molar showing light colored reparative dentin on chamber floor.

laws of orifice locations 1 and 2 dictate the presence of a mesio-palatal orifice (Fig. 17B). This orifice can be any distance from either orifice but must be along this junction line.

The laws of symmetry 1 and 2, color change, orifice locations 1 and 2 can be applied to any tooth. They are especially valuable when unexpected or unusual anatomy is present. Notice the diagrammatic representation of a chamber floor of a maxillary second premolar (Fig. 18A). Knowledge of the chamber-floor-anatomy laws immediately leads the observer to realize that there are three canals in this tooth (Fig. 18B).

Another example of the value of chamber-floor-anatomy knowledge can be seen in Fig. 19A, which shows a mandibular molar that has been sectioned at the CEJ. Using the laws of chamber-floor anatomy, the observer is guided to realize that there are only two orifices in this tooth. Their positions are indicated in Fig. 19B.

The relationships that we observed occurred with very high frequency. Over 95% of the specimens we observed demonstrated all of the laws. There were, however, exceptions. Mandibular

second and third molars were especially deviant. Approximately 5% of these teeth most often showed a different anatomy. This anatomy has often been described in the literature and has been observed clinically as a C-shaped canal. Even in these teeth, however, the laws of color change and orifice location 1 apply. The laws of symmetry 1 and 2 and orifice locations 2 and 3, however, are not observed in them.

The ramifications and use of these laws are far ranging and manifold. A specific technique has been developed using the laws to identify the number and position of root-canal orifices in teeth and especially those in heavily calcified pulp chambers. This technique will be discussed in a subsequent article.

SUMMARY

The cause of most endodontic failures is inadequate biomechanical instrumentation of the root-canal system. This can result from inadequate knowledge of root-canal anatomy. Because one can never know before treatment begins how many root canals are in a tooth, only a systematic knowledge of pulp-chamber-floor anatomy can provide greater certainty about the total number of root canals in a particular tooth. Knowing the average number of root canals in a tooth has limited clinical relevance to the specific tooth being treated. If one or more of the root canals remains undiscovered, failure potential increases. Therefore, the only way to provide the best environment for success is to establish the full extent of the root-canal system. This study showed that consistent patterns of anatomy of both the chamber and the pulp-chamber floor exist. These consistent patterns were analyzed and from them laws were proposed. These laws can be used to help practitioners identify the total number of canals in any tooth and their specific orifice location on the pulp-chamber floor.

With the proposal of a systematic anatomic approach to pulp chamber and root-canal-orifice location, the practice of endodontics can now be based on fundamental surgical anatomic principles. As in other medical specialties, knowledge of basic concepts such as these laws is more important than the tools for measurement. With this anatomic basis, the use of supplementary instruments, such as microscopes, can now be rationally used, not as gimmicks, but as valuable tools for conducting treatment.

Drs. Krasner and Rankow are professors, Temple University, School of Dentistry

The authors thank all of our graduate students for their never-ending interest in this subject, Dr. Peter Friedman for editing help, and Mary Ferrell for inspiring us to complete this article.

Address requests for reprints to Dr. Paul Krasner, 18 S. Roland Street, Pottstown, PA 19464.

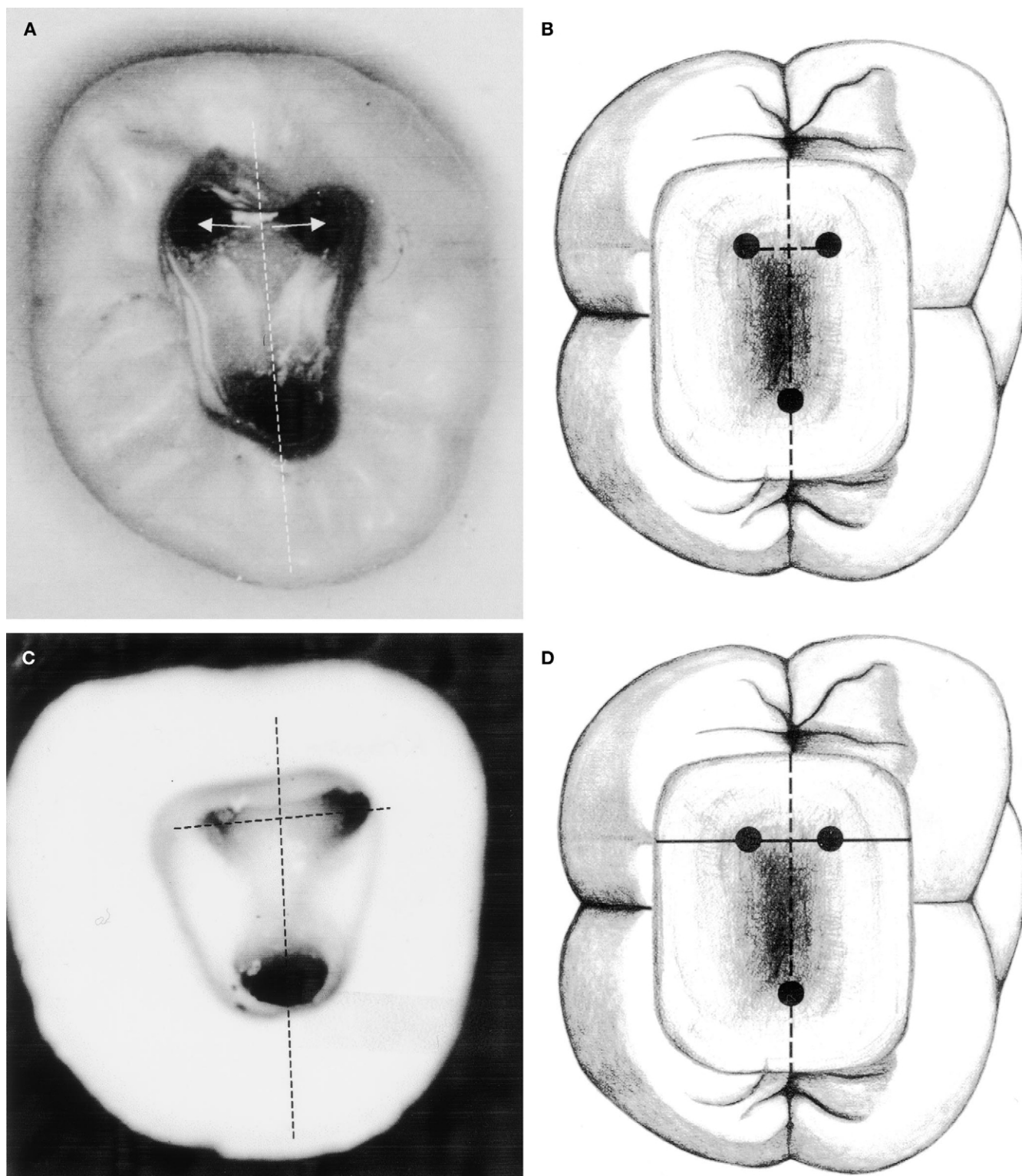


FIG 9. (A) Cut specimen of mandibular molar showing equidistance of orifices from mesiodistal line. (B) Mandibular molar showing equidistance of orifices from mesiodistal line. (C) Cut specimen of mandibular molar showing orifices perpendicular to mesiodistal line. (D) Mandibular molar showing orifices perpendicular to mesiodistal line.

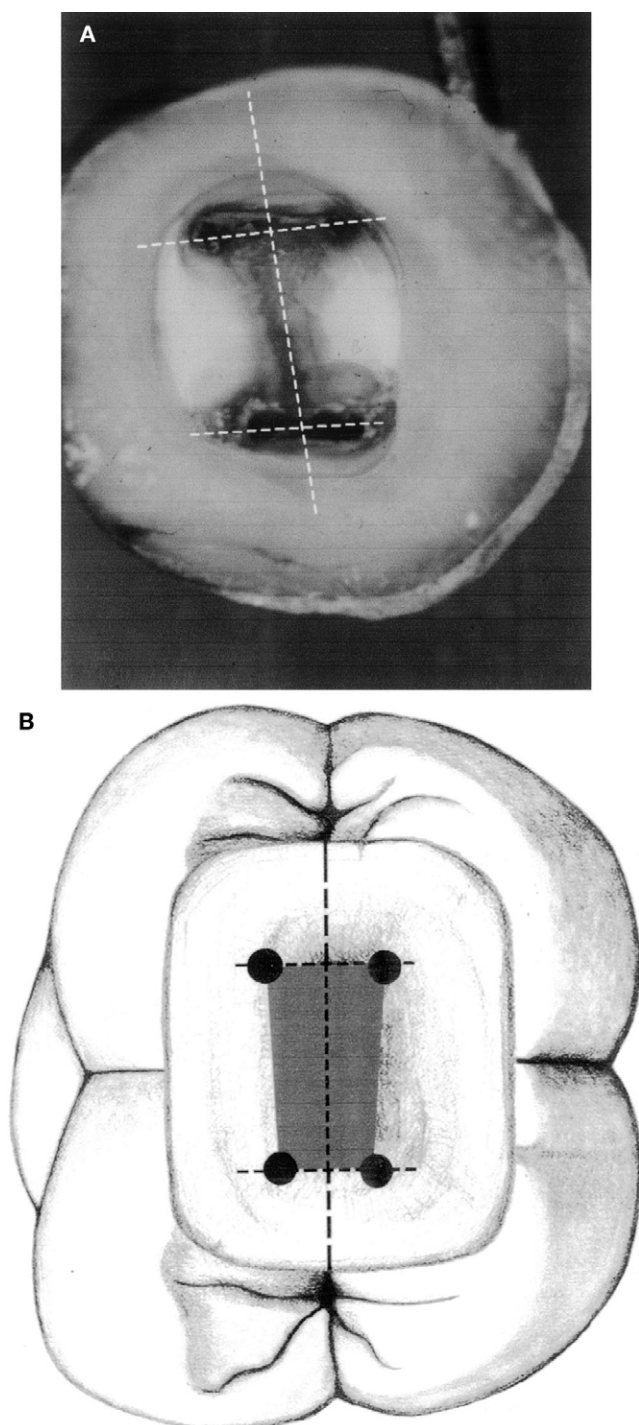


FIG 10. (A) Cut specimen showing the laws of symmetry 1 and 2 and orifice locations 1, 2, and 3. (B) Laws of symmetry 1 and 2 and orifice locations 1, 2, and 3.

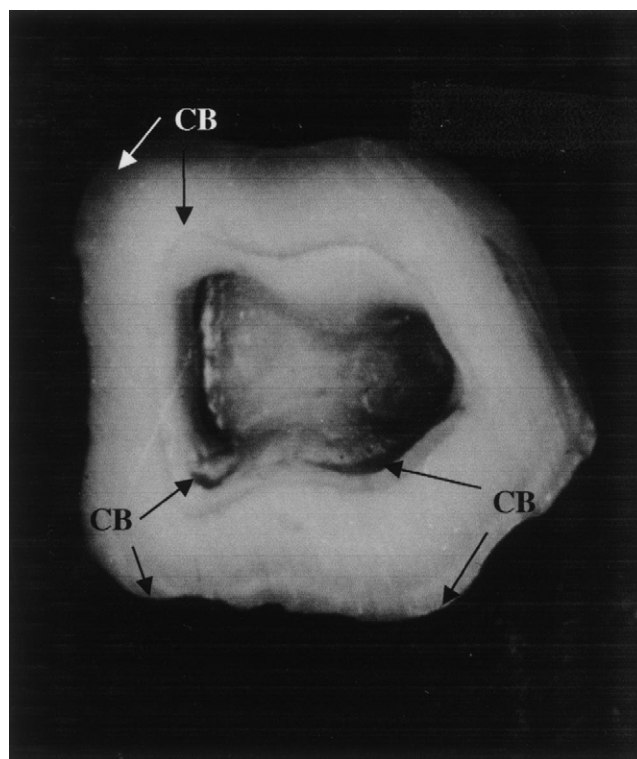


FIG 11. Cut specimen showing CEJ bulge (CB) with concentric chamber wall.

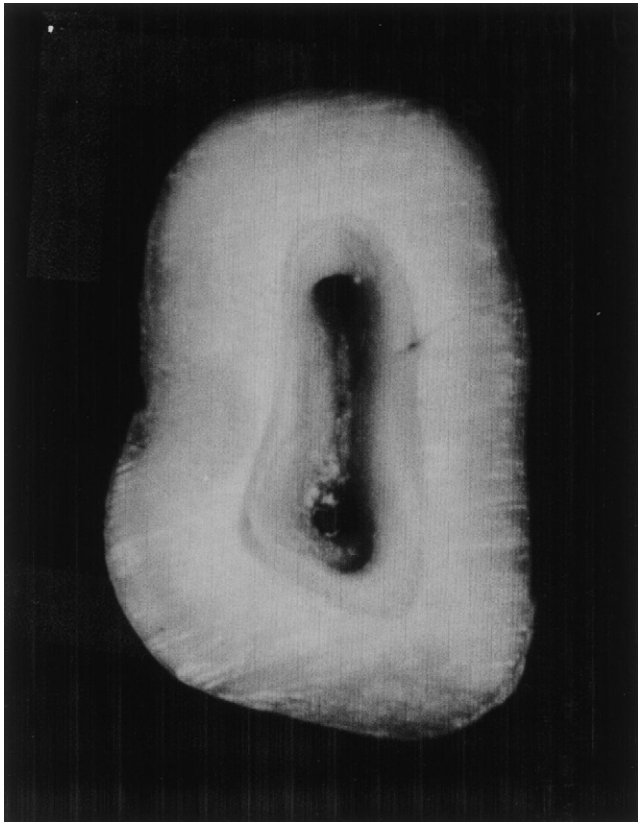


FIG 12. Cut specimen showing mesiodistally narrow pulp chamber in mesiodistally narrow clinical crown (cut at CEJ).

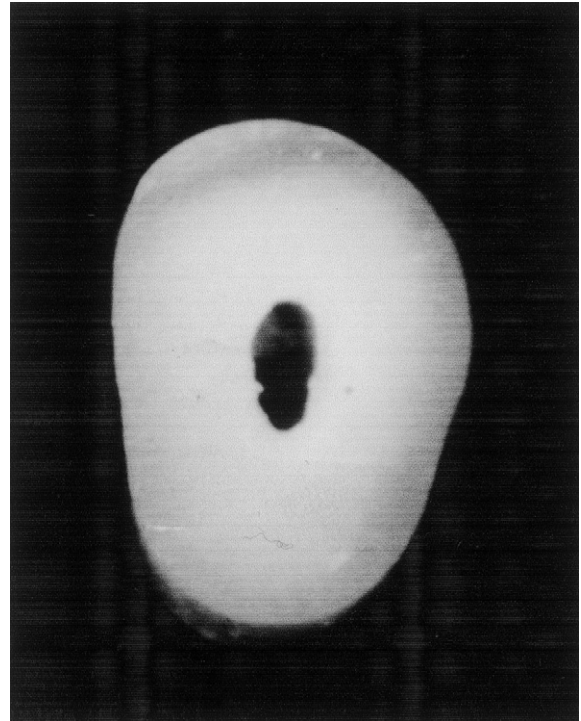


FIG 14. Cut specimen shows inadequate access.

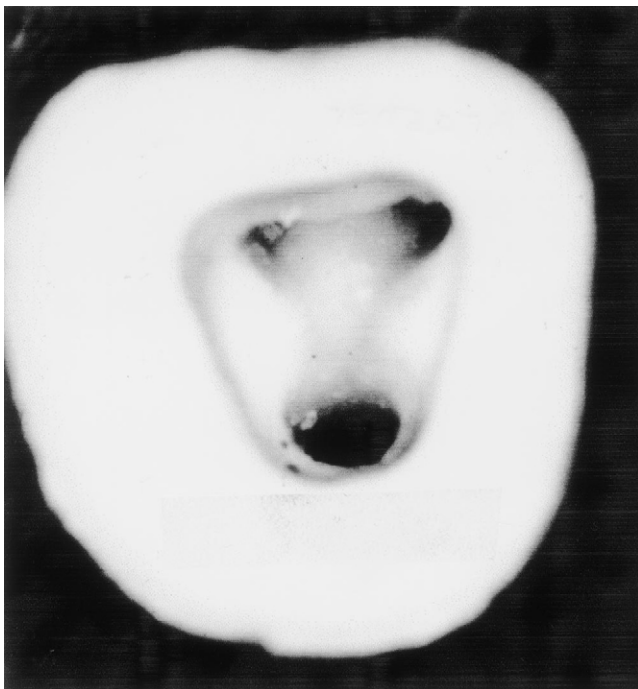


FIG 13. Cut specimen showing complete access, which allows visualization of chamber floor meeting chamber walls 360 degrees.

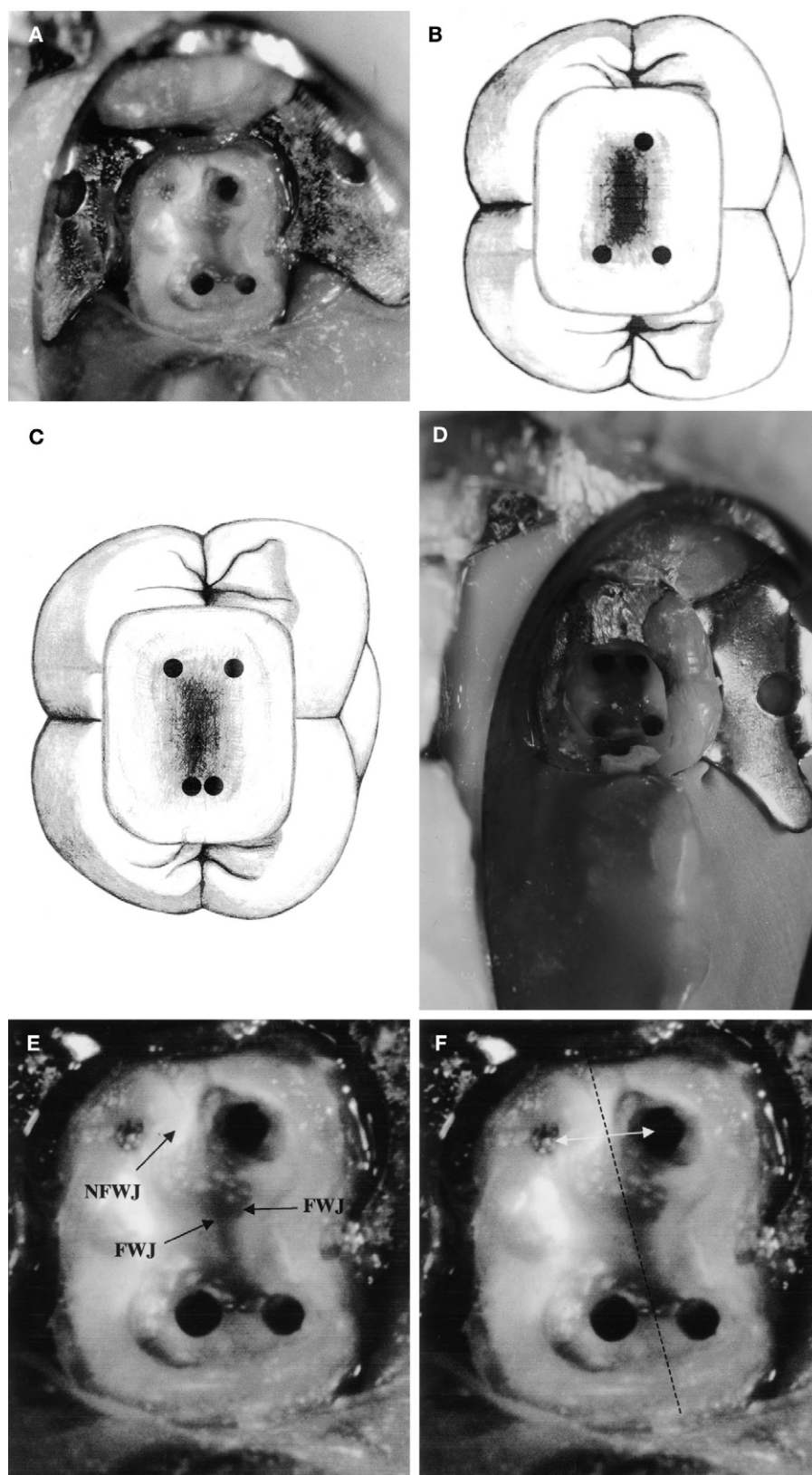


FIG 15. (A) Cut specimen with pulp-chamber-floor anatomy that, through the laws of symmetry and orifice location, indicates the presence of a fourth canal. (B) Pulp-chamber-floor anatomy, which, through the laws of symmetry and orifice location, indicates the presence of a fourth canal. (C) Cut specimen of a mandibular molar that shows the presence and position of a fourth canal. (D) Mandibular molar that shows the presence and position of a fourth canal. (E) Cut specimen showing floor-wall junction (FWJ) and the lack of observation of distinct floor-wall junction (NFWJ). (F) Cut specimen showing use of law of symmetry (arrows) to show where to begin to remove overlying roof or reparative dentin.

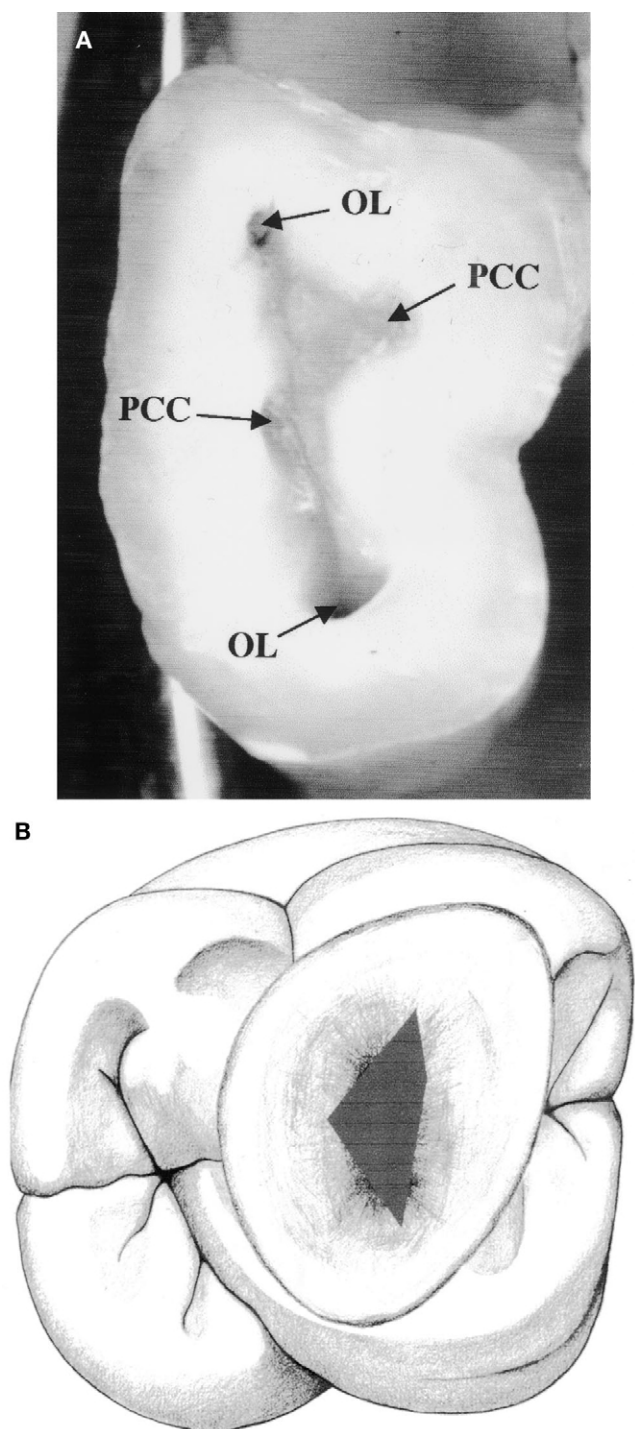


FIG 16. (A) Cut specimen of maxillary molar that uses laws of orifice location to show potential sites of calcified canals (PCC) and orifice location (OL). (B) Maxillary molar that uses laws of orifice location to show potential sites of calcified canals (PCC).

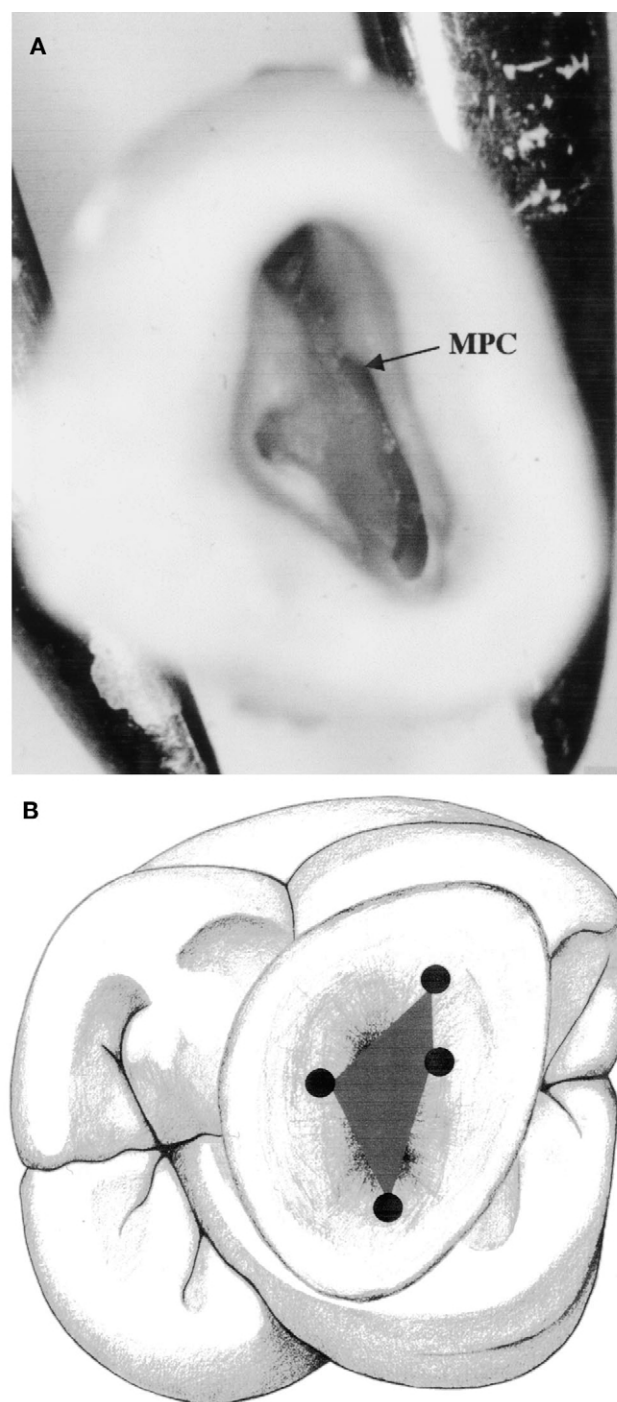


FIG 17. (A) Cut specimen showing position of a mesiopalatal orifice (MPC) after the laws of orifice location. (B) Position of a mesiopalatal orifice (MPC) after the laws of orifice location.

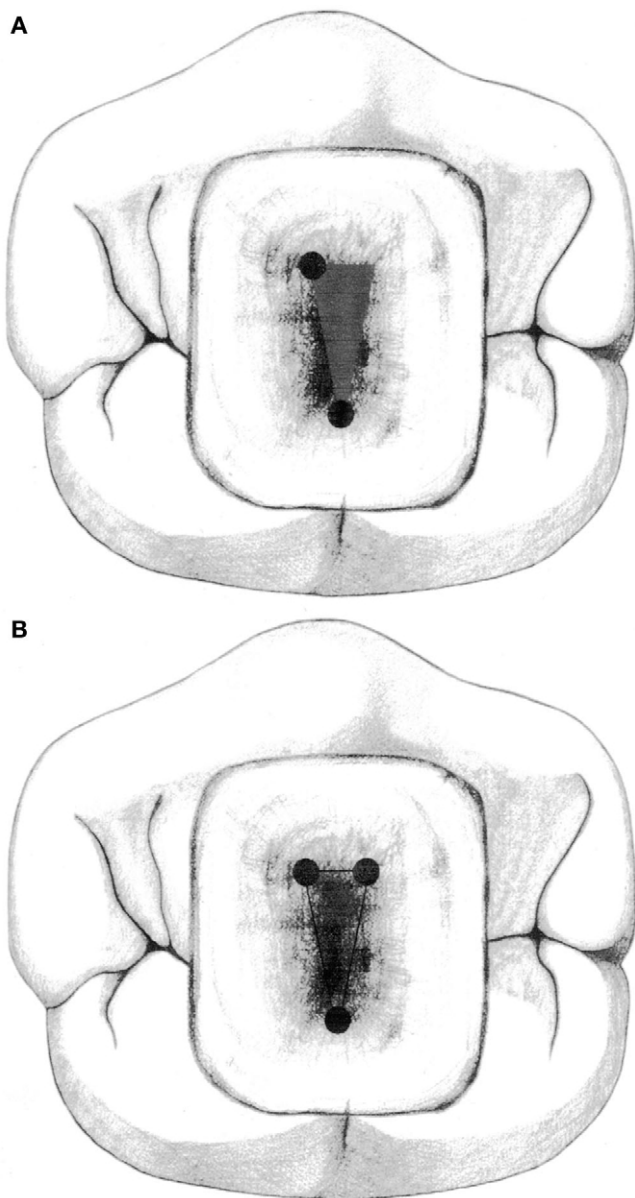


FIG 18. (A) Premolar access and pulp-chamber floor with an anatomy that, using the laws of symmetry and orifice location, shows the presence of a third canal. (B) Premolar access and pulp chamber that show the presence and position of a third canal.

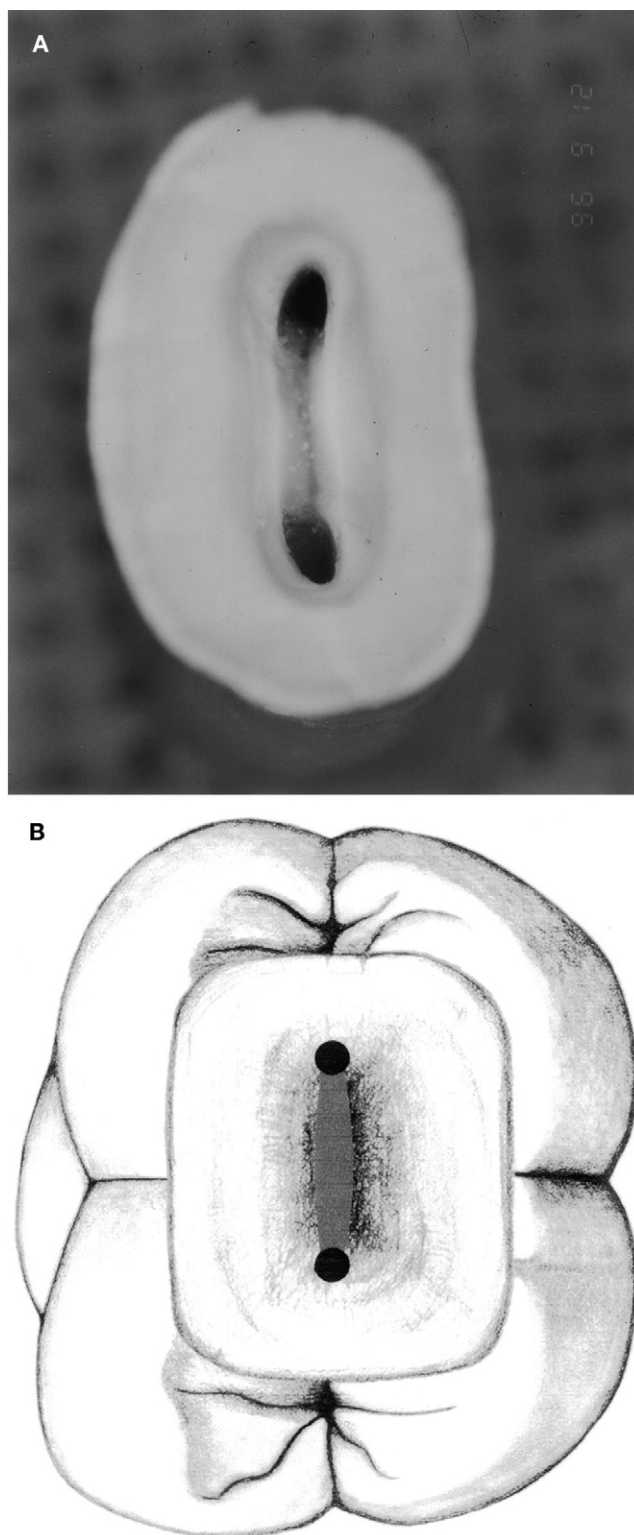


FIG 19. (A) Cut specimen of a mandibular molar that, using the laws of symmetry and orifice location, shows the presence of two orifices. (B) Mandibular molar that, using the laws of symmetry and orifice location, shows the presence of two orifices.