

# Maxillary Sinusitis of Endodontic Origin

## Introduction

The American Association of Endodontists is dedicated to excellence in endodontics and promoting the highest standards of patient care. This following position statement is intended to define and outline Maxillary Sinusitis of Endodontic Origin (MSEO), deliver guidelines for its diagnosis and appropriate treatment, and provide a standard for all dental and medical practitioners who undertake the responsibility of managing patients with this condition.

The relationship between dental infections and sinus disease is widely recognized in both the dental and medical literature. Despite extensive scientific recognition and reported high prevalence, periapical infection manifesting in the maxillary sinus remains under-appreciated and frequently goes undiagnosed by dentists, otolaryngologists, and radiologists alike, with its sequelae often misdiagnosed as sinogenic sinusitis. Recognition of MSEO is critical as failure to identify and properly manage the endodontic source pathology will result in the persistence of sinus disease, the failure of medical sinus therapies, and the potential advancement to more serious or even life-threatening cranio-facial infections.

## Incidence and Recognition

The pathological extension of dental disease into the maxillary sinus is well documented in the dental and medical literature and was first referred to by Bauer in 1943 as *maxillary sinusitis of dental origin* (MSDO).<sup>1</sup> Numerous investigators since have discovered that this is a prevalent and common disease process.<sup>2-23,25</sup> Abrahams et al.<sup>2</sup> have reported that infections of maxillary

posterior teeth show maxillary sinus pathology in 60% of the cases, while Mattila<sup>3</sup> found sinus mucosal hyperplasia present in approximately 80% of teeth with periapical osteitis. Obayashi et al.<sup>4</sup> found maxillary sinus mucosal changes in 71.3% of patients with infections originating in the maxillary canines, premolars and molars.

While it has often been quoted and generally accepted that dental infections account for approximately 10 to 12% of all cases of maxillary sinusitis,<sup>5-9</sup> the primary source for this figure provides no epidemiological data to support it.<sup>5,10</sup> More recent literature strongly supports the conclusion that the incidence of MSDO, also termed odontogenic sinusitis, is likely much higher, particularly in chronic cases. Melen et al.<sup>11</sup>, in a study of 198 patients with 244 cases of chronic bacterial maxillary sinusitis, found a dental etiology in 40.6% of the cases. Maillet et al.<sup>12</sup> reviewed 82 cone beam computed tomography (CBCT) scans that had findings consistent with maxillary sinusitis for evidence of a dental pathology and concluded that over 50% of these cases were of dental etiology. Bomeli et al.<sup>13</sup> found that the more severe the sinus disease, the more likely it was to be associated with dental pathology, with up to 86% of severely affected maxillary sinuses having a dental etiology for the infection. Matsumoto et al.<sup>14</sup> found that 72% of unilateral sinusitis cases had an odontogenic source.

Despite the reported high prevalence of MSDO, and the persistence of sinus disease if the odontogenic source remains, this condition frequently goes unrecognized by radiologists, dentists, and otolaryngologists - Ear, Nose and Throat (ENT) specialists.<sup>15</sup> In two separate case series evaluating odontogenic sinusitis,

approximately two-thirds of the identifiable dental pathology went unreported by radiologists on sinus computed tomography (CT) scans.<sup>16,17</sup> It was also found that routine general dental examination using periapical radiographs failed to diagnose odontogenic maxillary sinusitis in 86% of the cases.<sup>16</sup> Melen et al.<sup>11</sup> similarly reported that 56 out of 99 (55%) odontogenic maxillary sinusitis cases were missed on routine dental examination and dental radiography.

Although the medical literature provides ample studies and review articles regarding the high prevalence of odontogenic sinusitis with the specific recommendation for dental or endodontic examination and treatment, published guidelines for the management of sinusitis rarely address the need to rule out or treat a potential odontogenic source. The current *Clinical Practice Guidelines for the Management of Adult Rhinosinusitis*, published by The American Academy of Otolaryngology – Head and Neck Surgery Foundation, makes no mention of the potential for an odontogenic cause for sinusitis, nor does it make any recommendation for a dental or endodontic examination to rule out or treat an odontogenic source for sinusitis.<sup>24</sup> Out of 85 sinusitis guidelines, published between 1998 and 2010, only eleven mentioned an odontogenic cause for sinusitis and only three gave a recommendation for a dental examination.<sup>16</sup> None of the published sinusitis guidelines made the recommendation to refer to endodontic specialists, who are uniquely trained and equipped to diagnose and treat odontogenic infections.

## Presentation and Definitions

Inflammatory responses of the maxillary sinus to dental infection can present with varied symptoms, clinical progression, and radiographic presentations. Odontogenic sinus infections may produce only a minimal, often asymptomatic local reaction in the antral floor periosteum and/or mucosa for months or even years.<sup>25</sup> However, a pathologically altered mucosa is impaired and less resistant than an intact one to infection, and is a pathogenic

factor in the progression to rhinosinusitis.<sup>26,27</sup> Depending on dental pathogenicity, anatomic factors, the extent of mucosal edema, and sinus ostial patency, periradicular inflammation may progress beyond the antral floor causing a partial or total obstruction of the maxillary sinus with symptoms and radiographic presentation common to sinogenic sinusitis. The condition can further ascend to involve the nasal cavity, ethmoid, and frontal sinuses, and in rare, severe cases can spread via the maxillary sinus causing orbital cellulitis, blindness, meningitis, subdural empyema, brain abscess and life-threatening cavernous sinus thrombosis.<sup>4,28-31</sup>

The terms MSDO, odontogenic sinusitis, odontogenic rhinosinusitis, and odontogenic maxillary sinusitis are all used synonymously in the current literature to describe various levels of mucosal inflammation and symptoms, caused by multiple odontogenic etiologies, including periodontal disease, endodontic disease, root fractures, dental implants, dental extractions, oro-antral fistulae, and iatrogenic causes such as extruded dental materials, displaced teeth and foreign bodies.<sup>2,6,7,25,32-35</sup> While these are all odontogenic sources for sinusitis, it is important to distinguish these etiologies from maxillary sinusitis of endodontic origin (MSEO), as they each require markedly different clinical treatments. Furthermore, combining these very different etiologies under a single term can create confusion that may impede understanding of the disease processes and potential post-treatment management. MSEO is a new term, coined with this document, and refers specifically to sinusitis secondary to periradicular disease of endodontic origin, excluding sinusitis secondary to other dental etiologies. Previously termed “the endo-antral syndrome” by Seldon,<sup>18-20</sup> MSEO requires an accurate diagnosis of the condition followed by appropriate endodontic treatment or extraction to remove the source of endodontic pathogens associated with the periapical disease and secondary sinus infection.

## Diagnosis of MSEO

### 1. Dental and Sinonasal History and Symptoms

Diagnosis of MSEO begins with a thorough medical and dental history. The clinician must recognize that patients with MSEO may experience a wide variation of dental and sinonasal symptoms including no symptoms. Common sinonasal symptoms include congestion, rhinorrhea, retrorhinorrhea, facial pain, and foul odor.<sup>36,37</sup> Typical endodontic symptoms such as thermal pain, periapical sensitivity, swelling, and/or draining intraoral sinus tract are often not present with MSEO. Thermal pain is not typically present because source teeth for MSEO are either necrotic or have failing endodontic therapy. Periapical tenderness is typically absent in MSEO because periapical infection is essentially draining into the sinus via fistula, eliminating pressure. For this same reason, swelling or intraoral sinus tracts rarely form. There are of course no absolutes, as multi-rooted teeth have the potential for both sinus and intraoral presentations.

Patients with primary sinonasal symptoms and without localized dental pain will typically first seek care from their primary care physician or ENT specialist who may misdiagnose and treat MSEO as a primary sinus infection since dental infections are easily overlooked during routine ENT examinations.<sup>15,16,37</sup> Physicians must always be aware that a lack of dental symptoms or complaint does not rule out dental etiology for sinusitis, and recognize that current clinical guidelines for the medical management of rhinosinusitis do not offer guidance in this area.<sup>24</sup> Physicians must also recognize that lack of sinonasal symptoms does not rule out a dental etiology for mucosal abnormalities or sinus obstruction. Rhinosinusitis is defined as symptomatic inflammation of the paranasal sinuses and nasal cavity, and therefore management of rhinosinusitis is based primarily on patient symptoms rather than imaging findings.<sup>24</sup> Considering this, mucosal changes and periradicular findings seen on imaging that are not coupled with patient symptoms may

be dismissed as incidental, to the detriment of patients exhibiting dental abscesses and/or associated periapical mucositis. If periapical findings are noted on sinus CT imaging, or sinus floor mucosal changes appear to have potential dental etiology, these patients should be referred to an endodontist for evaluation to rule out or resolve any dental pathology, even if the patient is dentally asymptomatic.<sup>17</sup>

Findings that should raise the suspicion of MSEO are a history of repeated episodes of unilateral maxillary sinus infections, particularly when associated with a patent sinus ostium or previously unsuccessful sinus surgery.<sup>17</sup> A cooperative relationship between endodontists and ENT specialists is imperative for diagnosing MSEO and distinguishing it from sinogenic sinusitis. Endodontists should keep sinonasal disease in mind when diagnosing and treating MSEO, and should not attempt to make a final diagnosis of non-odontogenic sinus disease, nor offer treatment that is outside the scope of dental practice.

### 2. Radiographic Examination

While periapical radiographs are the most widely used imaging modality in endodontics, the posterior maxilla presents significant and unique interpretation challenges when using conventional 2-D imaging.<sup>38</sup> Anatomic structures such as the zygomatic and palatal processes, maxillary sinus cortical floor, and buccal cortical plate are often superimposed onto the dental roots, obscuring or concealing periradicular inflammatory changes. Visualizing the apices of the maxillary posterior teeth is further obscured when maxillary sinus mucosal thickening is present. Conventional periapical radiographs also do not consistently reveal mucosal soft tissue changes or air-fluid levels in the sinus, which are of great diagnostic value in MSEO.<sup>39</sup>

Limited field CBCT imaging has been shown to significantly improve the ability to detect odontogenic sources for sinusitis. In a study by Low et al.<sup>40</sup>, comparing periapical radiography and CBCT for preoperative diagnosis in 74 posterior maxillary teeth consecutively referred

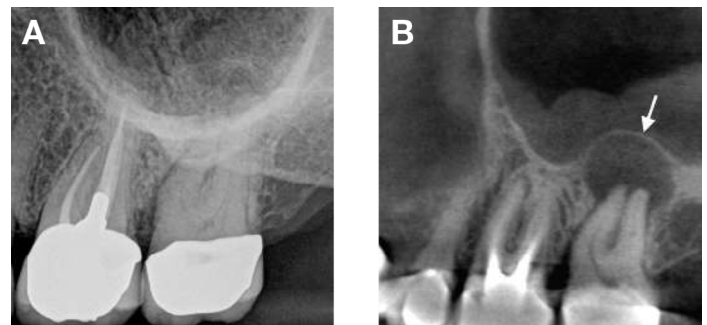
for apical surgery, CBCT revealed 34% more lesions than periapical radiography, as well as significantly more expansion of lesions into the maxillary sinus, sinus membrane thickening, and untreated canals. The same investigation also showed that with the use of CBCT imaging, mucosal changes associated with dental infections were found with a prevalence of 77%, compared to only 19% using conventional radiographs. Lofthag-Hansen et al.<sup>39</sup> compared CBCT and intraoral radiography for the diagnosis of periapical pathology and found that thickening of the mucous membrane of the maxillary sinus was identified more than four times as often with CBCT imaging than with periapical radiographs, and all observers agreed that in 70% of the cases CBCT provided clinically relevant information not found in the periapical radiographs. Shahbazian et al.<sup>41</sup>, examining 145 dental records, found that periapical radiography could only identify approximately 40% of apical periodontitis on posterior maxillary teeth, and 3% of all apical infections extending into the sinus that were seen on CBCT. They also concluded that periapical radiographs are not adequate in observing the anatomical relationship between maxillary molars and the sinus floor.

Periapical inflammation is often responsible for distinct maxillary sinus radiographic changes that differ significantly from typical periradicular radiolucencies observed in alveolar bone.<sup>42</sup> Two unique radiographic findings associated with periradicular inflammation of the sinus mucoperiosteum are *periapical osteoperiostitis* and *periapical mucositis*.<sup>43</sup> Both conditions can progress further to a partial or total sinus obstruction.

### **Periapical Osteoperiostitis (PAO)**

The presence of apical periodontitis adjacent to the maxillary sinus cortical floor will often expand the sinus periosteum, displace it upward into the sinus, and subsequently induce a periosteal reaction that continues to deposit a thin layer of new bone on the inner periphery of the periosteum as it expands. This reactive osteogenesis, termed *periapical osteoperiostitis*

(PAO), forms a thin, hard-tissue dome on the sinus floor and presents on radiographs and CT images as a radiopaque “halo” appearance.<sup>43</sup> (Fig 1) If the inflammatory process continues, the bone deposits can become thicker and expand deeper into the maxillary sinus. PAO lesions may or may not be symptomatic and may be accompanied by varying degrees of adjacent mucosal edema and sinus fluid levels, particularly if a perforation occurs in the periosteum and osseous tissue.<sup>44,45</sup>

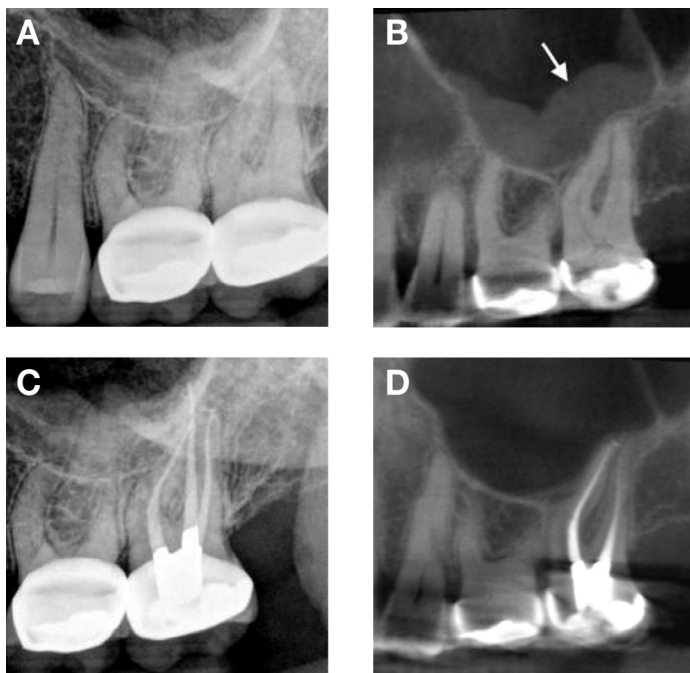


**Figure 1.** Periapical osteoperiostitis. **A.** Periapical radiograph of the posterior left maxilla. Clinical exam confirmed a necrotic maxillary left second molar, however any periapical and sinus abnormalities are obscured by the zygoma. **B.** CBCT image of the same necrotic left maxillary second molar displaying an osteoperiostitis or “halo” lesion (arrow) with associated mucosal edema of the left maxillary sinus.

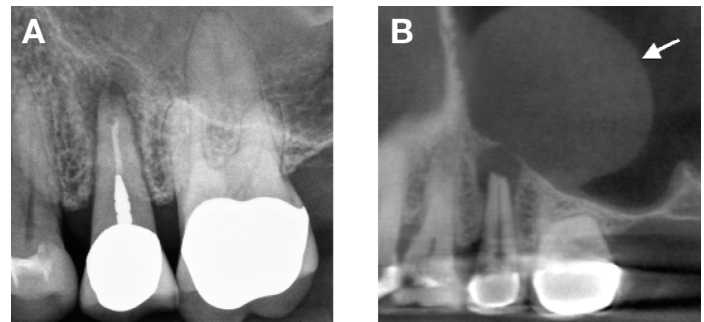
### **Periapical Mucositis (PAM)**

It is not uncommon for the root apices of maxillary posterior teeth to project through the maxillary sinus cortical floor and directly contact the antral mucosa, or for periapical abscesses to perforate the sinus cortical floor and periosteum. Symptomatic or asymptomatic apical periodontitis in direct contact with or adjacent to the antral mucosa will typically produce a localized mucosal tissue edema termed *periapical mucositis* (PAM), which appears on CT imaging as a mucosal thickening or dome-shaped soft tissue expansion in the floor of the sinus directly adjacent to the infected root apex.<sup>43</sup> (Figs 2 and 3) Periradicular inflammation from dental roots not directly adjacent to the sinus mucosa can also cause PAM without any evident inflammatory bone resorption via extension of inflammatory mediators through bone marrow, blood vessels, and lymphatics.<sup>1</sup>

Because there is often no evident osseous destruction or PAO halo, PAM is more difficult to recognize radiographically than typical endodontic lesions and may be misinterpreted as an insignificant or incidental finding. Mucosal edema on the sinus floor and particularly dome-shaped mucosal swellings directly over dental root apices should raise the suspicion of a dental etiology. Clinicians should be mindful, however, that PAM may have a similar appearance to mucous retention cysts, antral polyps, mucosal thickening caused by periodontal disease, and sinogenic mucosal thickening. As with all endodontic diagnoses, a determination of etiology cannot be made based on radiographic examination alone. Careful endodontic clinical examination of pulpal status is imperative to distinguish PAM from other mucosal abnormalities.



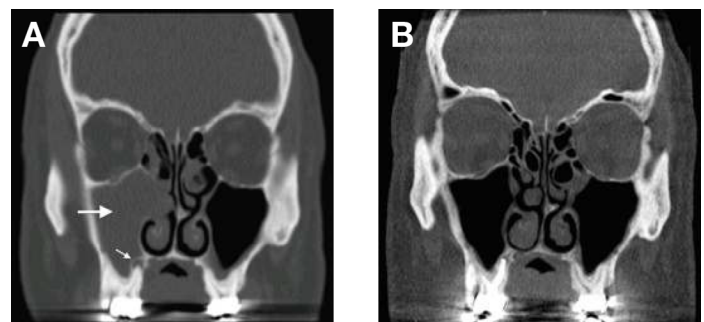
**Figure 2.** Periapical mucositis. **A.** Periapical radiograph of the posterior left maxilla. Clinical exam confirmed a necrotic maxillary left second molar. **B.** CBCT image reveals mucosal edema on the floor of the left maxillary sinus (arrow) with no evident osseous lesion. **C.** Periapical radiograph following endodontic treatment of the second molar. **D.** 3-month post-operative CBCT image showing full resolution of the mucosal edema.



**Figure 3.** Periapical mucositis. **A.** Periapical radiograph of a failing root canal therapy of the maxillary second bicuspid. **B.** CBCT image of the apical periodontitis perforating the antral cortical floor and associated periosteum causing a localized, dome-shaped inflammatory edema of the sinus mucosal tissue (arrow).

### Sinus Obstruction from MSEO

Full or partial sinus obstruction is very evident on sinus CT imaging, but may be more difficult to recognize as having an endodontic etiology. (Fig 4) Careful radiographic examination for evidence of PAO is helpful in making this determination but, as seen with PAM lesions, periapical radiolucencies or osseous changes do not always exist. A history of unilateral sinus obstruction, particularly if recurrent and/or associated with a patent infundibulum is a strong indicator for possible MSEO. Clinical endodontic examination, however, is essential to confirm or rule out a potential endodontic source.<sup>17</sup>



**Figure 4.** MSEO sinus obstruction. **A.** Coronal CT image of a fully obstructed right maxillary sinus (large arrow). The patient had experienced recurrent right maxillary sinus infections and nasal congestion for more than four years with no resolution despite multiple antibiotic regimens and adjunctive sinus treatments. An associated periapical osteoperiostitis lesion is evident over the palatal root apex of the necrotic right maxillary first molar (small arrow). **B.** 3-month postoperative coronal CT image showing full resolution of the maxillary rhinosinusitis following endodontic therapy of the maxillary first molar. No other sinus treatment was performed, nor antibiotics administered.

### 3. Clinical Examination

When diagnosing a possible endodontic etiology in patients with rhinosinusitis, the clinician must perform a thorough clinical endodontic examination to evaluate for any pulpal necrosis and periapical disease, while carefully evaluating all prior endodontic treatments for possible failure in the suspected quadrant. Endodontic evaluation of pulpal and periapical tissues includes thermal testing, electric pulp vitality testing, percussion, palpation, periodontal probing and mobility tests. A healthy vital pulp will not contribute to any periradicular or odontogenic sinus inflammation. While an inflamed vital pulp with root apices proximal to the sinus floor may generate enough inflammatory mediators to induce minor sinus mucosal changes, it is unlikely to contribute to any significant sinonasal disease or sinonasal symptoms.<sup>45</sup> For a periapical infection to occur, microorganisms must be present.<sup>46</sup> Only those teeth with an infected necrotic pulp or failing endodontic treatment will generate MSEO. When examining maxillary posterior teeth with existing root canal treatment, one must carefully examine for any untreated or sub-optimally filled canals, inadequate core restorations, or leaking coronal restorations that may provide evidence of endodontic failure and a bacterial source for MSEO.<sup>4</sup>

#### Treatment of MSEO

Successful management of MSEO, as with any infection of endodontic origin, is focused on removing the nidus of infection and preventing reinfection. The objectives for treatment of MSEO are removal of the pathogenic microorganisms, their by-products, and pulpal debris from the infected root canal system that are causing the sinus infection. Appropriate treatment options include non-surgical root canal therapy, periradicular surgery when indicated, intentional replantation, or extraction of the infected tooth. Patients should be informed of all treatment options and the prognosis of each option, to include risks of no treatment.

Clinicians performing endodontic treatment in the posterior maxillary dentition should have extensive knowledge of maxillary root canal anatomy, the necessary armamentarium, and requisite clinical skill considering the anatomic complexities and challenges in this region. Endodontists are specialists in managing complex root canal systems, and maxillary molars typically have the most complex anatomy in the dentition. Inadequate root canal treatment, particularly missed mesio-buccal canal systems, is a common cause of endodontic failure in maxillary molars.<sup>48-51</sup> The close anatomic proximity of maxillary molar root apices to the floor of the maxillary sinus can lead to persistent or progressive MSEO if canals are left untreated or root canal failure occurs in these teeth. Clinicians should realize that persistent sinus infection following endodontic treatment may be due to deficiencies in endodontic or restorative treatment, or due to periodontal disease<sup>52,53</sup>, and should critically evaluate these potential sources of sinusitis prior to concluding that other forms of medical or surgical intervention are indicated.

Use of systemic antibiotics to manage MSEO should follow the guidelines set forth in the *AAE Guidance on the Use of Systemic Antibiotics in Endodontics*.<sup>54</sup> Apart from spreading infections, antibiotic therapy is unwarranted in the treatment of MSEO and utterly ineffective as a definitive solution. While antibiotic therapy may offer temporary relief of symptoms by improving sinus clearing, and may be indicated for rapidly spreading infections, their sole use is inappropriate without definitive debridement and disinfection of the root canal system. In cases of MSEO, antibiotic therapy should not be used in lieu of endodontic treatment or removal of the infected root canal system.

Similarly, surgical intervention of the maxillary sinus that is focused strictly on removing diseased sinus tissue and establishing drainage is inadequate if the endodontic component is neglected. Although these procedures are performed with the goal of re-establishing sinus aeration and drainage, and may provide relief of some symptoms, it is well documented that

neglecting the dental etiology and focusing only on medical and surgical therapies of the ostiomeatal complex (OMC) will not resolve MSEO.<sup>15,55-57</sup> The dental literature provides numerous case reports showing full resolution of MSEO following endodontic treatment.<sup>2,16,19-22,58-62</sup>

It should be noted, however, that thorough dental treatment alone may not resolve all cases of MSEO, therefore clinical and radiological follow-up is essential as concomitant management of the associated rhinosinusitis by an ENT specialist may be necessary in some cases.<sup>15,37,59,60,63-66</sup>

Tomamatsu<sup>60</sup> et al. evaluated 39 patients with MSEO associated with full unilateral maxillary sinus obstruction who underwent initial treatment of endodontic therapy or extraction. Twenty patients showed full resolution of maxillary sinus obstruction and sinusitis symptoms without requiring sinus surgery. The remaining 19 patients required adjunctive sinus surgery which resolved the sinusitis. The primary finding in this study was that the non-effective group displayed a significantly narrower aperture width of the OMC, suggesting it may be a predictor of the effectiveness of initial dental treatment of MSEO. In contrast to earlier studies that recommend contemporaneous dental treatment and sinus surgery for management of all cases of odontogenic sinusitis<sup>67-69</sup>, the Tomamatsu study strongly supports the AAE's position for managing MSEO by treating the primary endodontic infection first, followed by clinical and radiological assessment, and then proceeding with additional sinus surgical procedures only for recalcitrant cases, even in cases of total sinus obstruction. Contemporaneous dental and surgical sinus treatment with appropriate antibiotics should only be considered in severely acute cases requiring immediate drainage.

Collectively, the literature strongly supports the need for a collaborative effort and open referral relationship between the ENT surgeon and the endodontic specialist to achieve the best outcomes for patients with MSEO. Directions for future research may include the incidence and progression of sinus disease in MSEO, specific pathological alterations to sinus mucosal tissues

induced by endodontic disease, and potential indicators for adjunctive antibiotic use, medical treatments, or surgical sinus treatment following endodontic therapy in the management of MSEO.

## Conclusion

It is important to recognize that MSEO is fundamentally an endodontic infection manifesting in the maxillary sinus. This condition is different from sinogenic sinusitis, with an entirely different pathogenesis and treatment regimen. Although the symptoms and radiographic signs of MSEO may mimic sinogenic sinusitis and lead patients to first seek care from their primary care physicians or ENT specialists, medical treatment will not resolve MSEO if the endodontic source is overlooked. MSEO is also frequently overlooked in general dental practice due to a lack of dental symptoms and an obscured or atypical radiographic presentation. The increased availability of in-office CBCT has increased clinicians' recognition and ability to diagnose MSEO. Clinical endodontic examination, however, remains essential for correct diagnosis. Endodontists are uniquely trained and equipped to diagnose and properly manage endodontic disease that manifests in the maxillary sinus. Improved communication and referral relationships between ENT surgeons and endodontic specialists are essential to provide appropriate patient care when managing MSEO.

## References

1. Bauer WH. Maxillary sinusitis of dental origin. *Am J Orthod Oral Surg* 1943;29:133-51.
2. Abrahams JJ, Glassberg RM. Dental disease: a frequently unrecognized cause of maxillary sinus abnormalities? *Am J Roentgenol* 1996;166:1219-23.
3. Mattila K. Roentgenological investigations of the relationship between periapical lesions and conditions of the mucous membrane of the maxillary sinuses. *Acta Odontolog Scand* 1965;23:42-6.
4. Obayashi, N., Ariji, Y., Goto, M. et al. Spread of odontogenic infection originating in the maxillary teeth: computerized tomographic assessment. *Oral Surg Oral Med Oral Pathol Oral Radiol Endod* 2004;98:223-31.
5. Maloney PL, Doku HC. Maxillary sinusitis of odontogenic origin. *J Can Dent Assoc* 1968;34:591-603.
6. Kretzschmar DP, Kretzschmar JL. Rhinosinusitis: Review from a dental perspective. *Oral Surg Oral Med Oral Pathol Oral Radiol Endod* 2003;96:128-35.
7. Mehra P, Murad H. Maxillary sinus disease of odontogenic origin. *Otolaryngol Clin North Am* 2004;37:347-64.
8. Cymerman JJ, Cymerman DH, O'Dwyer RS. Evaluation of odontogenic maxillary sinusitis using cone-beam computed tomography: three case reports. *J Endod* 2011;37:1465-9.
9. Lanza DC, Kennedy DW. Adult rhinosinusitis defined. *Otolaryngol Head Neck Surg* 1997;117:1-7.
10. Fleming, WE. The effect of chronic pyogenic infections on the maxillary sinus. *Qld Dent J* 1954;6:78-82.
11. Melen I, Lindahl L, Andreasson L, Rundcrantz H. Chronic maxillary sinusitis. Definition, diagnosis and relation to dental infections and nasal polyposis. *Acta Otolaryngol* 1986;101:320-7.
12. Maillet M, Bowles WR, McClanahan, SL. Cone-Beam computed tomography evaluation of maxillary sinusitis. *J Endod* 2011;37:753-57.
13. Bomelli SR, Branstetter BF, Ferguson, BF. Frequency of a dental source for acute maxillary sinusitis. *Laryngoscope* 2009; 119(3):580-84.
14. Matsumoto Y, Ikeda T, Yokoi H, et al. Association between odontogenic infections and unilateral sinus opacification. *Auris Nasus Larynx* 2015;42:288-93.
15. Patel NA, Ferguson BJ. Odontogenic sinusitis: an ancient but under-appreciated cause of maxillary sinusitis. *Curr Opin Otolaryngol Head Neck Surg* 2012;20:24-8.
16. Longhini AB, Ferguson BJ. Clinical aspects of odontogenic maxillary sinusitis: a case series. *Int Forum Allergy Rhinol* 2011;1:409-15.
17. Pokorny A, Tataryn R. Clinical and radiologic findings in a case series of maxillary sinusitis of dental origin. *Int Forum Allergy Rhinol* 2013;3:973-9.
18. Seldon HS, August DS. Maxillary sinus involvement – an endodontic complication. *Oral Surg Oral Med Oral Pathol Oral Radiol Endod* 1970;30:117-22.
19. Seldon HS. The interrelationship between the maxillary sinus and endodontics. *Oral Surg Oral Med Oral Pathol Oral Radiol Endod* 1974;38:623-9.
20. Seldon HS. The endo-antral syndrome. *J Endod* 1977;3:462-4.
21. Nenzen B, Welander U. The effect of conservative root canal therapy on local mucosal hyperplasia in the maxillary sinus. *Odontol Revy* 1967;18:295-302.
22. Dodd RB, Dodds RN, Hocomb JB. An endodontically induced maxillary sinusitis. *J Endod* 1984;10:504-6.

23. Bertrand B, Rombaux P, Eloy P, Reyckler H. Sinusitis of dental origin. *Acta Otorhinolaryngol Belg* 1997;51:315-22.
24. Rosenfeld RM, Piccirillo JF, Chandrasekhar SS, et al. Clinical practice guideline (update): Adult sinusitis executive summary. *Otolaryngol Head Neck Surg* 2015;152:598–609.
25. Legert KG, Zimmerman M, Stierna P. Sinusitis of odontogenic origin: pathophysiological implications of early treatment. *Acta Otolaryngol* 2004;124:655-63.
26. Lindahl L, Melen I, Ekedahl C, Holm SE. Chronic maxillary sinusitis. Differential diagnosis and genesis. *Acta Otolaryngol* 1982;93:147-50.
27. Kondrashev PA, Lodochkina OE, Opryshko ON. Microbiological spectrum of causative agents of rhinogenic and odontogenic chronic sinusitis and mucociliary activity of mucosal epithelium in the nasal cavity. *Vestn Otorinolaringol* 2010;4:45-7.
28. Eufinger H, Machtens E. Purulent pansinusitis, orbital cellulitis and rhinogenic intracranial complications. *J Cranio Maxillofac Surg* 2001;29:111-7.
29. Wagenmann M, Naclerio RM. Complications of sinusitis. *J Allergy Clin Immunol* 1992;90:552-4.
30. Gold RS, Sager E. Pansinusitis, orbital cellulitis, and blindness as sequelae of delayed treatment of dental abscess. *J Oral Surg* 1974;32:40-3.
31. Park CH, Jee DH, La TY. A case of odontogenic orbital cellulitis causing blindness and severe tension orbit. *J Korean Med Sci* 2013;28:340-3.
32. De Lima CO, Devito KL, Vasconcelos LR, et al. Correlation between endodontic infection and periodontal disease and their association with chronic sinusitis: A clinical-tomographic study. *J Endod* 2017;43:1978-83.
33. Zirk M, Dreiseidler T, Pohl M, et al. Odontogenic sinusitis maxillaris: A retrospective study of 121 cases with surgical intervention. *J Craniomaxillofac Surg* 2017;45:520-5.
34. Lechian JR, Filleul O, Costa de Araujo P, et al. Chronic maxillary rhinosinusitis of dental origin: A systematic review of 674 patient cases. *Int J Otolaryngol* 2014;2014:465173. Epub
35. Taschieri S, Torretta S, Corbella S, et al. Pathophysiology of sinusitis of odontogenic origin. *J Investig Clin Dent* 2017;8(2).
36. Williams JW, Simel DL, Roberts L, Samsa GP. Clinical evaluation for sinusitis: making the diagnosis by history and physical evaluation. *Ann Intern Med* 1992;117:705-10.
37. Workman AD, Granquist EJ, Adappa ND. Odontogenic sinusitis: developments in diagnosis, microbiology, and treatment. *Curr Opin Otolaryngol Head Neck Surg* 2018;26:27-33.
38. Ball RL, Barbizam JV, Cohenca N. Intraoperative endodontic applications of cone-beam computed tomography. *J Endod* 2013;39:548–57.
39. Lofthag-Hansen S, Huuonen S, Grondahl K, et al. Limited cone-beam CT and intraoral radiography for the diagnosis of periapical pathology. *Oral Surg Oral Med Oral Pathol Oral Radiol Endod* 2007;103:114-9.
40. Low, K.M., Dula, K., Burgin, W., and von Arx, T. Comparison of periapical radiography and limited cone-beam tomography in posterior maxillary teeth referred for apical surgery. *J Endod* 2008;34:557–62.
41. Shahbazian M, Vandewoude C, Wyatt J, Jacobs R. Comparative assessment of periapical radiography and CBCT imaging for radiodiagnostics in posterior maxilla. *Odontology* 2015;103:97–104.

42. Nunes CA, Guedes OA, Alencar AH, et al. Evaluation of periapical lesions and their association with maxillary sinus abnormalities on cone-beam computed tomographic images. *J Endod* 2016;42:42-6.
43. Worth HM, Stoneman DW. Radiographic interpretation of antral mucosal changes due to localized dental infection. *J Can Dent Assoc* 1972;38:111-6.
44. Tatarzyn RW. Surgical endodontics and the maxillary sinus. In: Torabinejad M, Rubinstein R (eds). *The art and science of contemporary surgical endodontics*. Chicago, IL: Quintessence. 203-22.
45. Tatarzyn RW. Rhinosinusitis and endodontic disease. In: Ingle JI, Bakland LK, Baumgartner JC (eds). *Ingle's Endodontics*, ed 6. Hamilton, ON: BC Decker. 626-37.
46. Kakehashi S, Stanley HR, Fitzgerald RJ. The effects of surgical exposures of dental pulps in germ-free and conventional laboratory rats. *Oral Surg Oral Med Oral Pathol Oral Radiol Endod* 1965;20:340-9.
47. Gomes AC, Nejaim Y, Silva AIV, et al. Influence of endodontic treatment and coronal restoration on status of periapical tissues: A cone-beam computed tomographic study. *J Endod* 2015;41:1614-8.
48. Wolcott J, Ishley D, Kennedy W, et al. A 5 yr clinical investigation of second mesiobuccal canals in endodontically treated and retreated maxillary molars. *J Endod* 2005;31:262-4.
49. Cleghorn BM, Christie WH, Dong CC. Root and root canal morphology of the human permanent maxillary first molar: a literature review. *J Endod* 2006;32:813-21.
50. Verma P, Love RM. A micro CT study of the mesiobuccal root canal morphology of the maxillary first molar tooth. *Int Endod J* 2011;44:210-7.
51. Degerness RA, Bowles WR. Dimension, anatomy and morphology of the mesiobuccal root canal system in maxillary molars. *J Endod* 2010;36:985-9.
52. Falk H, Ericson S, Hugoson A. The effects of periodontal treatment on mucous membrane thickening in the maxillary sinus. *J Clin Periodontol* 1986;13:217-22.
53. Engström H, Chamberlain D, Kiger R, Egelberg J. Radiographic evaluation of the effect of initial periodontal therapy on thickness of the maxillary sinus mucosa. *J Periodontol* 1988;59:604-8.
54. Fouad AF, Byrne BE, Diogenes AR, et al. AAE Guidance on the Use of Systemic Antibiotics in Endodontics. Association of Endodontists Position Statement 2017:1-8.
55. Cartwright S, Hopkins C. Odontogenic sinusitis an underappreciated diagnosis: Our experience. *Clin Otolaryngol* 2016;41:284-5.
56. Kulacz R., Fishman G, Levine H. An unsuccessful sinus surgery caused by dental involvement within the floor of the maxillary sinus. *Op Techniques Otolaryngol Head Neck Surg* 2004;15:2-3.
57. Longhini AB, Branstetter BF, Ferguson BJ. Unrecognized odontogenic maxillary sinusitis: A cause of endoscopic sinus surgery failure. *Am J Rhinol Allergy* 2010;24:296-300.
58. Bogaerts P, Hanssens JF, Siquet JP. Healing of maxillary sinusitis of odontogenic origin following conservative endodontic retreatment: case reports. *Acta Otorhinolaryngol Belg* 2003;57:91-7.
59. Wang KL, Nichols BG, Poetker DM, Loehrl TA. Odontogenic sinusitis: a case series studying diagnosis and management. *Int Forum Allergy Rhinol* 2015;5:597-601.
60. Tomomatsu N, Uzawa N, Aragaki T, Harada K. Aperture width of the osteomeatal complex as a predictor of successful treatment of odontogenic maxillary sinusitis. *Int J Oral Maxillofac Surg* 2014;43:1386-90.
61. Bendyk-Szeffer M, Lagocka R, Trusewicz M, et al. Perforating internal root resorption repaired with mineral trioxide aggregate caused complete resolution of odontogenic sinus mucositis: A case report. *J Endod* 2015;41:274-8.

62. Nurbakhsh B, Friedman S, Kulkarni GV, et al. Resolution of maxillary sinus mucositis after endodontic treatment of maxillary teeth with apical periodontitis: A cone-beam computed tomographic pilot study. *J Endod* 2011;37:1504-11.
63. Brook I. Microbiology of acute and chronic maxillary sinusitis associated with an odontogenic origin. *Laryngoscope* 2005;115:823-5.
64. Simuntis R, Kubilius R, Vaitkus S. Odontogenic maxillary sinusitis: a review. *Stomatologija* 2014;16:39-43.
65. Saibene AM, Pipolo GC, Lozza P, et al. Redefining boundaries in odontogenic sinusitis: a retrospective evaluation of extramaxillary involvement in 315 patients. *Int Forum Allergy Rhinol* 2014;4:1020-3.
66. Mattos JL, Ferguson BJ, Lee S. Predictive factors in patients undergoing endoscopic sinus surgery for odontogenic sinusitis. *Int Forum Allergy Rhinol* 2016;6:677-700.
67. Bertrand B, Rombaux P, Eloy P, Reyckler H. Sinusitis of dental origin. *Acta Otorhinolaryngol Belg* 1997;51:315-22.
68. Costa F, Emanuelli E, Robiony M, et al. Endoscopic surgical treatment of chronic maxillary sinusitis of dental origin. *J Oral Maxillofac Surg* 2007;65:223-8.
69. Albu S, Baciut M. Failures in endoscopic surgery of the maxillary sinus. *Otolaryngol Head Neck Surg* 2010;142:196-201.

**Thank you to the Special Committee to develop a Position Statement on Maxillary Sinusitis of Endodontic Origin:**

**Roderick W. Tataryn, Chair**

**Michael J. Lewis**

**Anthony L. Horalek**

**Chase G. Thompson**

**Bruce Y. Cha, Board Liaison**

**Alan T. Pokorny, Physician (ENT) Consultant**

The guidance in this statement is not intended to substitute for a clinician's independent judgment in light of the conditions and needs of a specific patient.

Access additional resources at [aae.org](http://aae.org).

© 2026 American Association of Endodontists (AAE).